

RADIOGRAFIAS DE TÓRAX

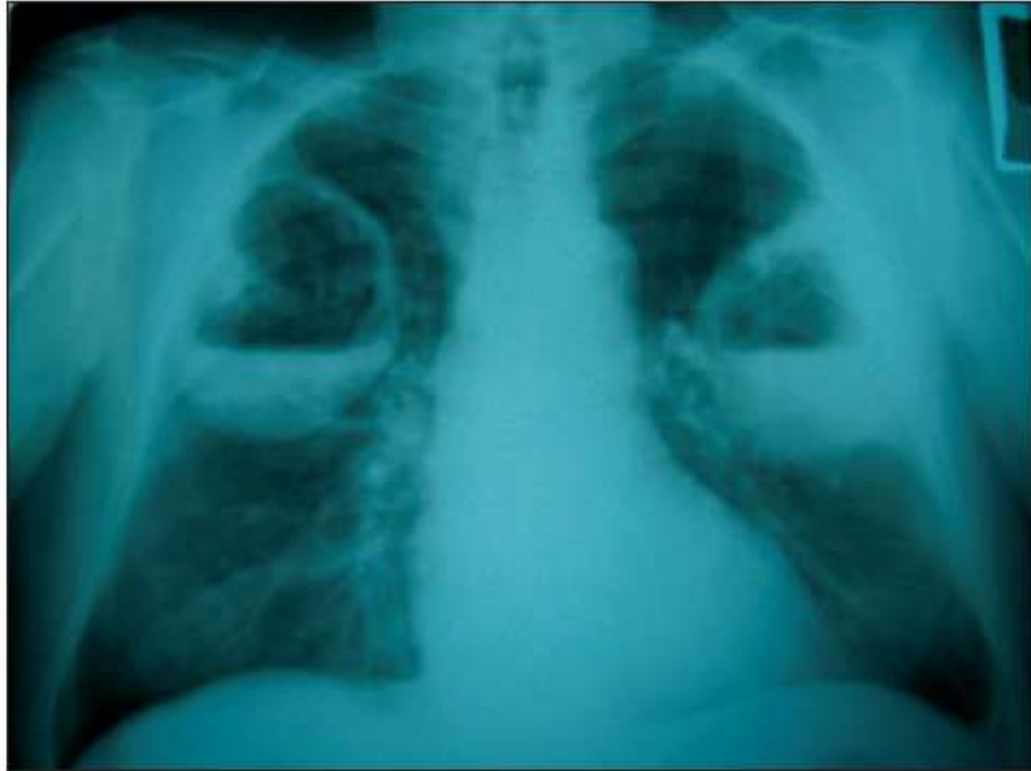


Fig. 1. *Rx tórax al ingreso.*

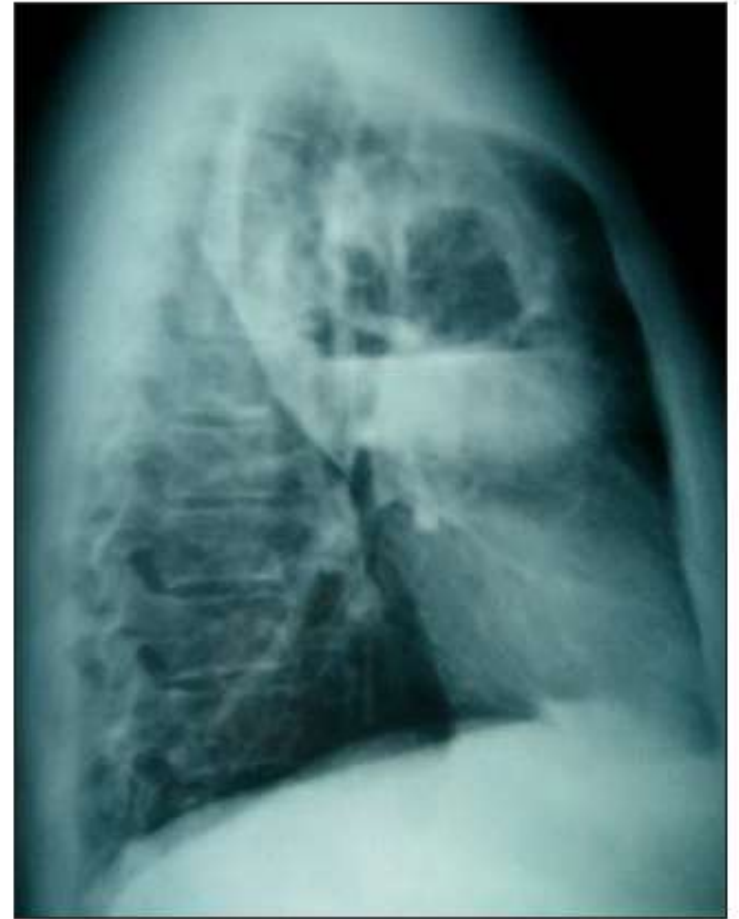


Fig. 2. *Rx tórax al ingreso.*

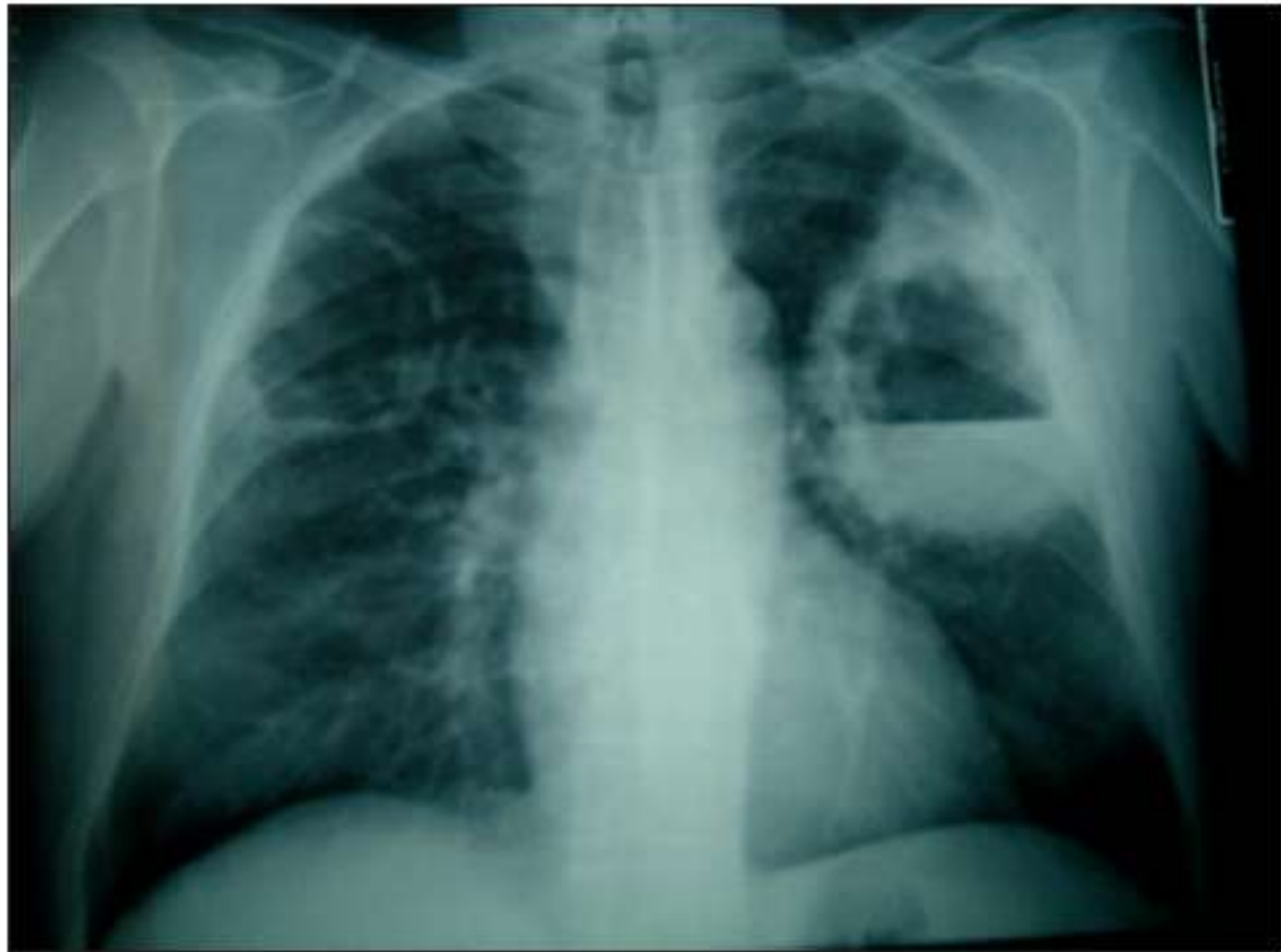

Fig. 5. *Rx tórax de control.*

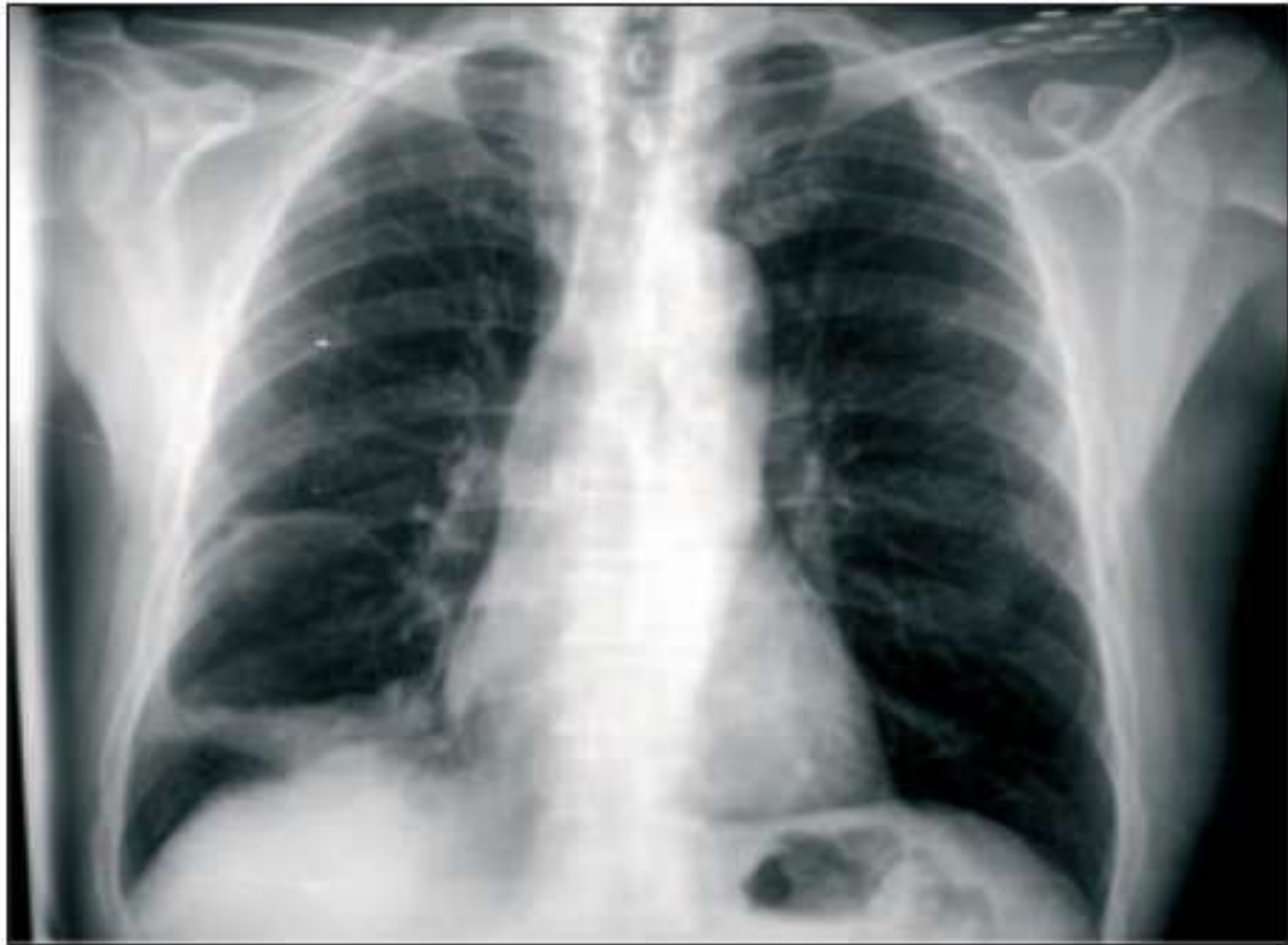

Fig. 1. *Rx de tórax.*

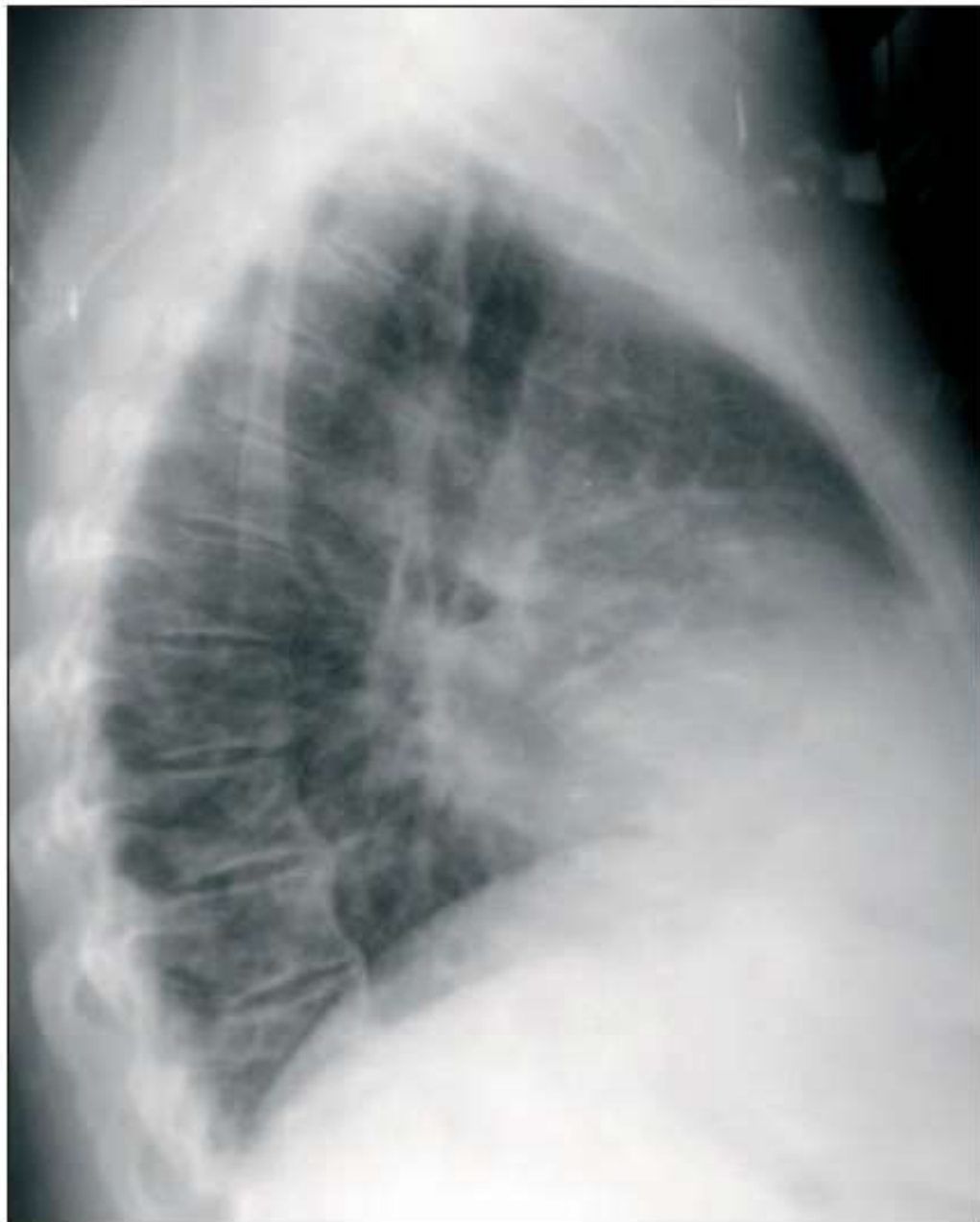

Fig. 2. *Rx de tórax.*

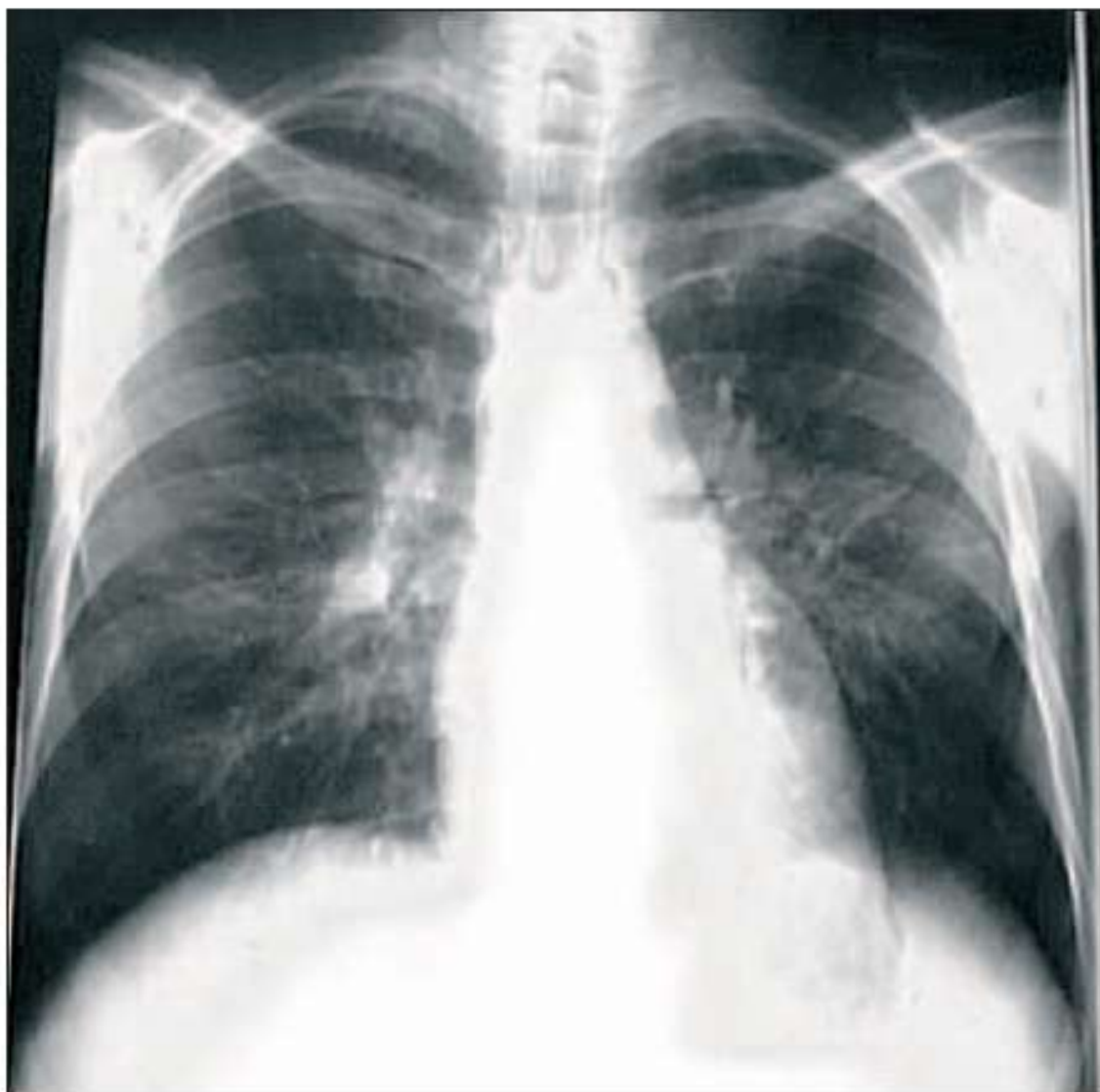

Fig. 1. *Rx de tórax con infiltrado intersticial perihiliar bilateral.*

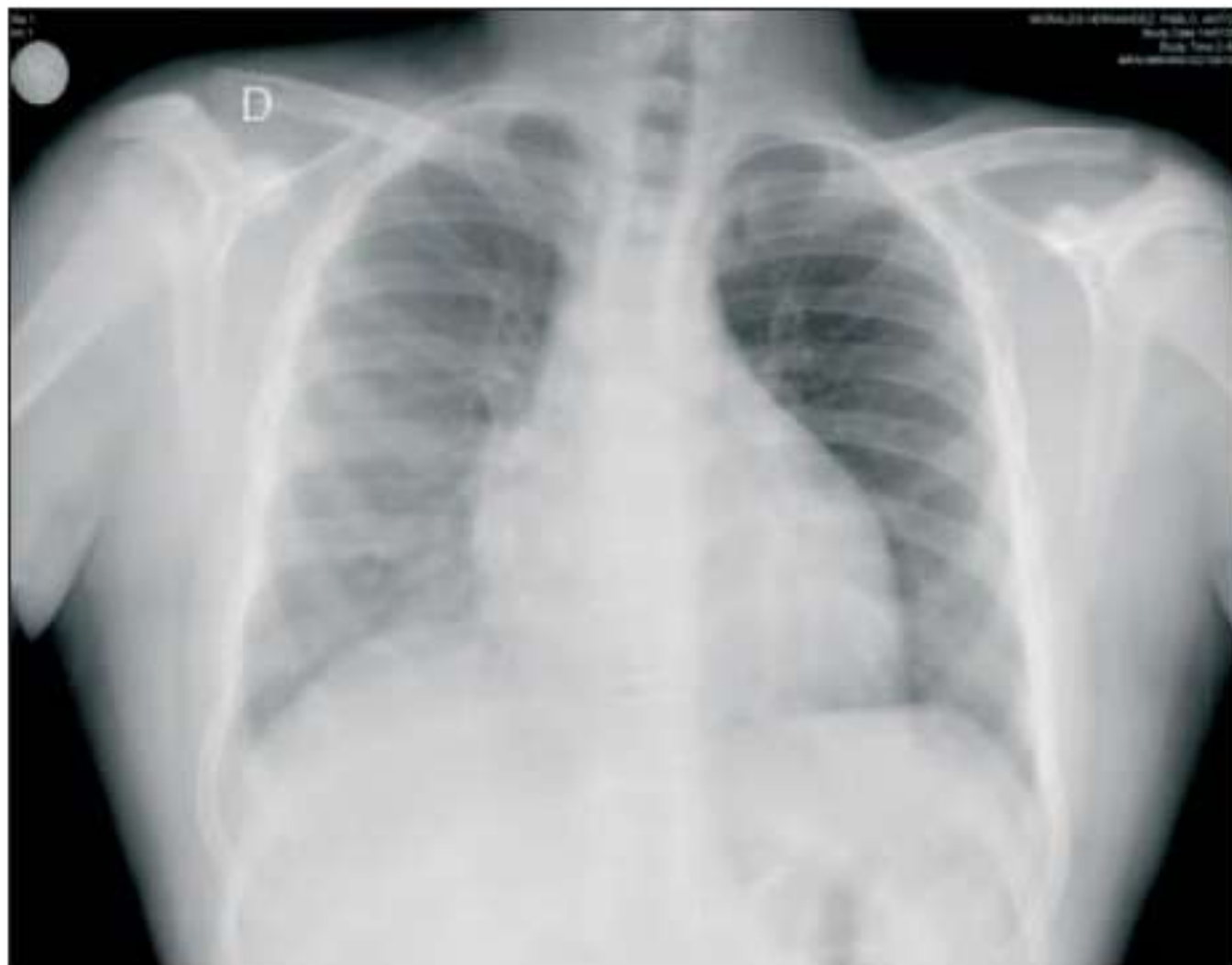

Fig. 2. *Rx tórax. Cardiomegalia sin signos de insuficiencia cardiaca.*

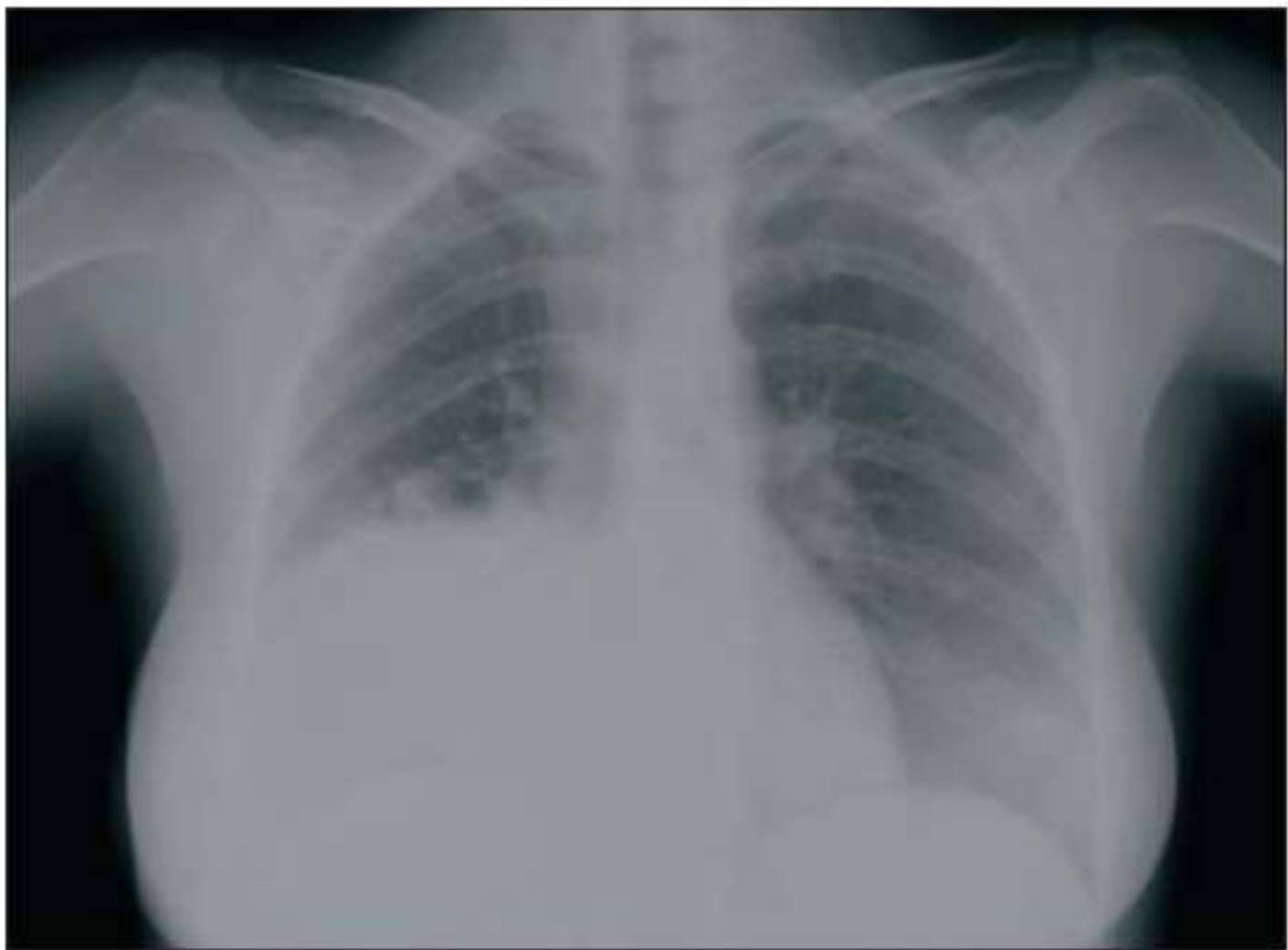


Fig. 2. *Rx de tórax.*

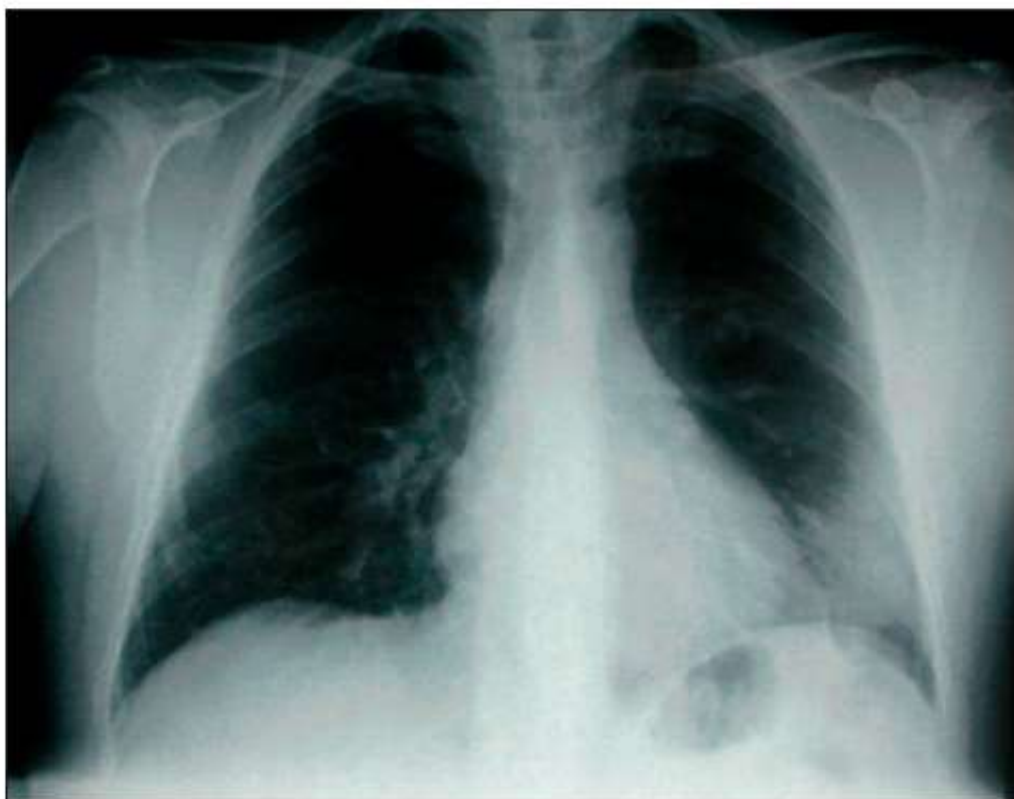


Fig. 1. *Rx de tórax PA.*

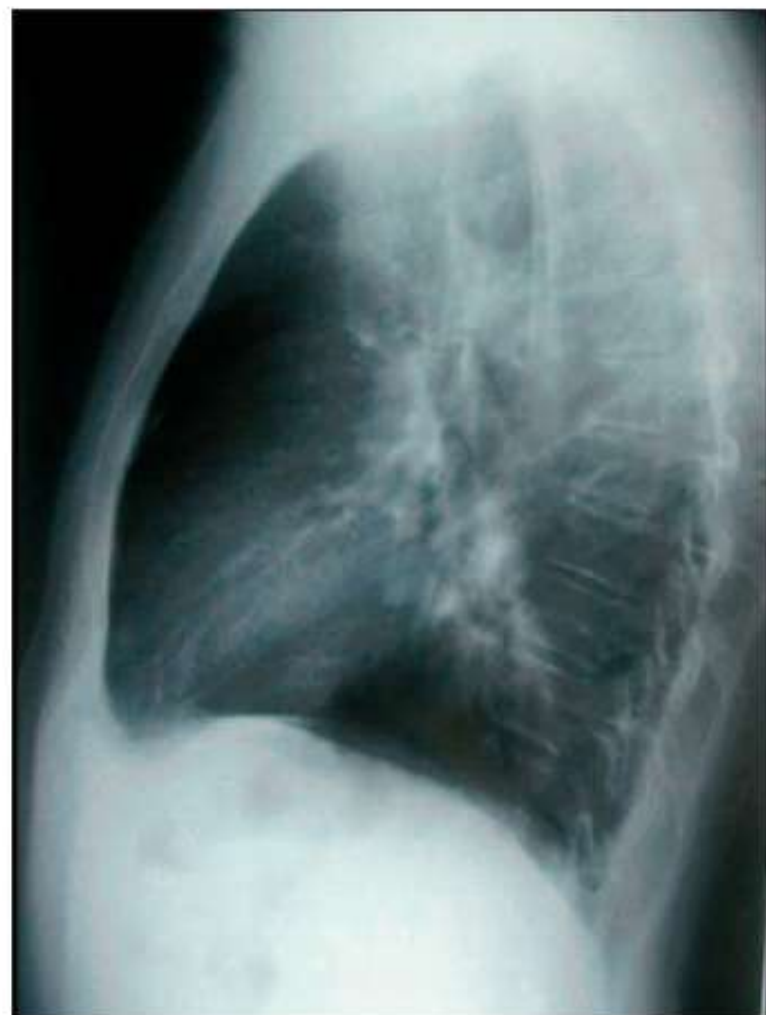

Fig. 2. *Rx de tórax lateral.*

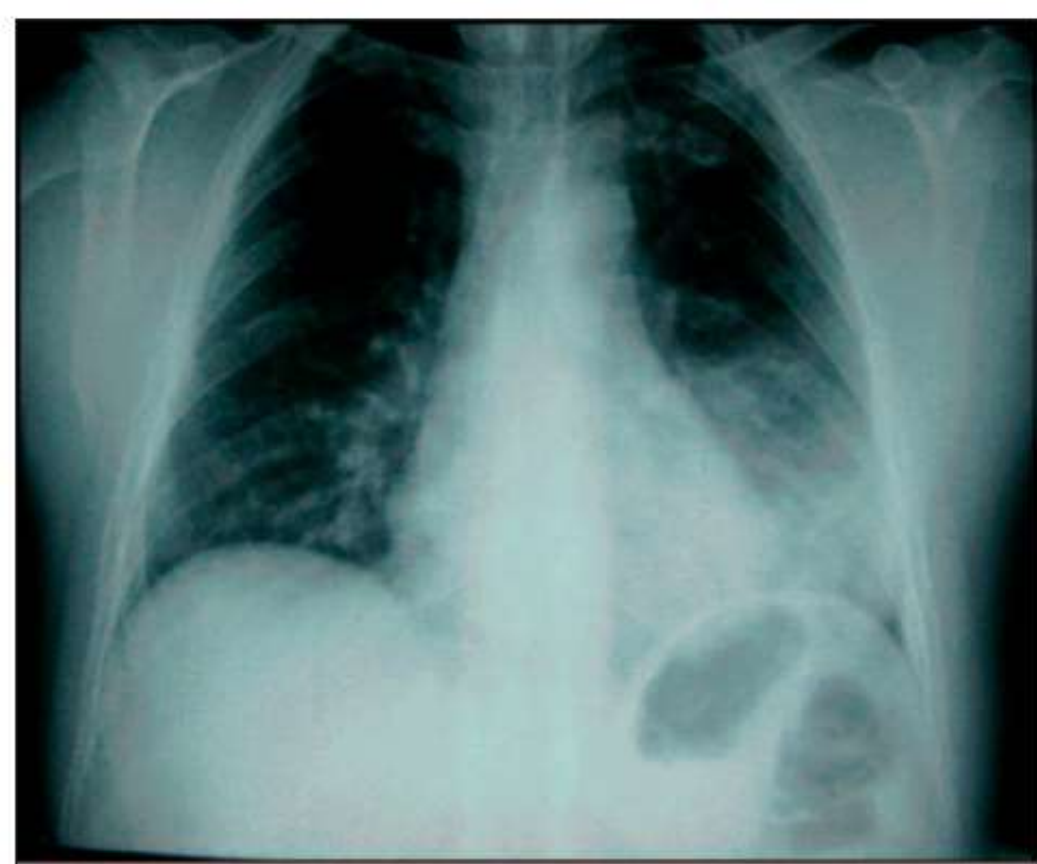


Fig. 3. *Rx de tórax PA.*

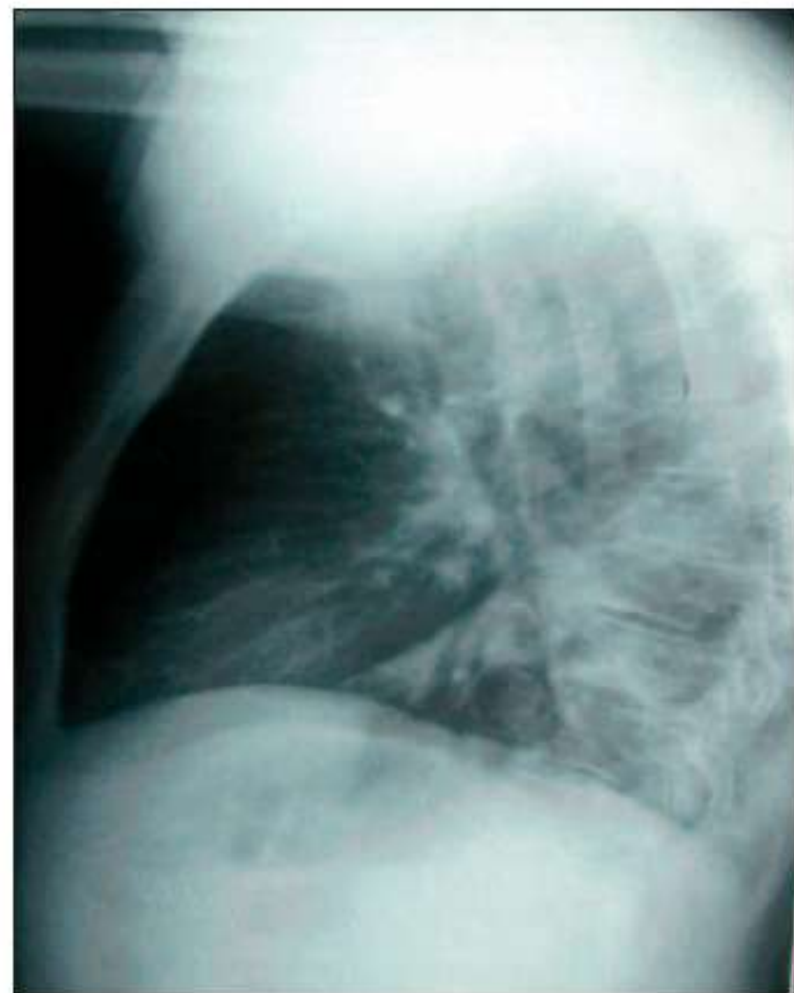

Fig. 4. *Rx de tórax lateral.*

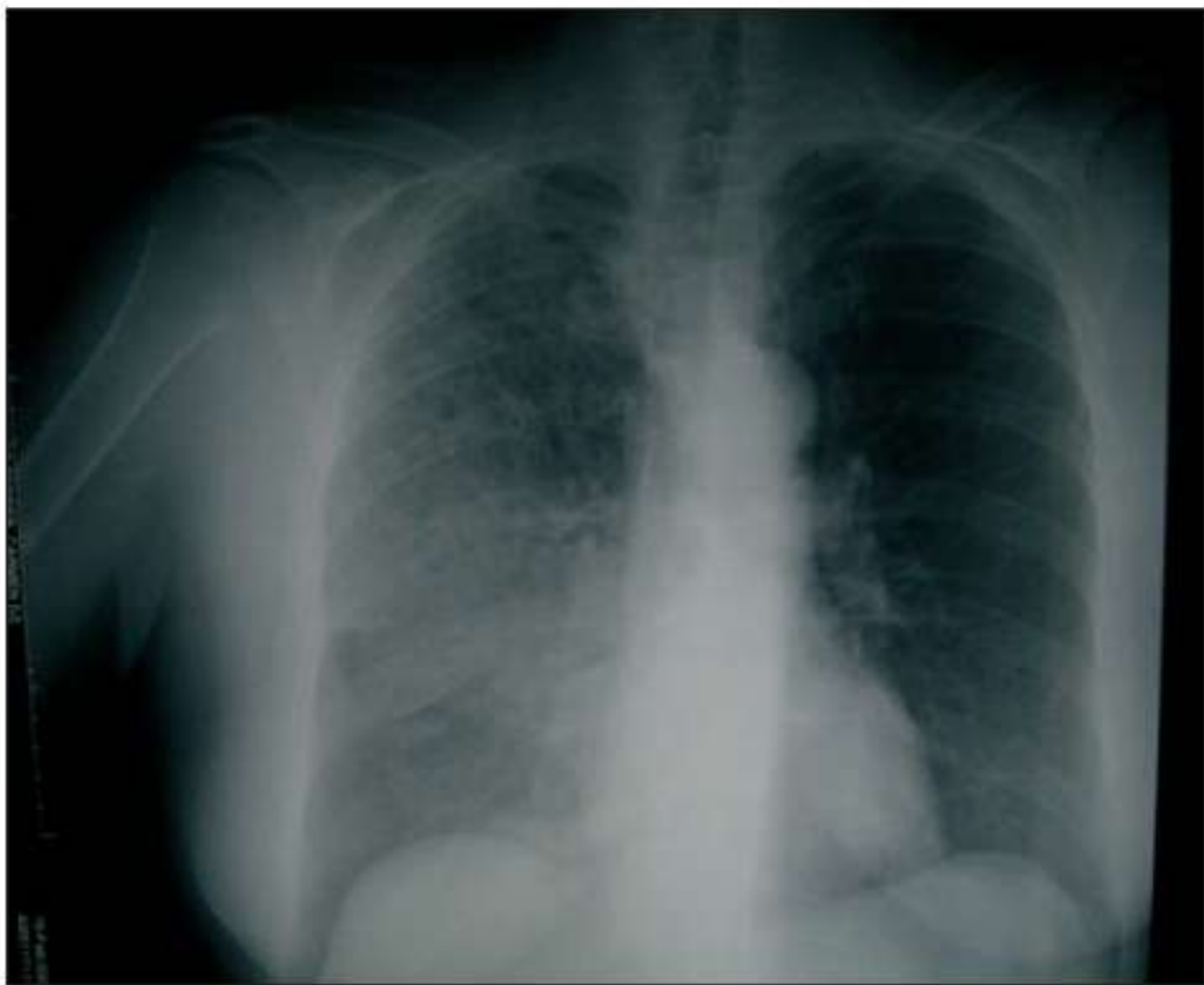


Fig. 1. *Rx tórax.*

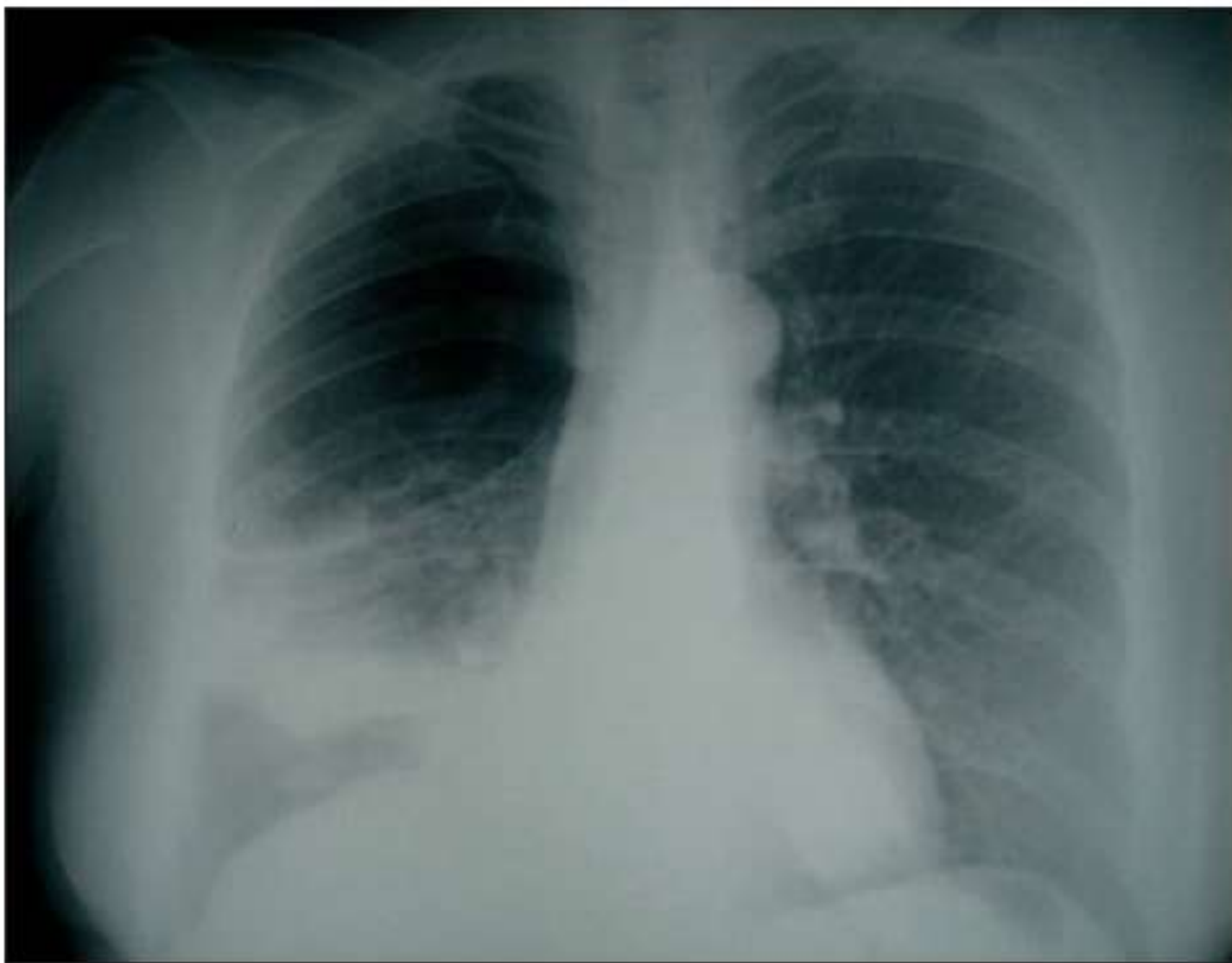

Fig. 2. *Rx tórax de control.*

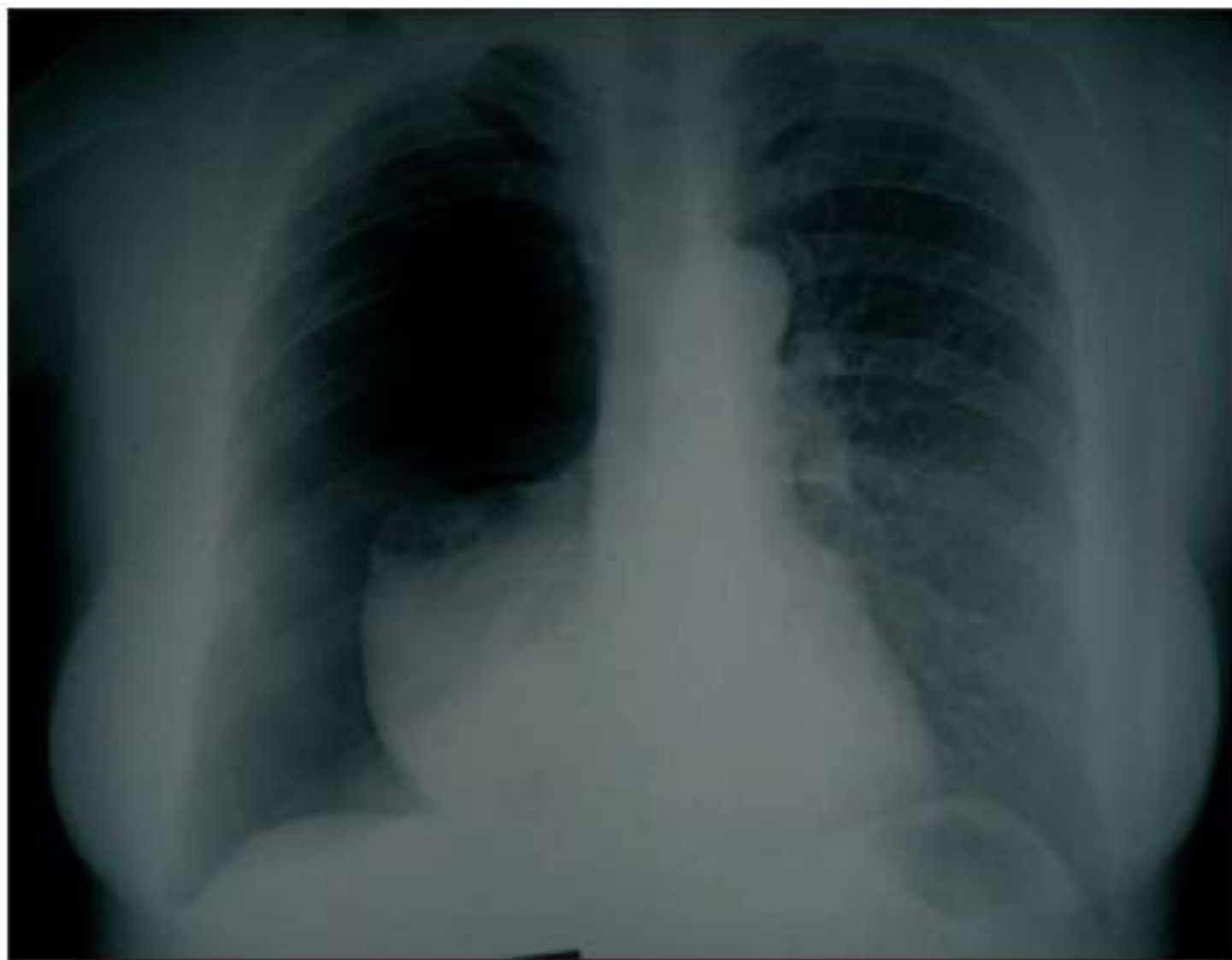

Fig. 3. *Rx tórax.*

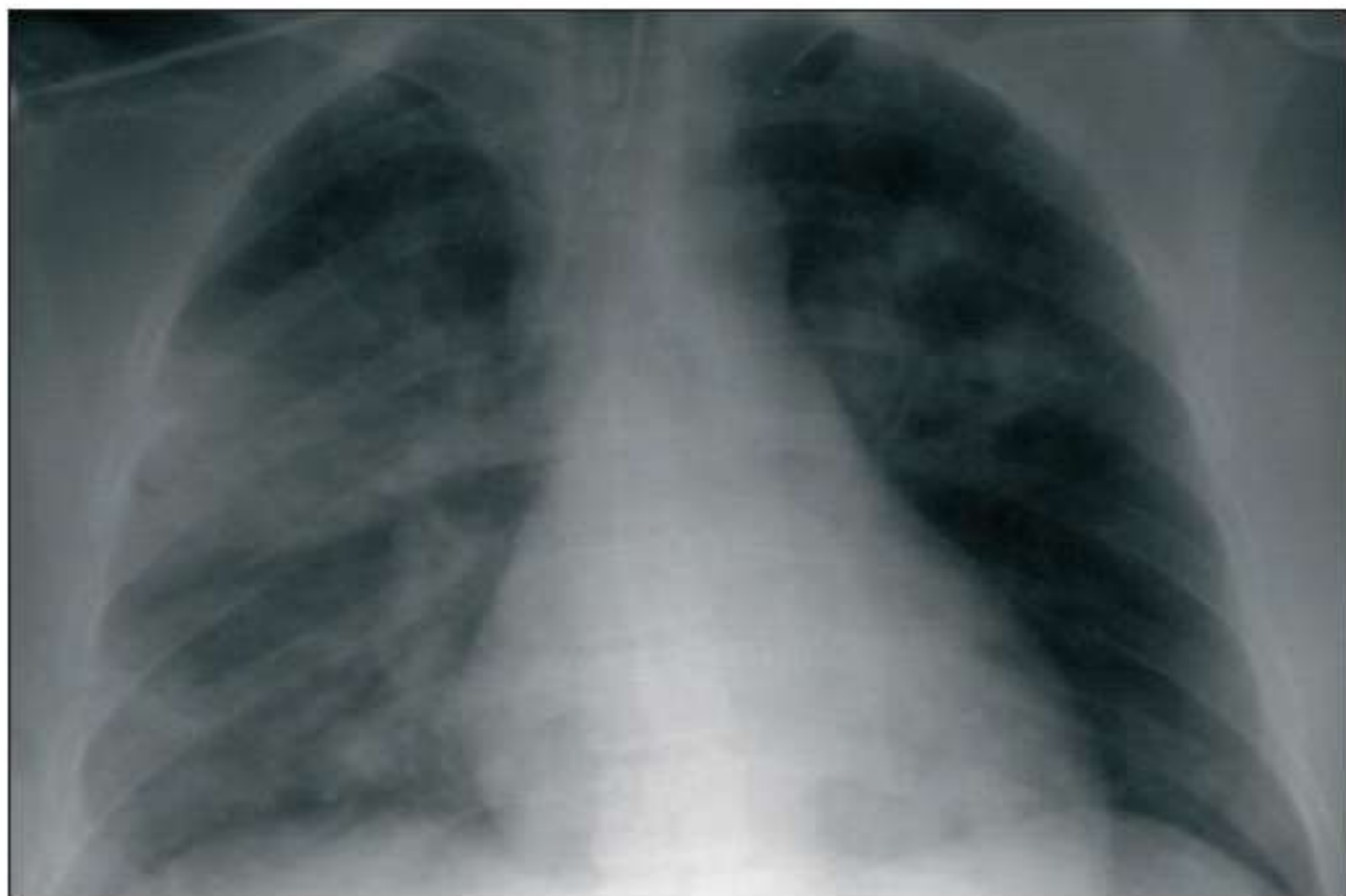
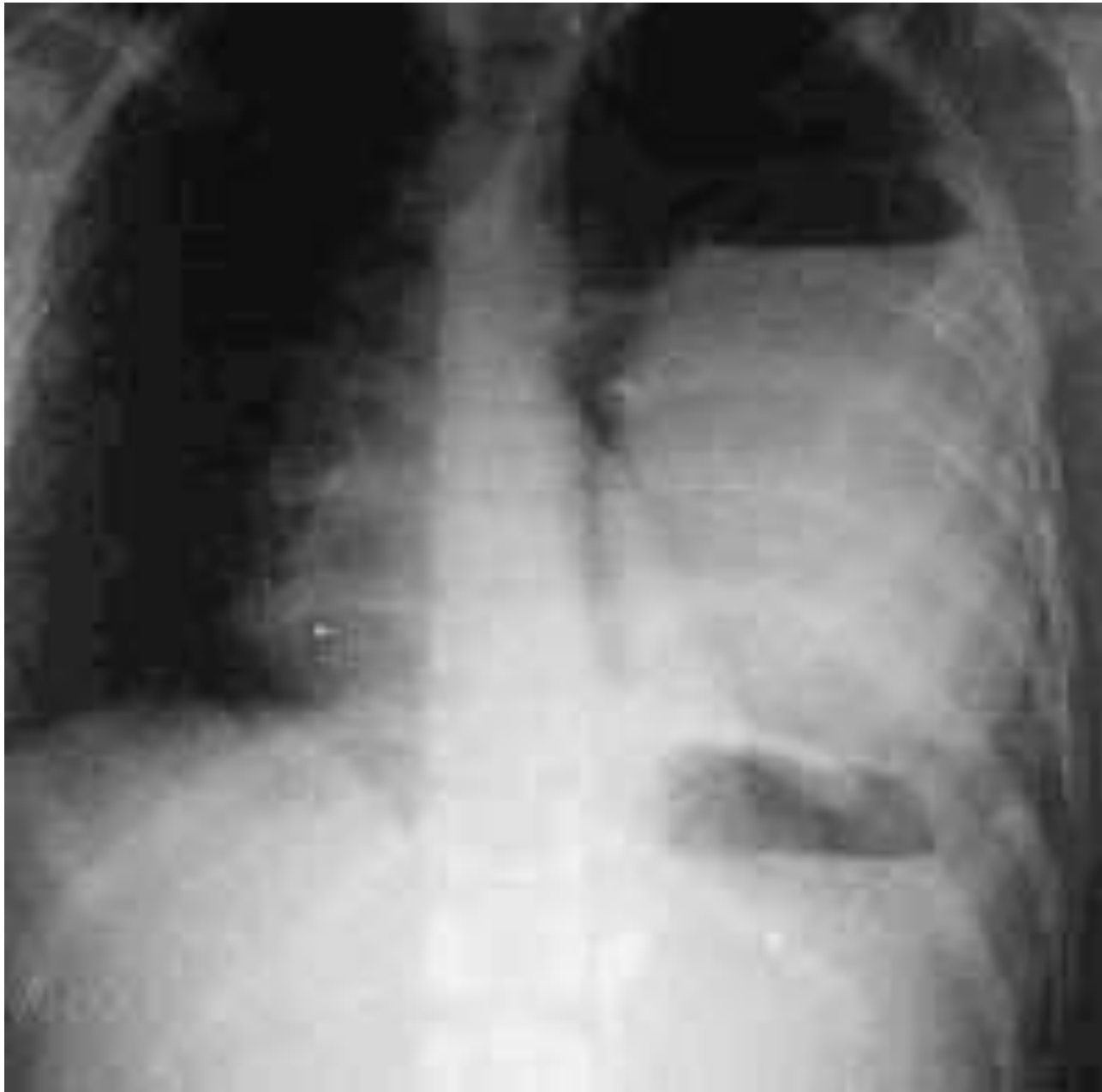
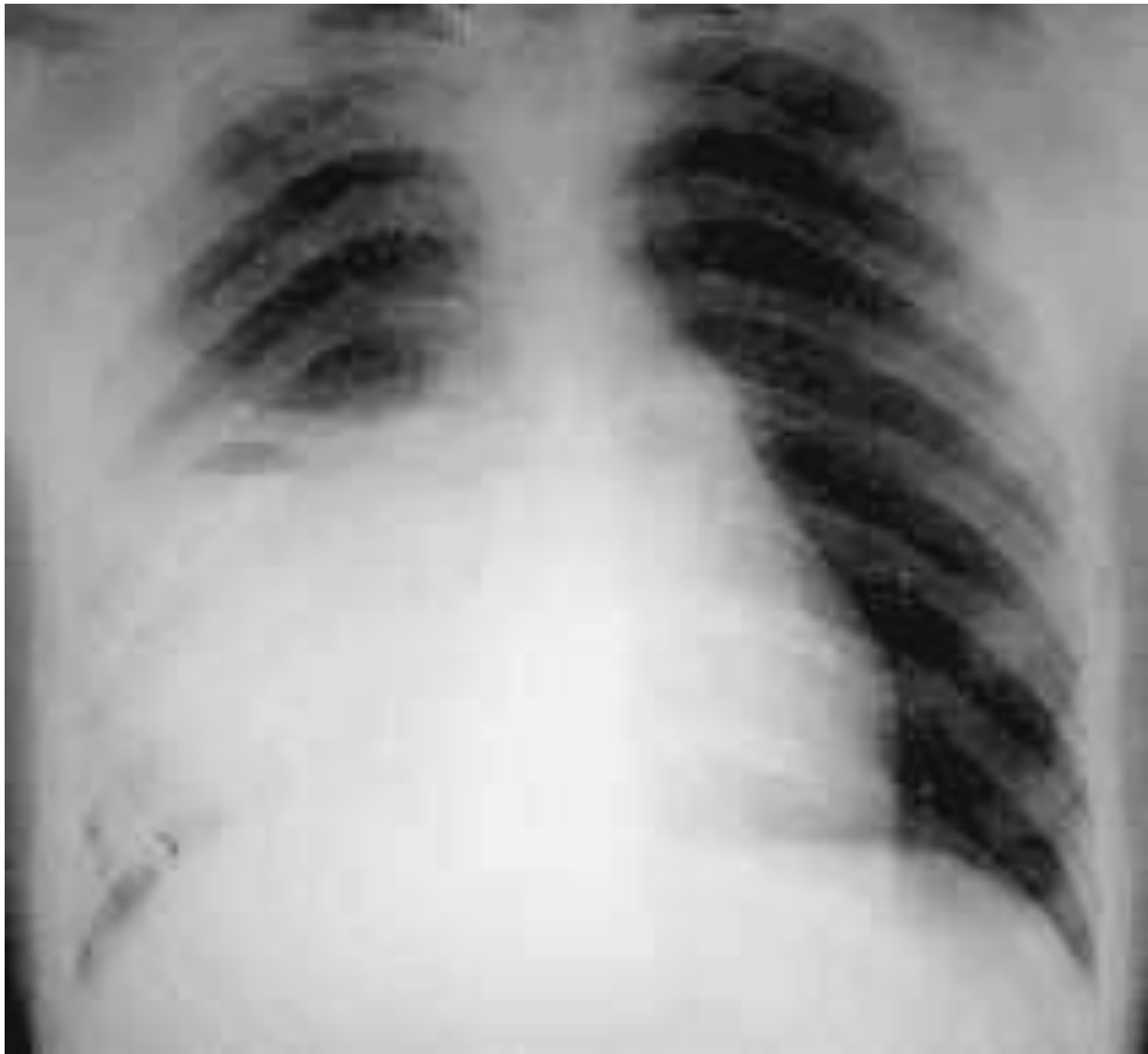
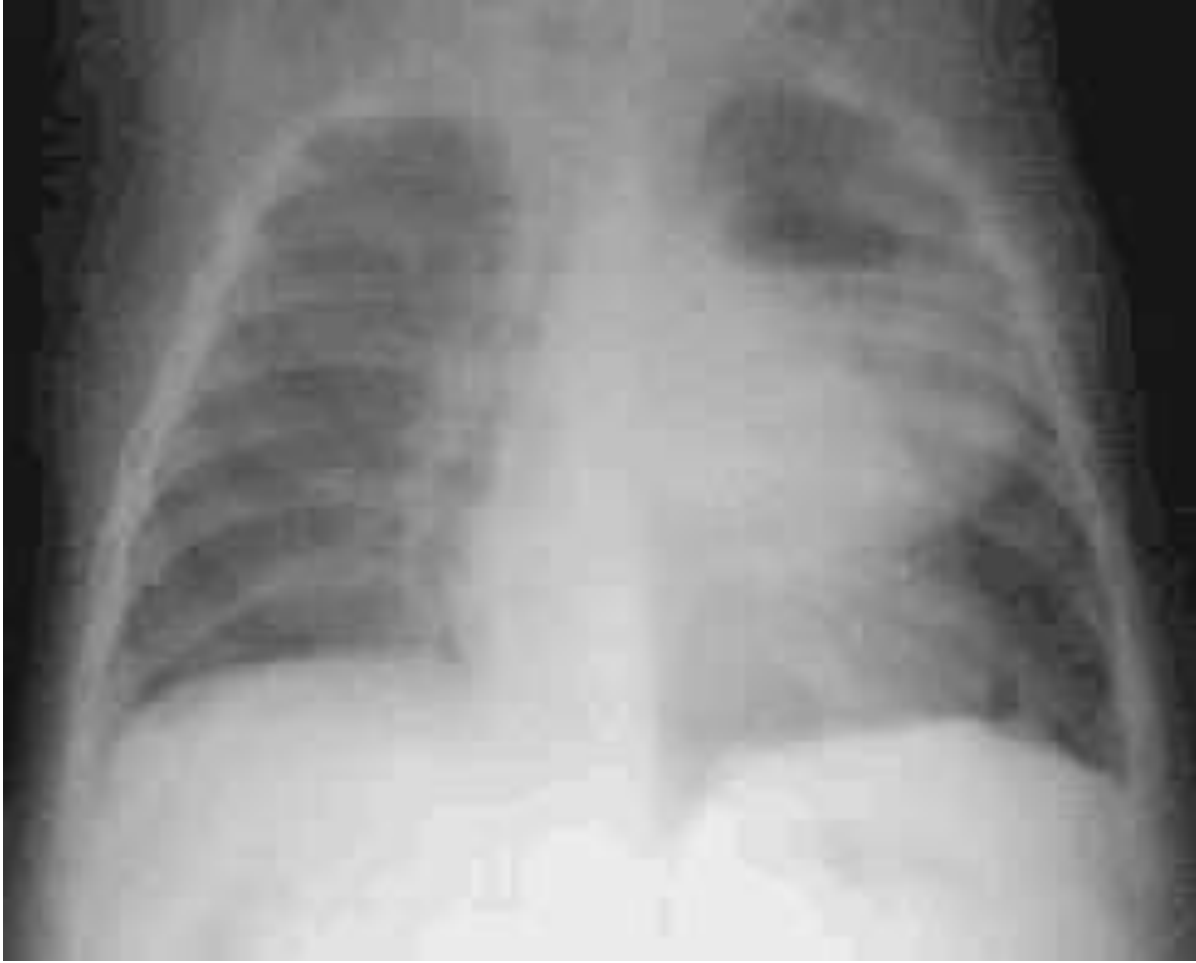Fig. 1. *Rx tórax.*



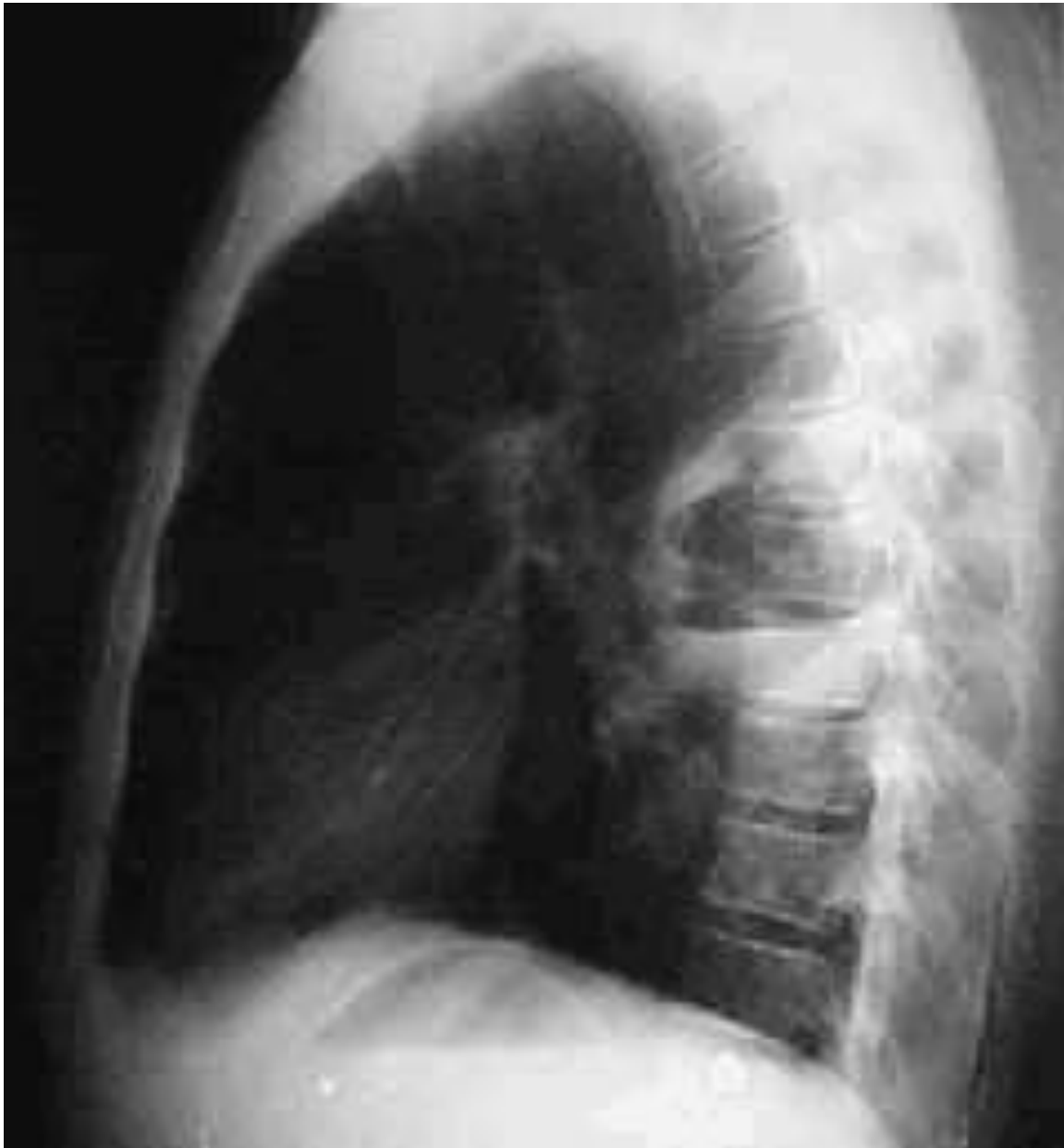Abceso pulmonar



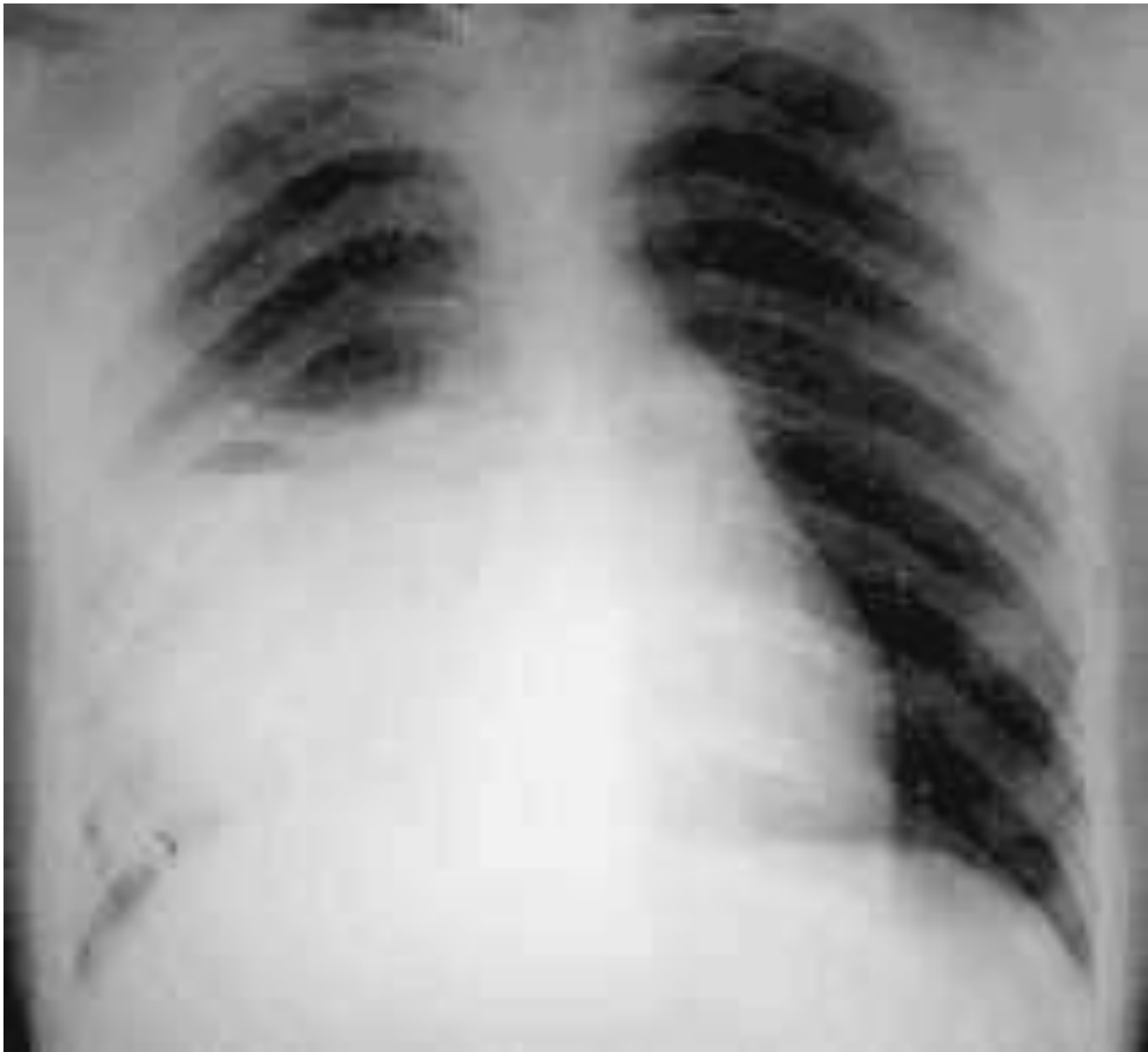Abceso pulmonar



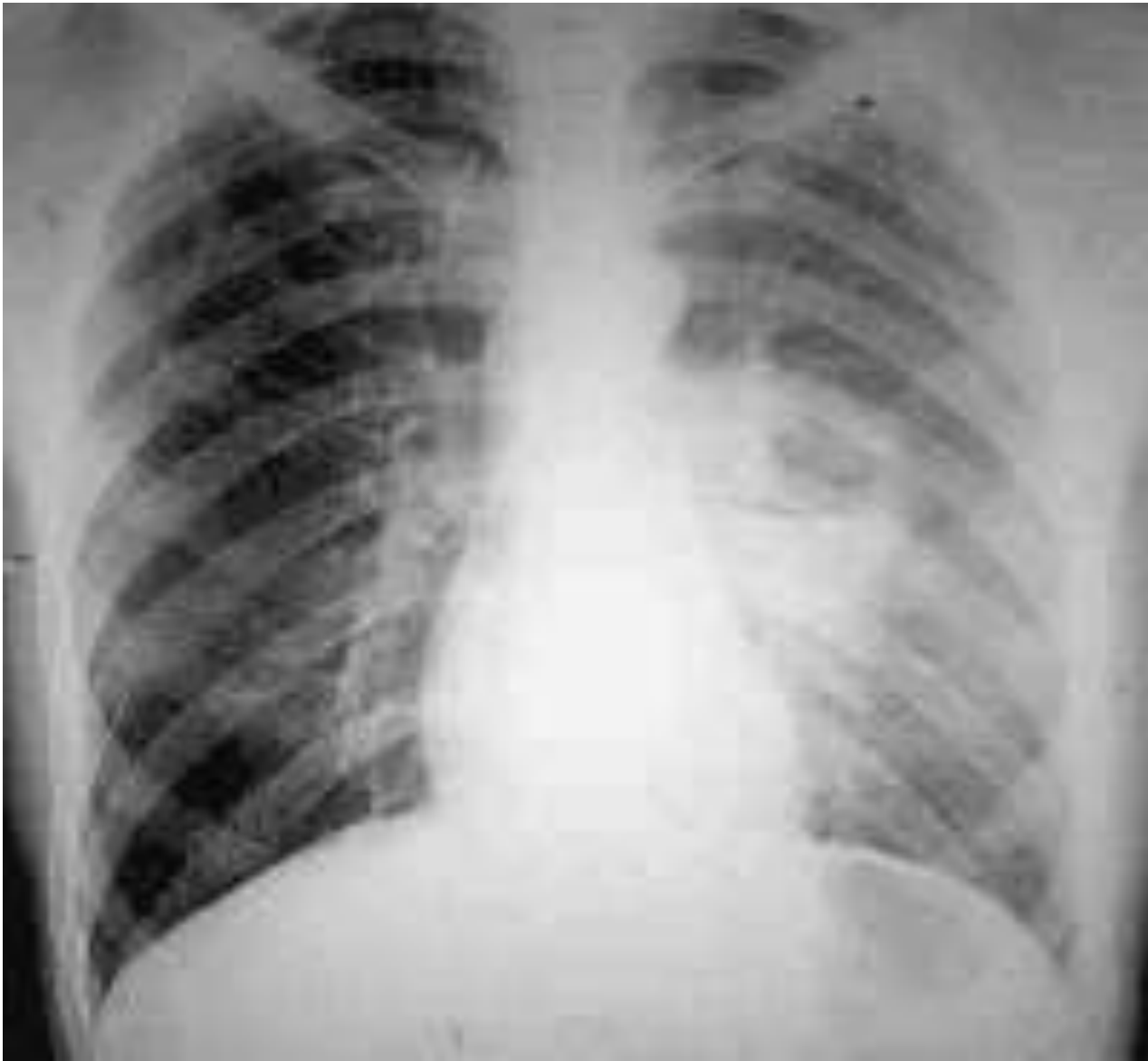
Abceso pulmonar



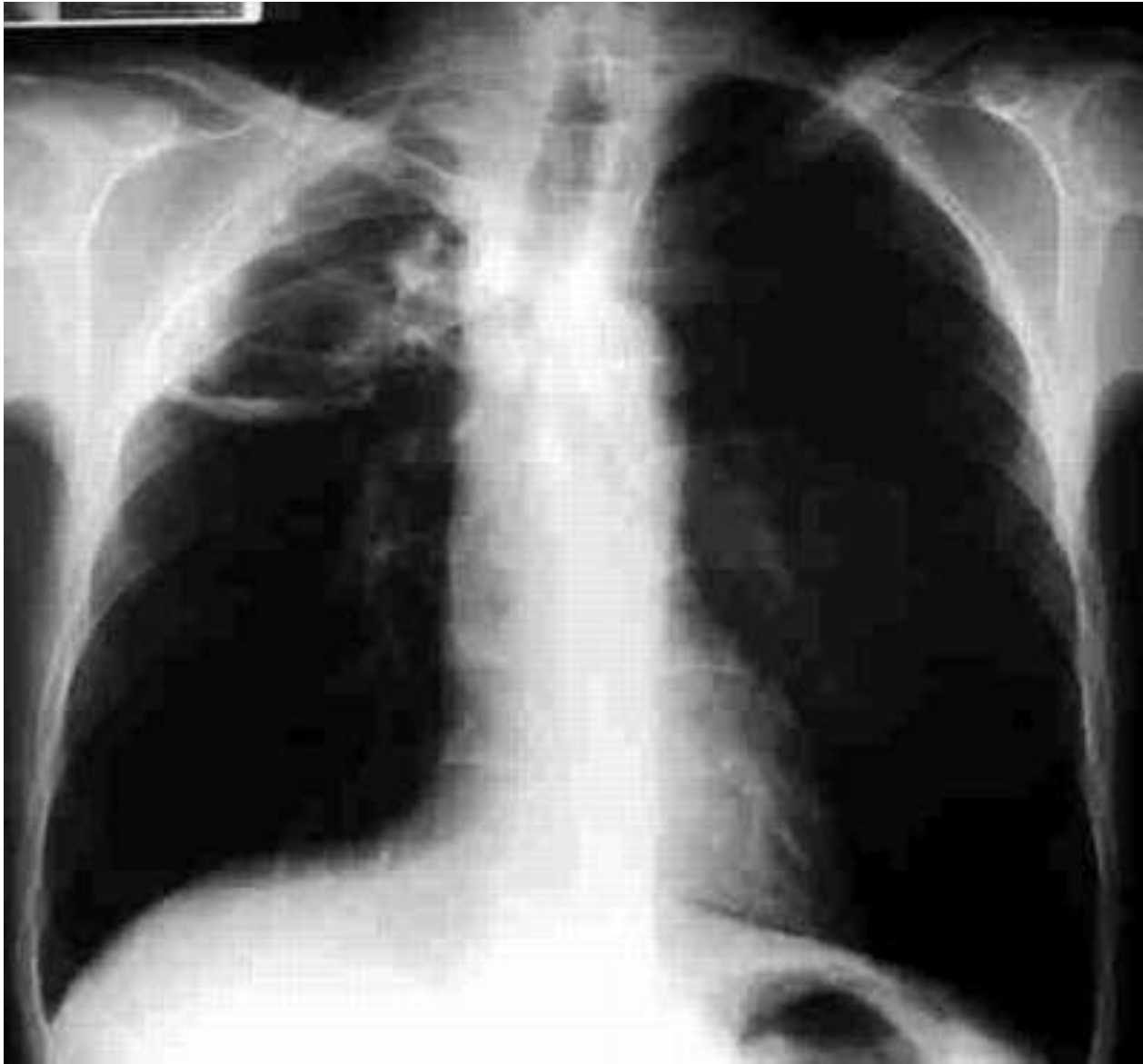
Abceso pulmonar



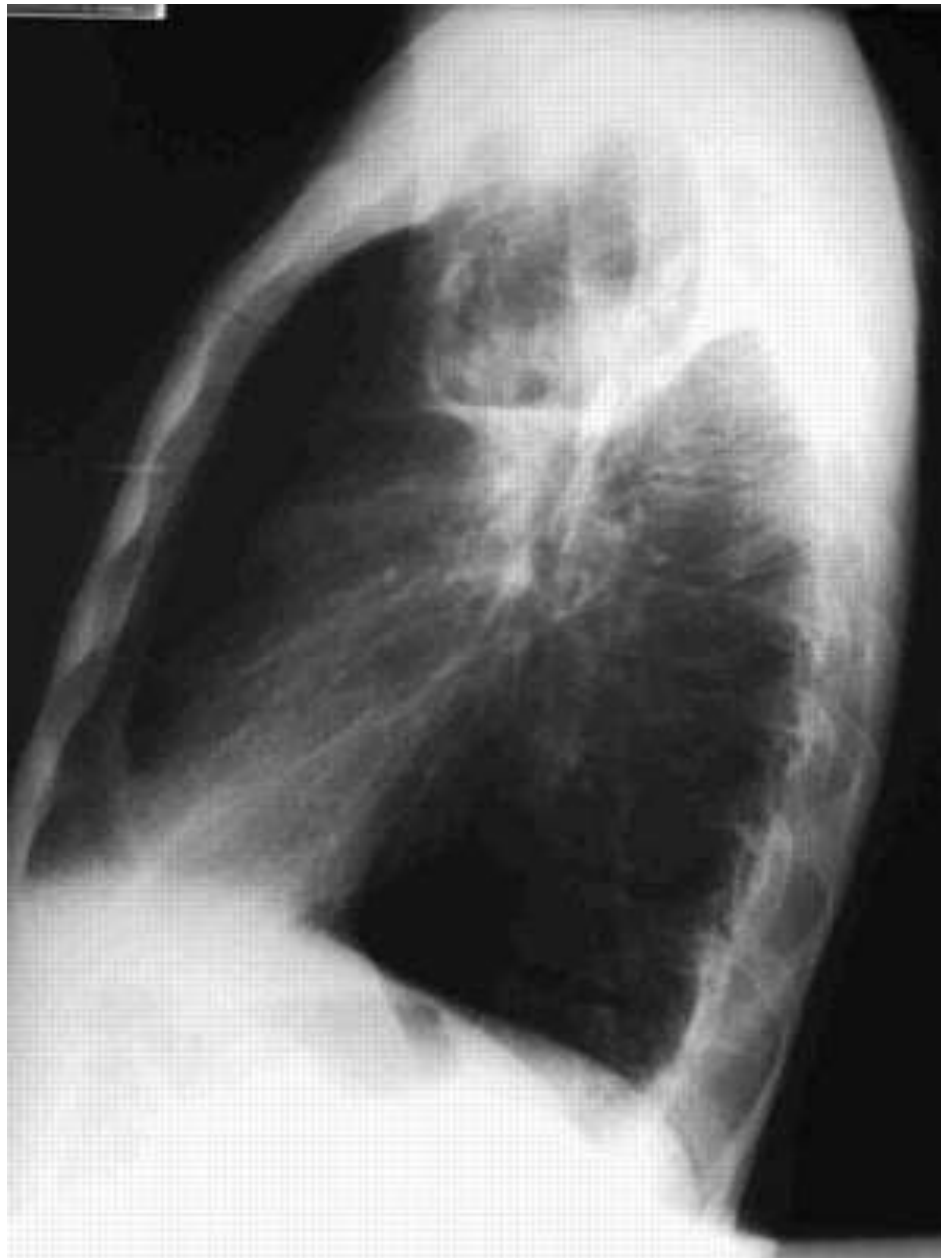Abceso pulmonar



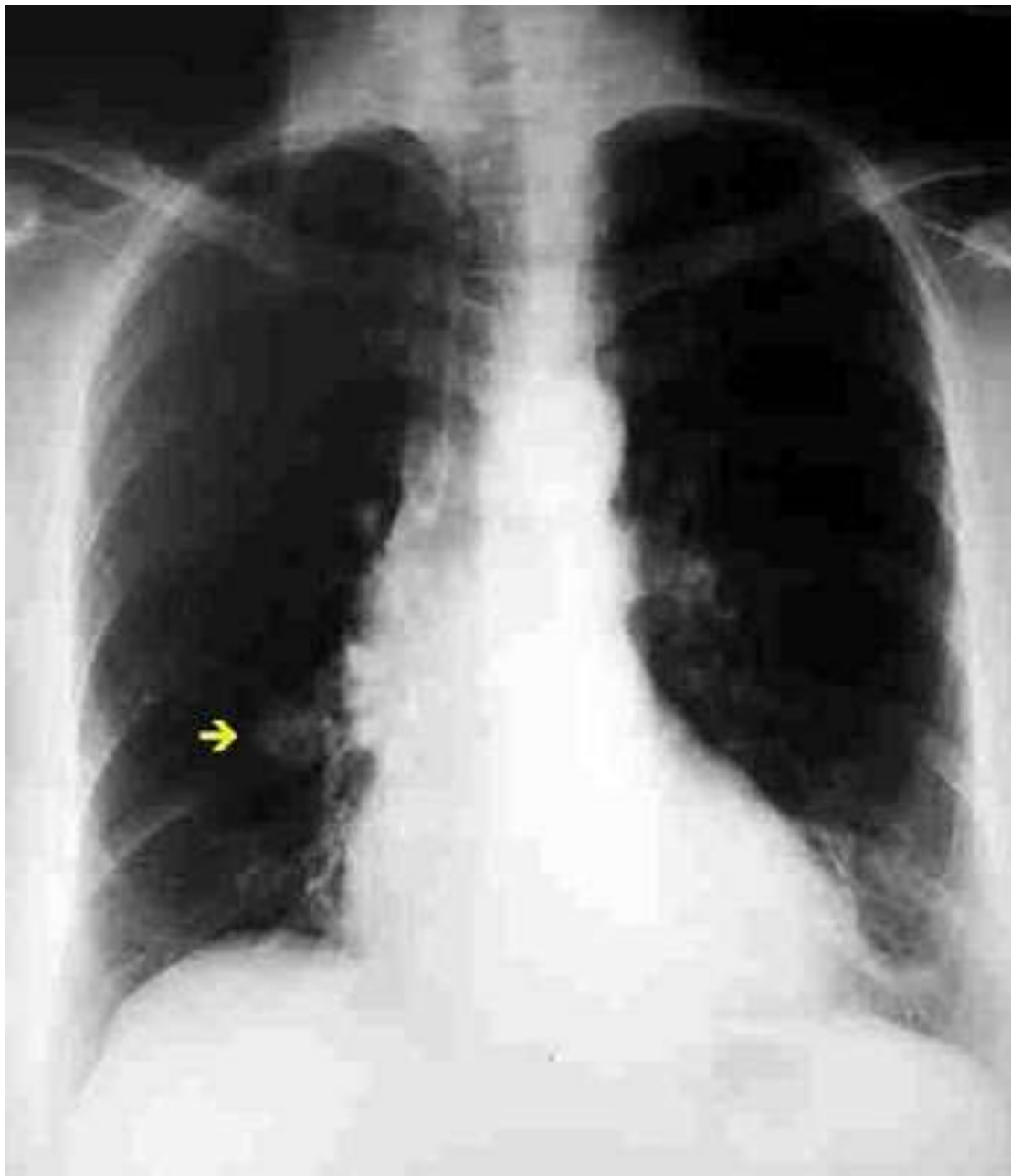
Abceso pulmonar



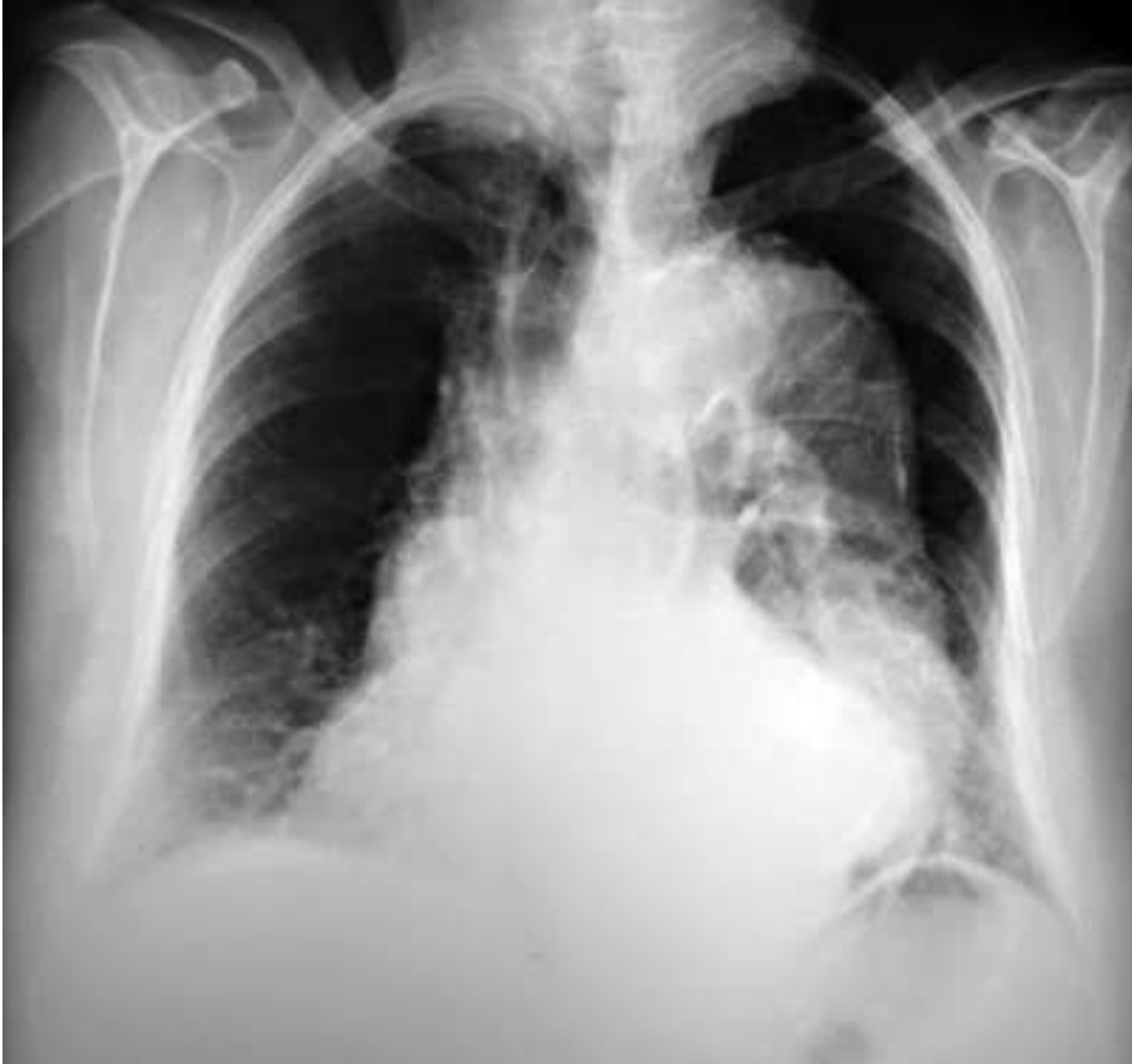Abceso pulmonar en paciente VIH



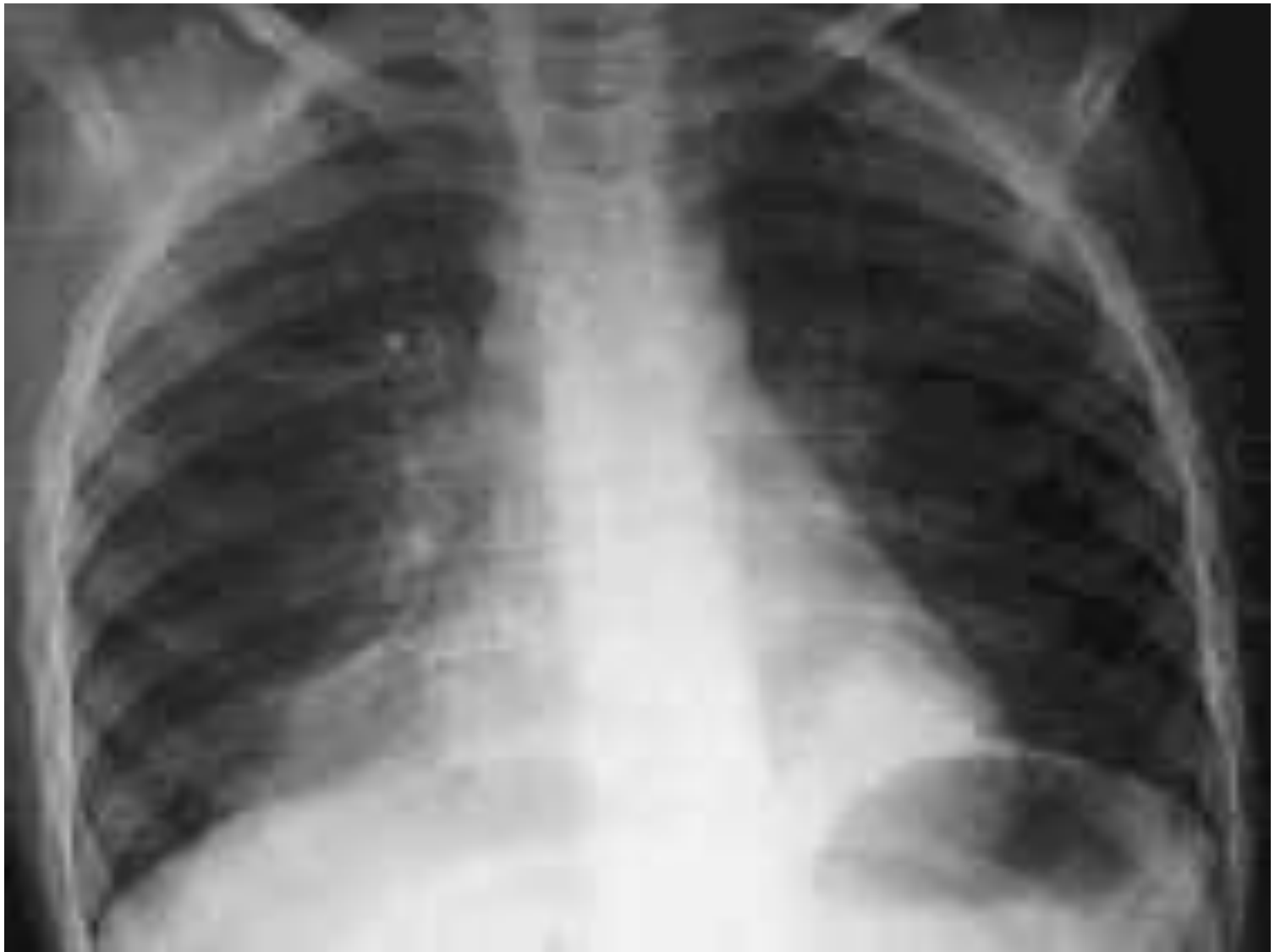Abceso pulmonar en paciente VIH



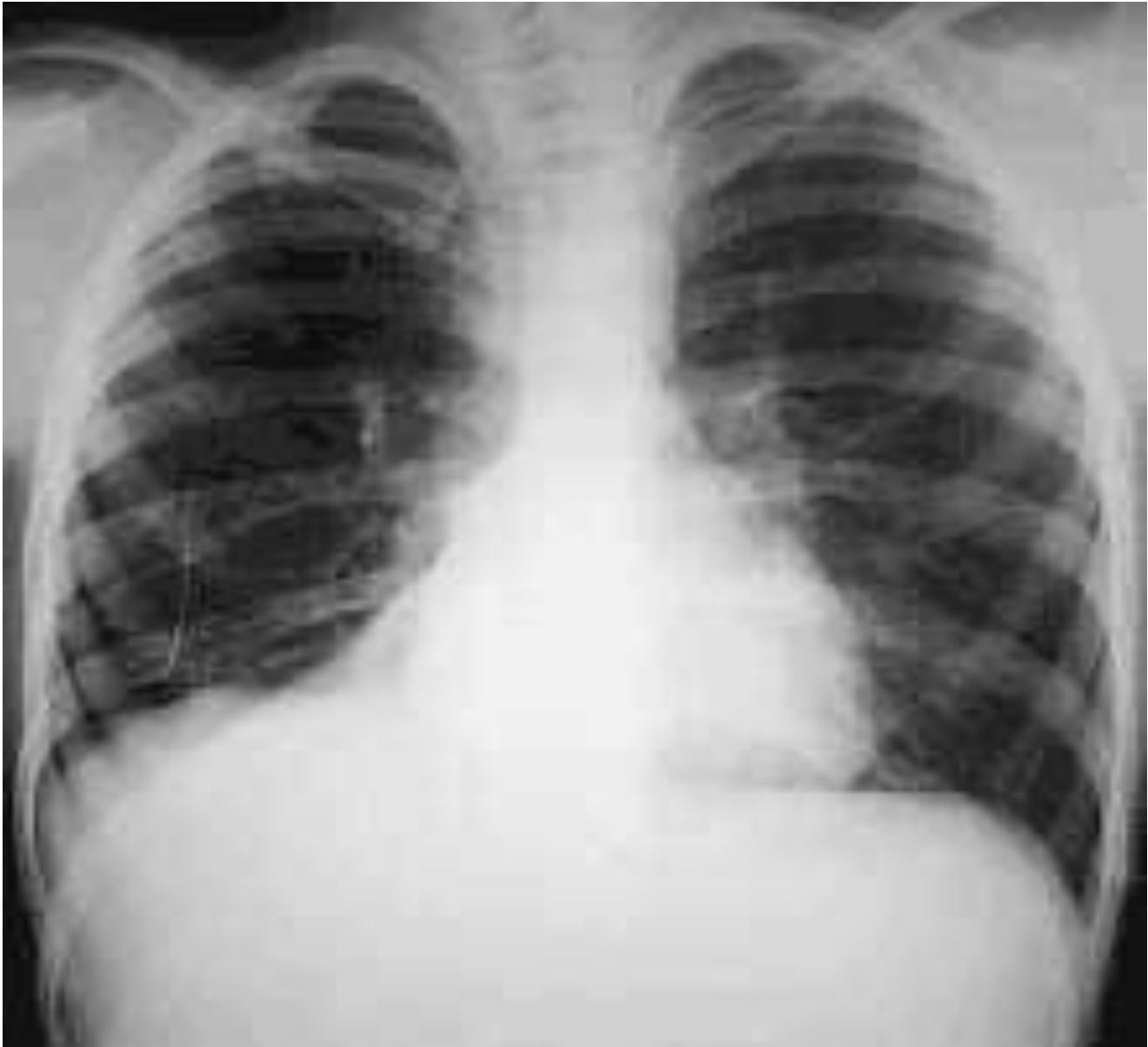adenoma



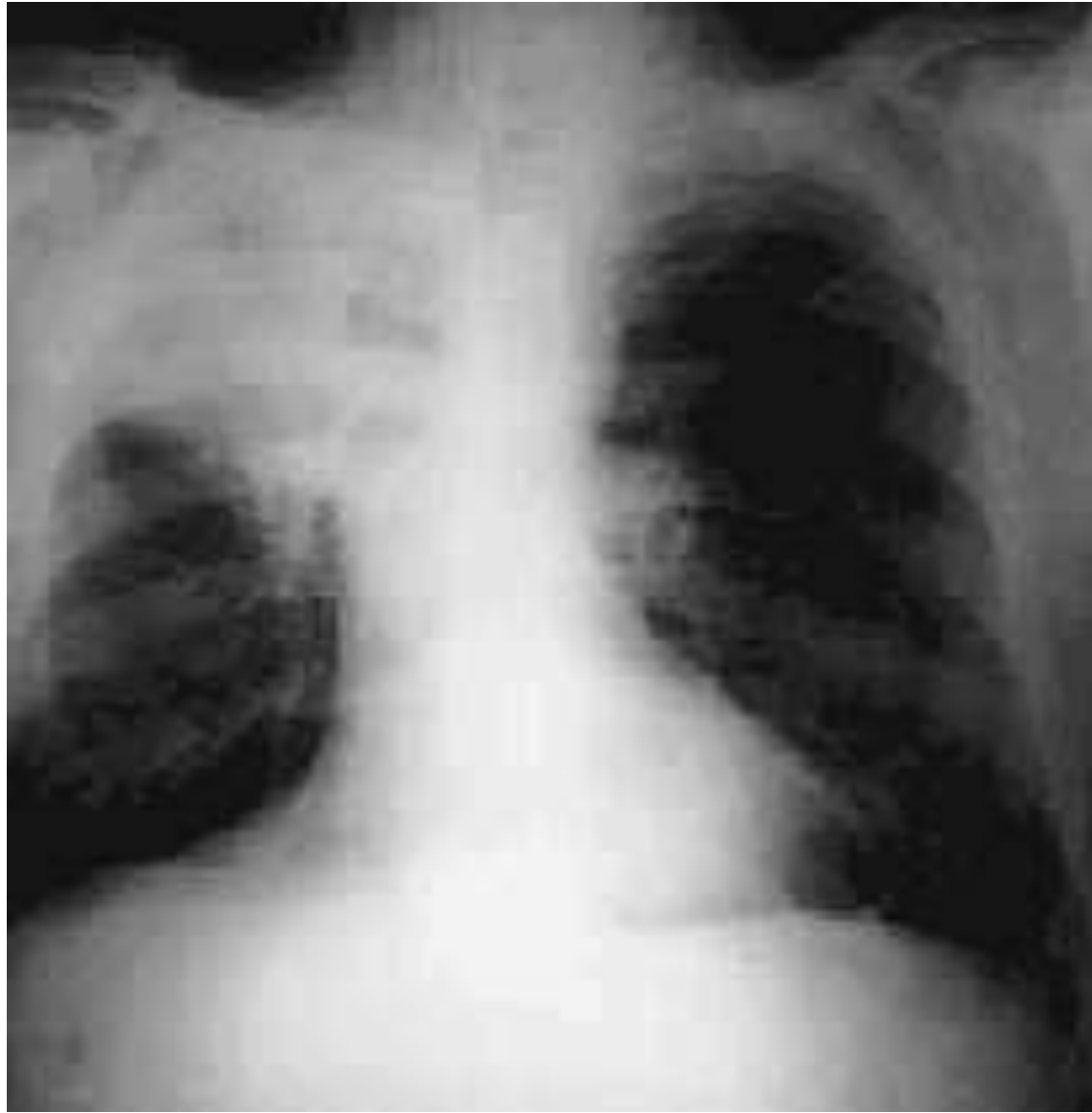Aneurisma aorta



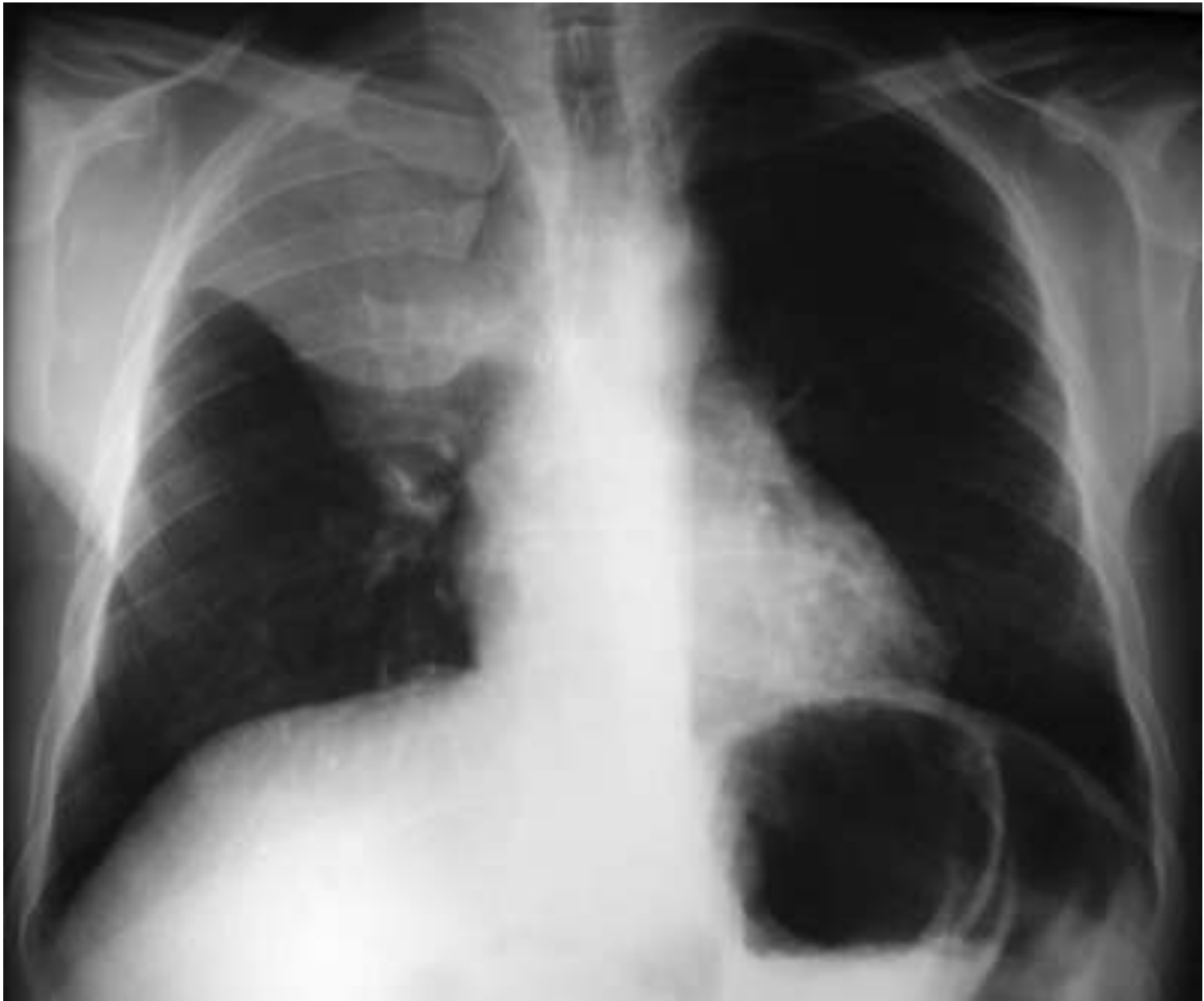Atelectasia LID



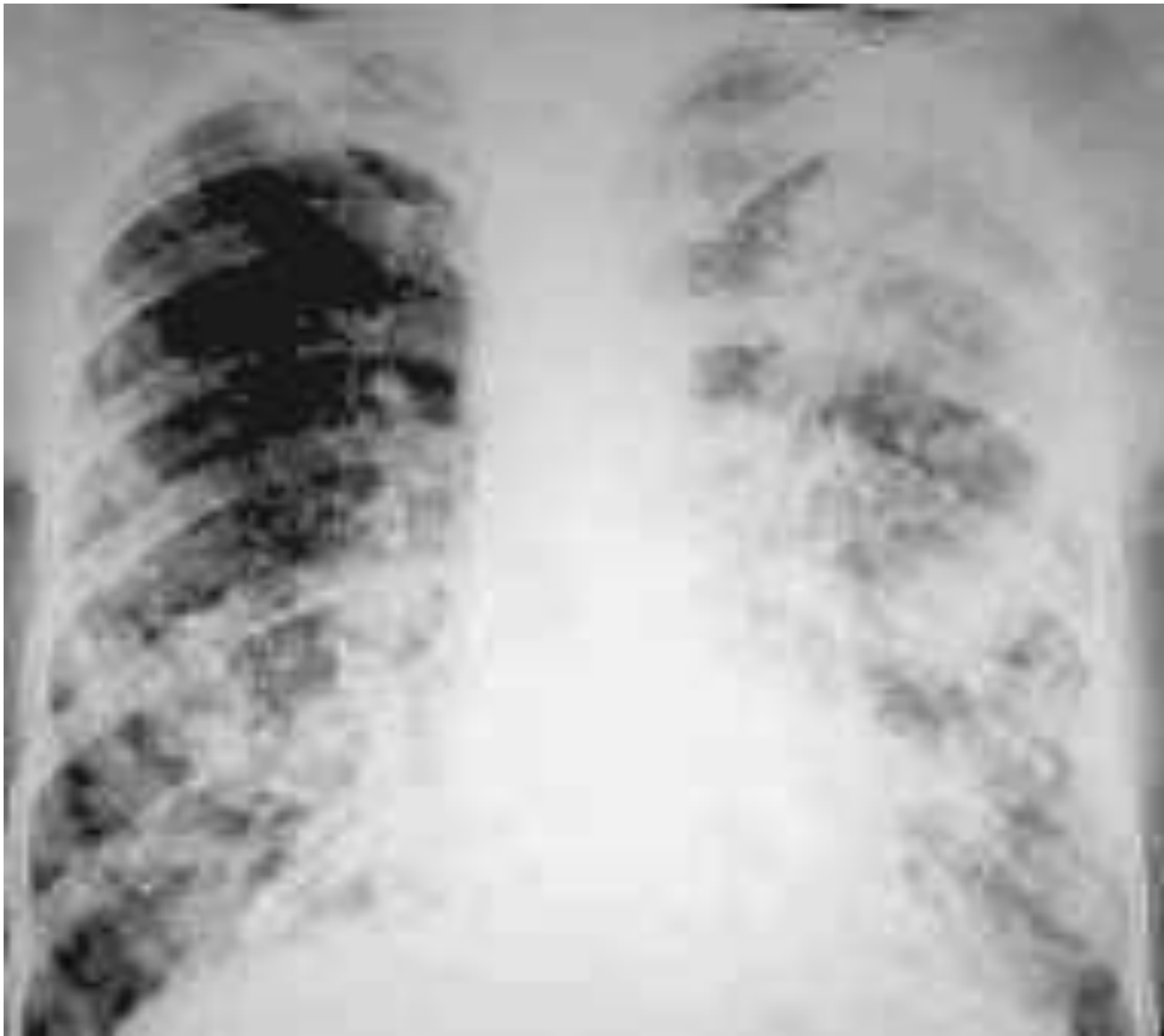Atelectasia LID



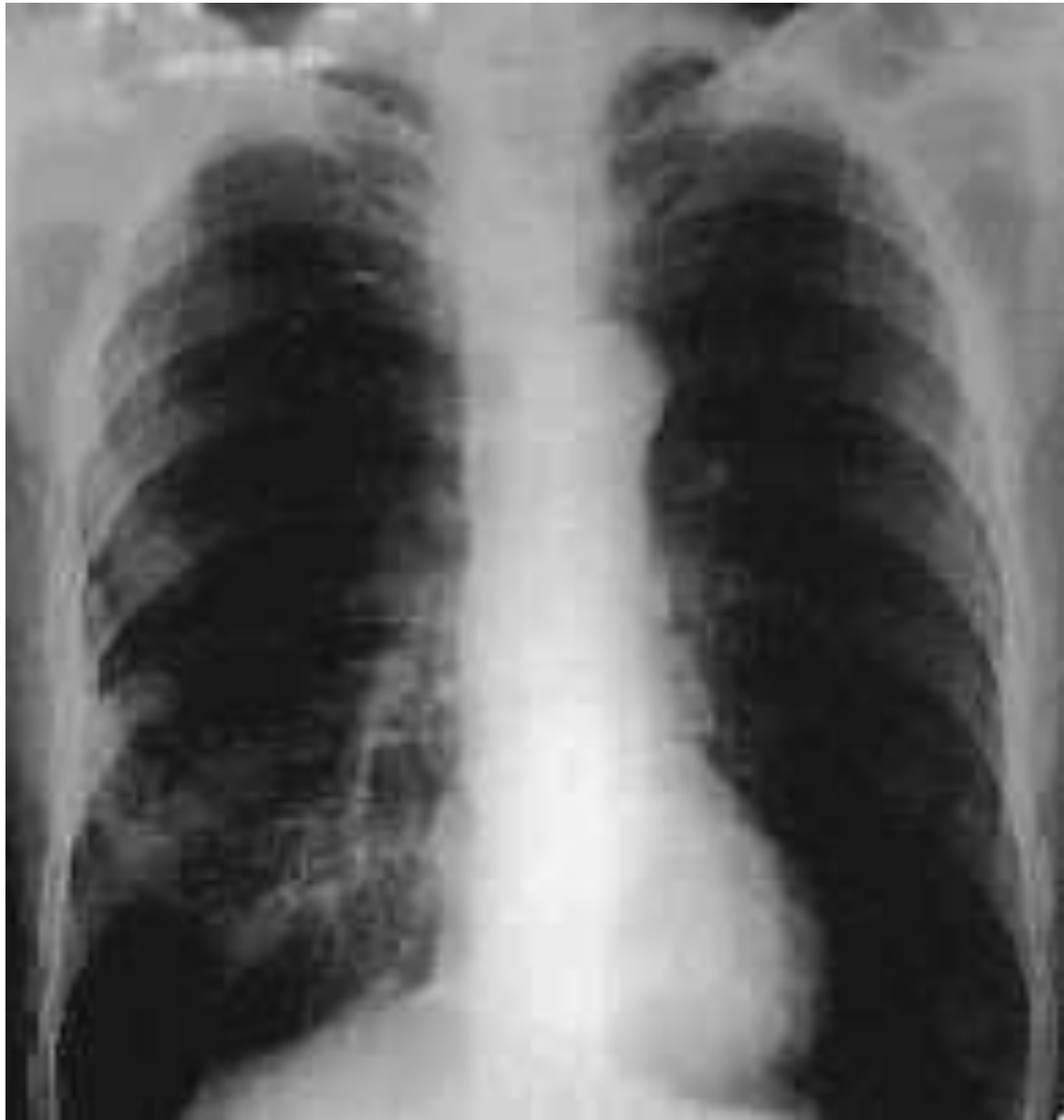Atelectasia LSD



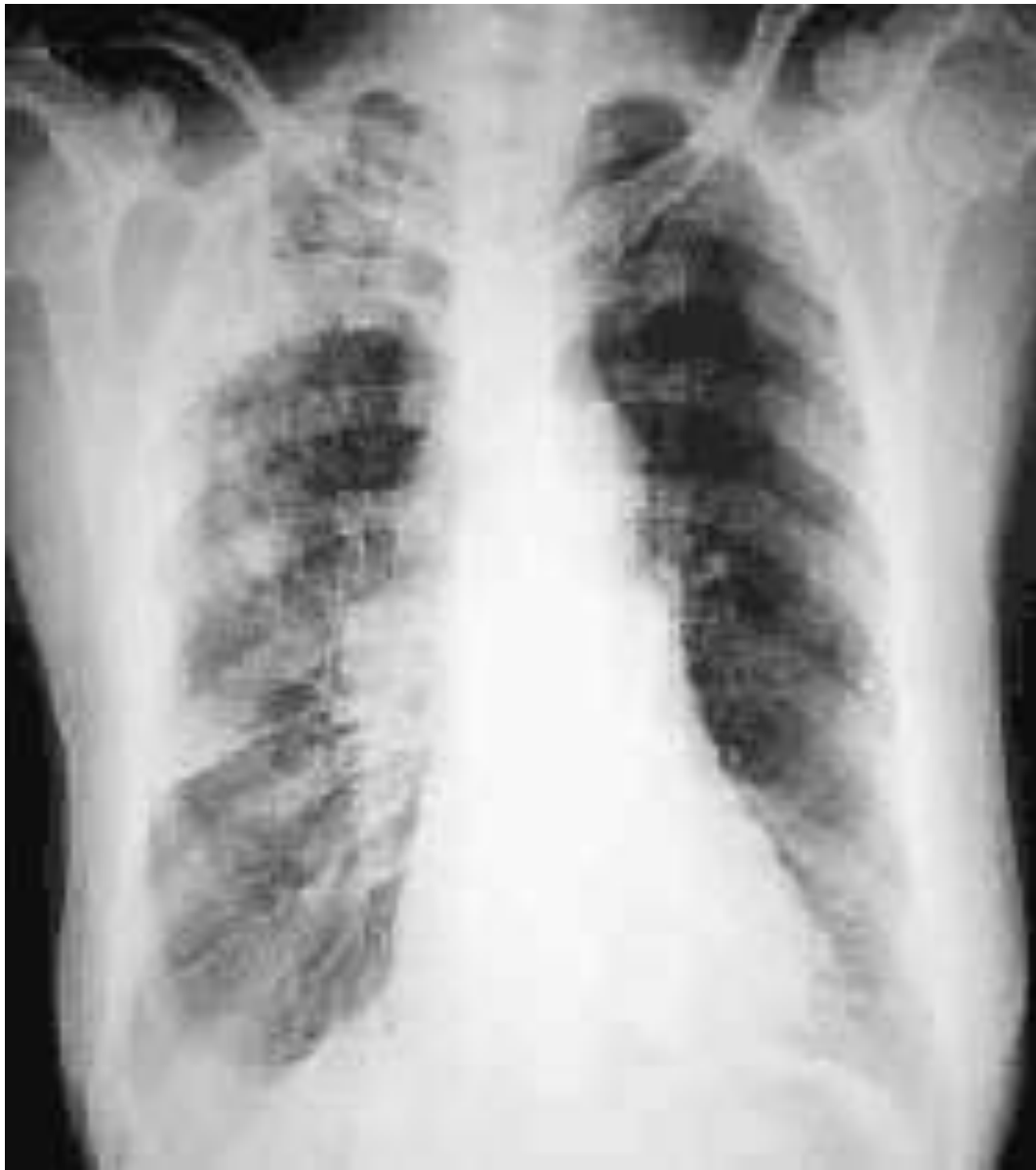Atelectasia LSD y masa hilar (S de Golden)



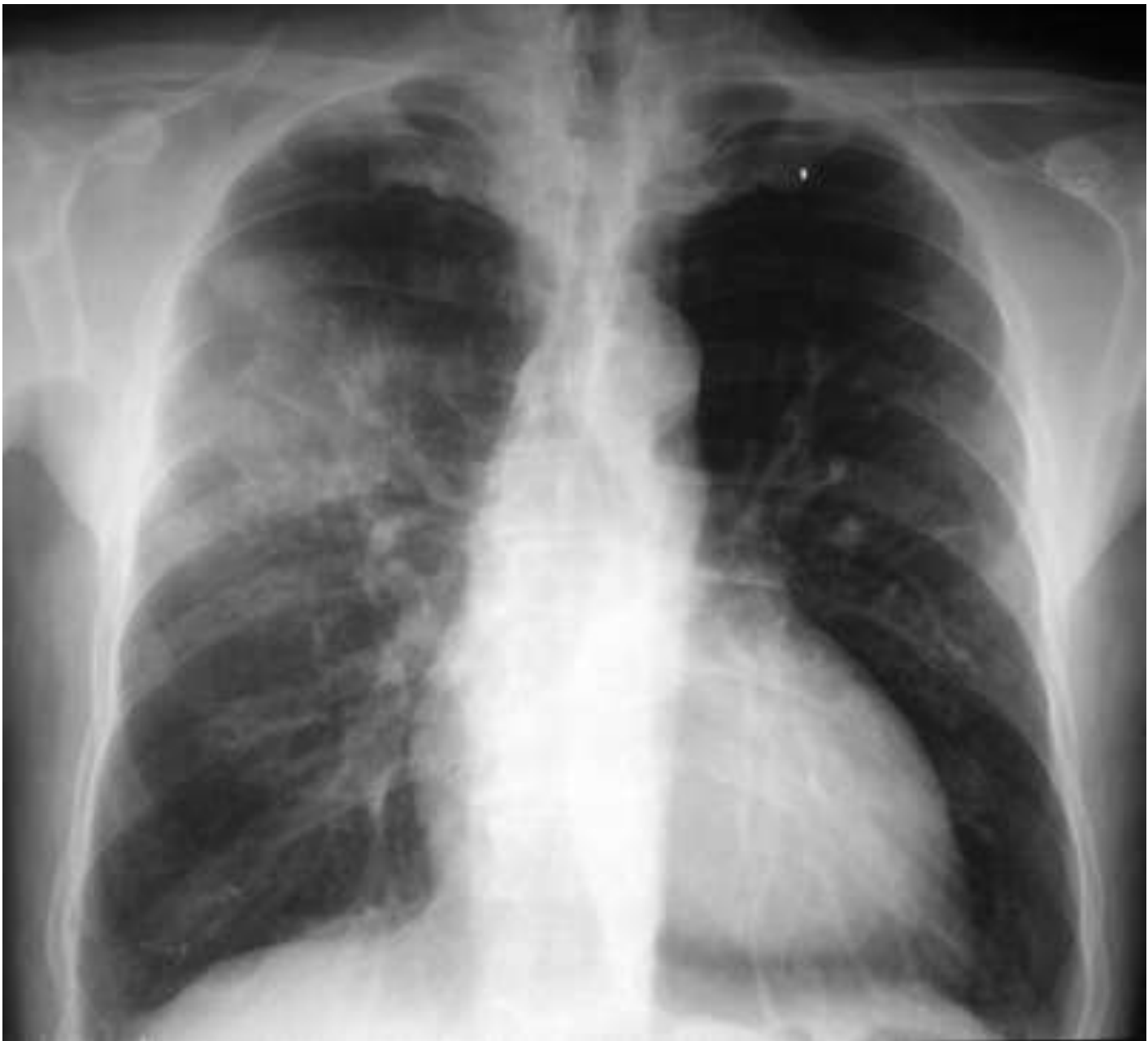Patrón alveolointerstitial difuso
(bronconeumonía)



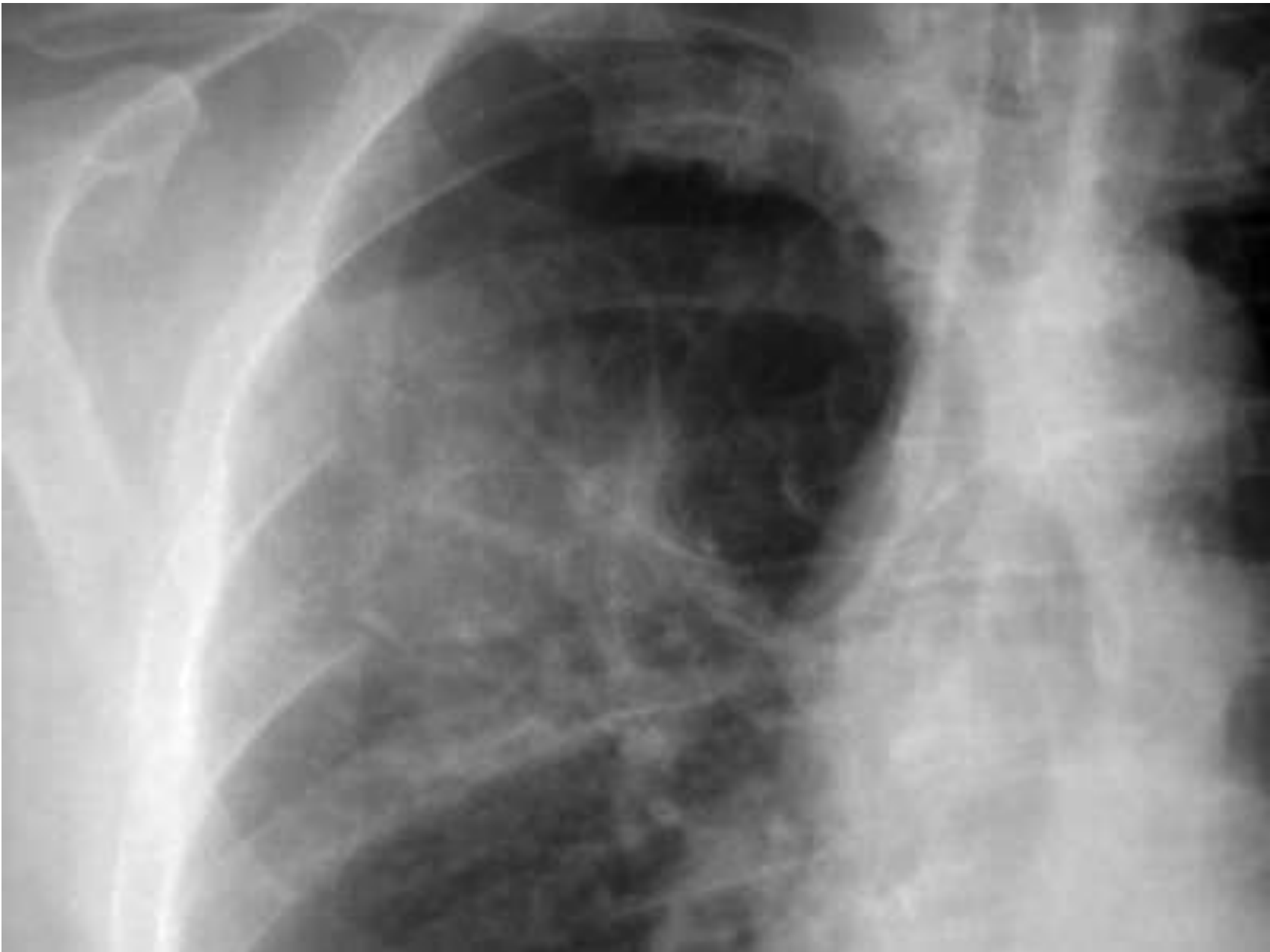Bronquiectasias saculares LMD

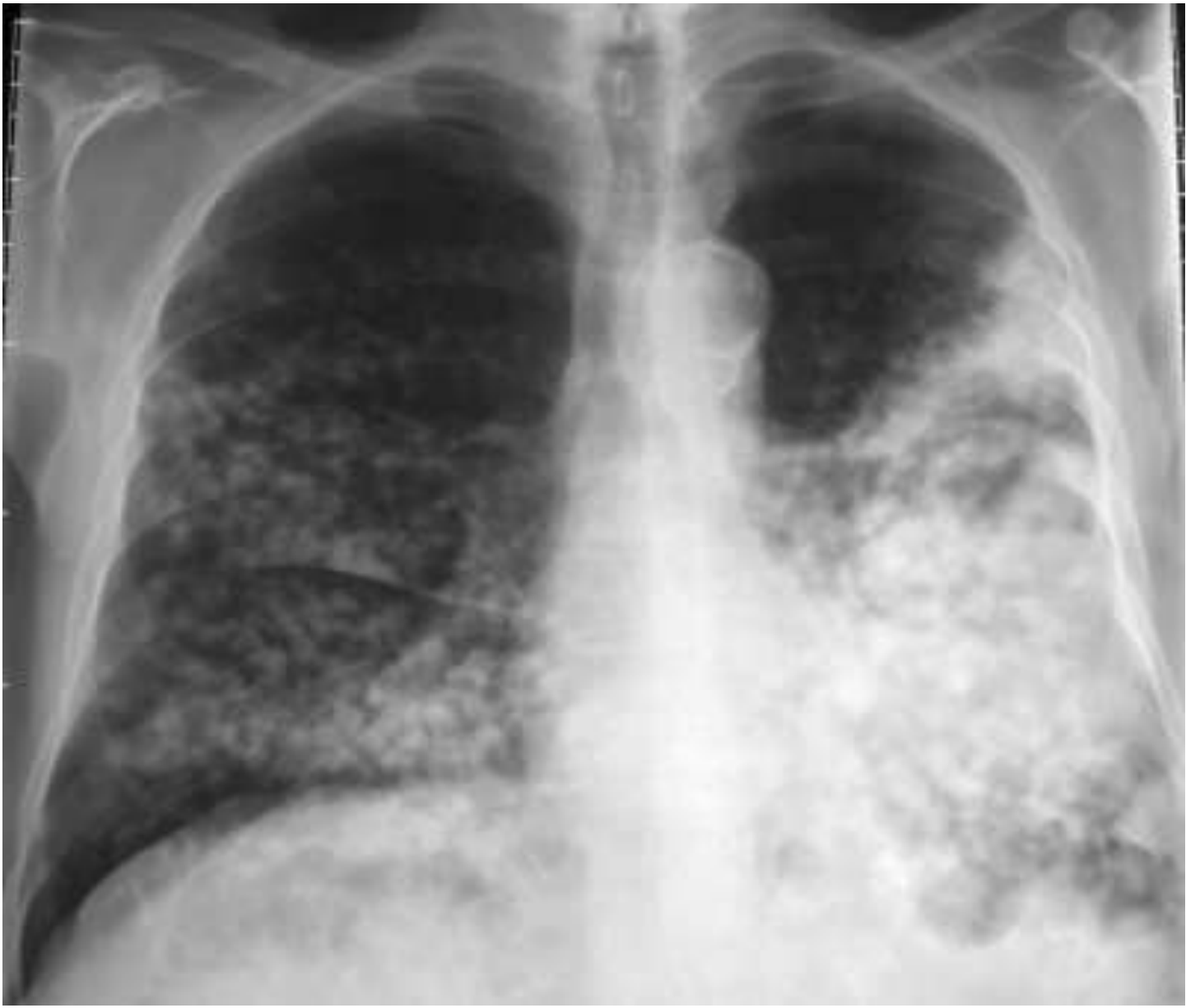


Bronquiectasias tubulares

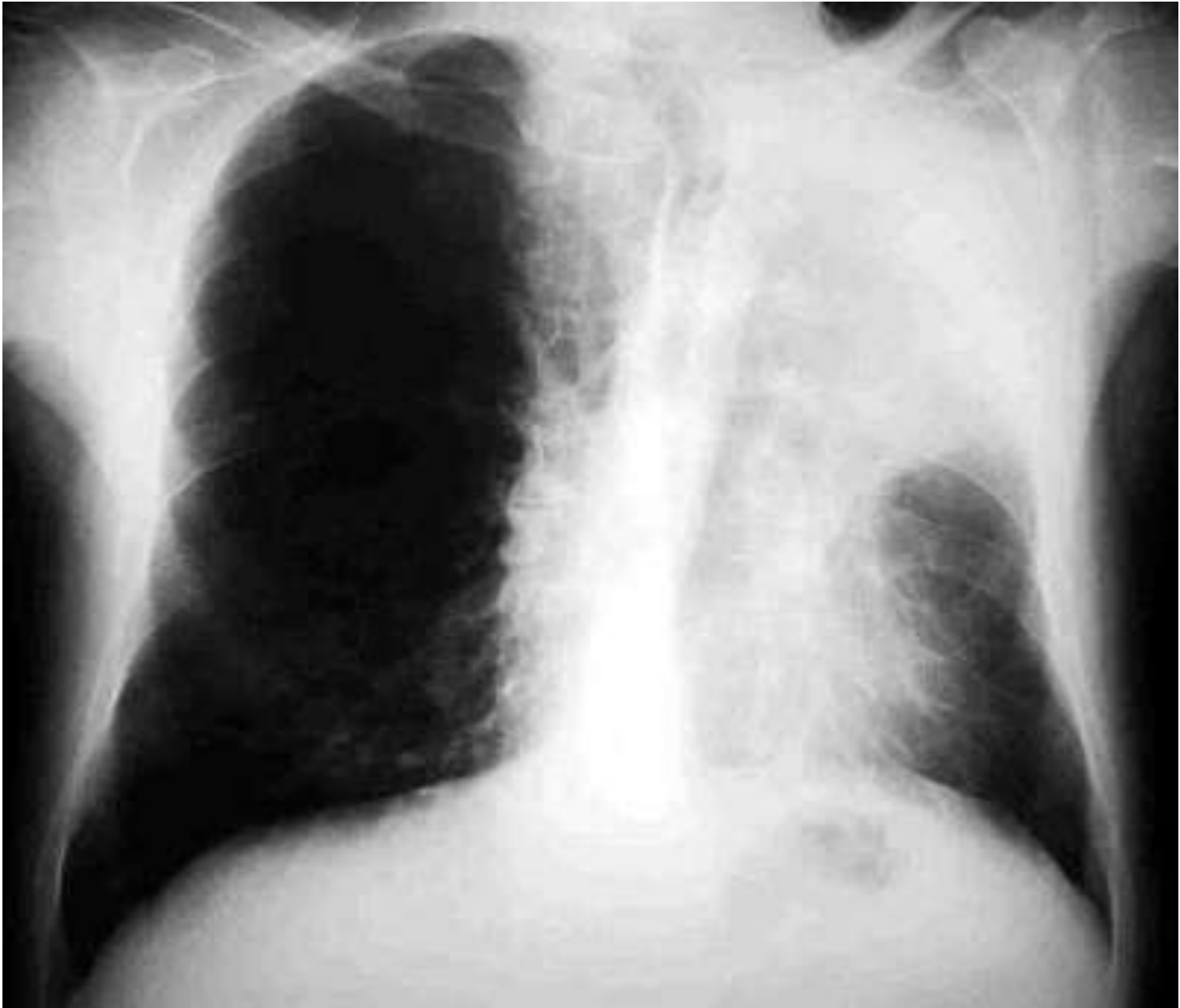


Ca broncogénico con MTX óseas

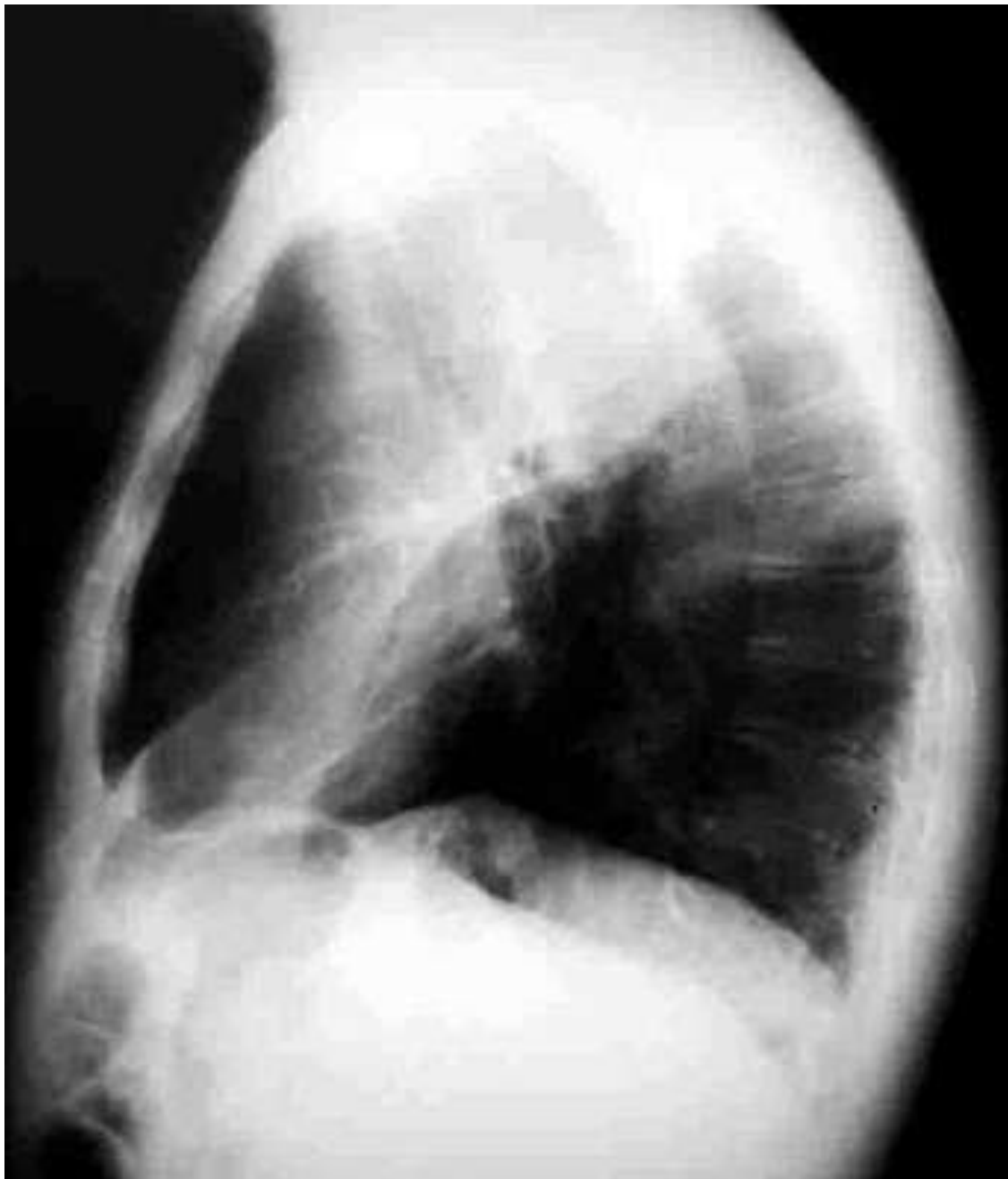


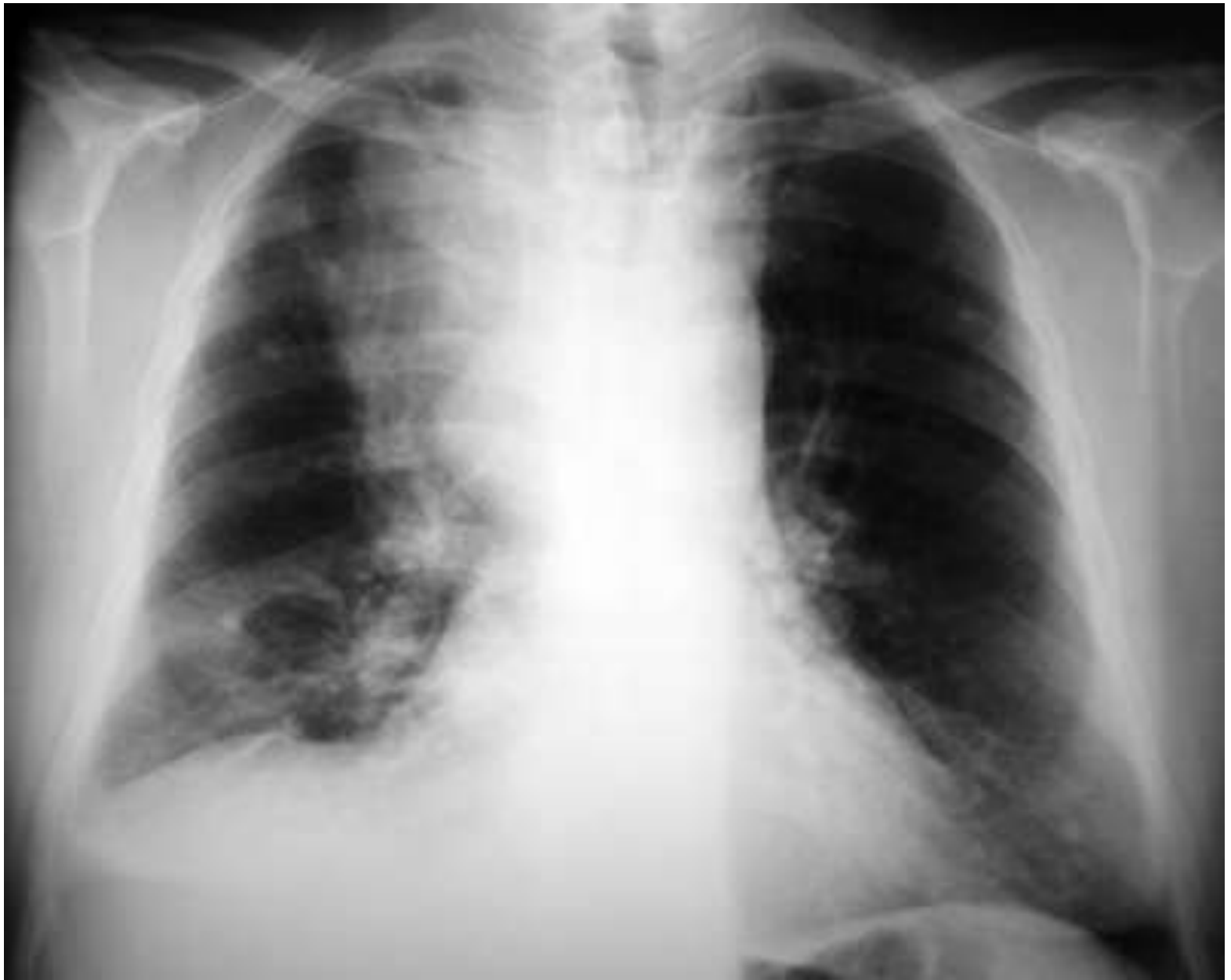
Carcinoma bronquioalveolar

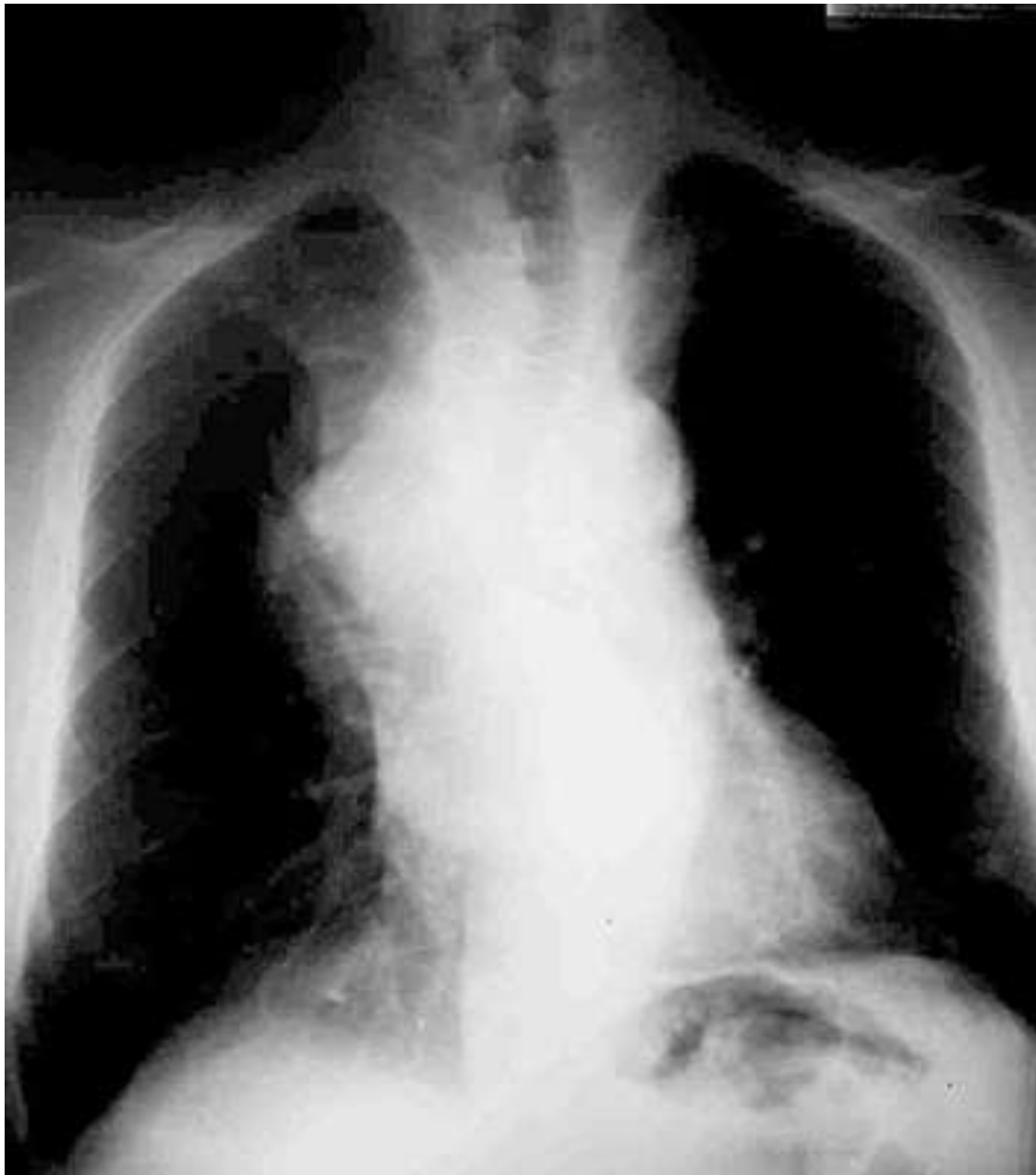

Ca epidermoide LSI

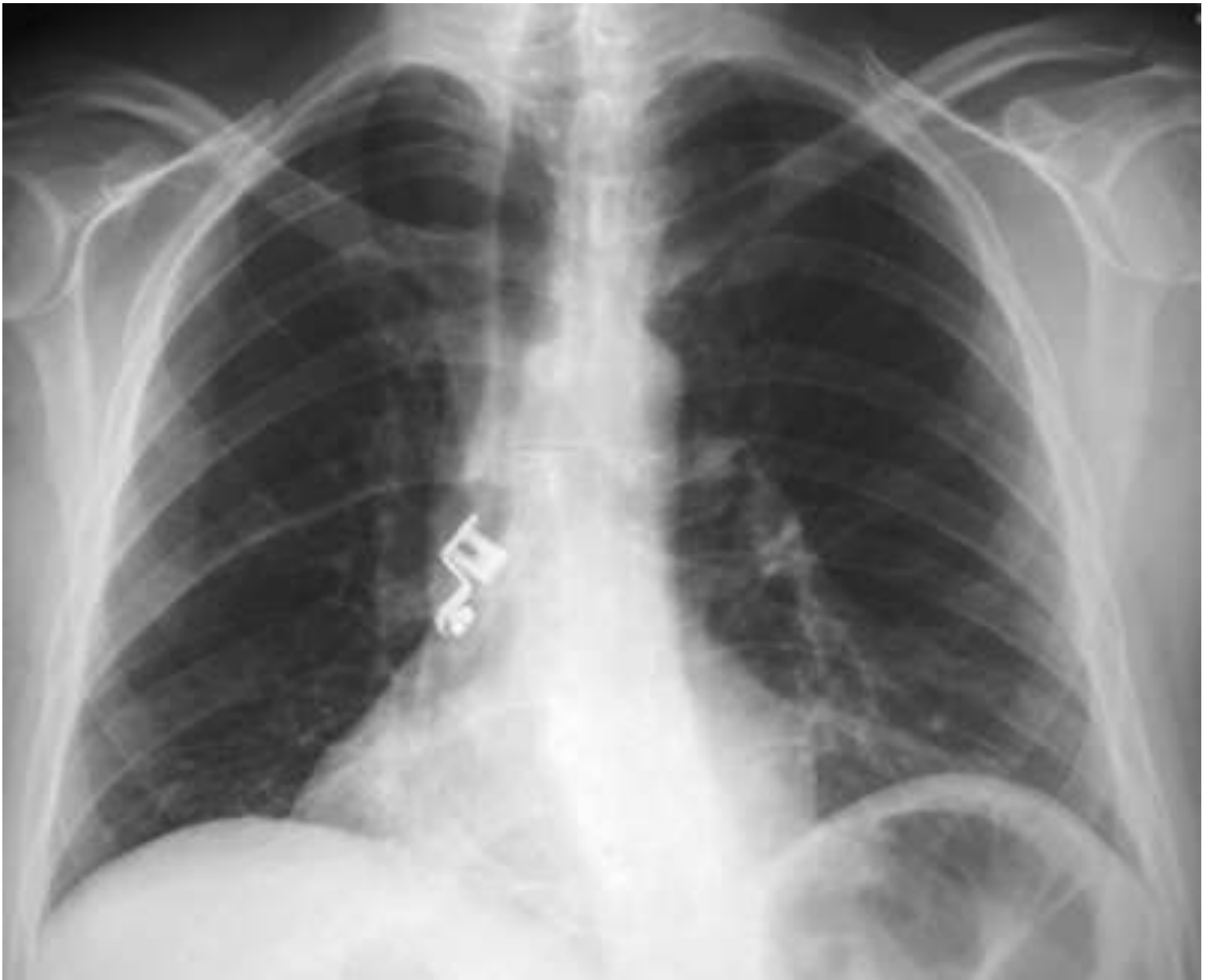



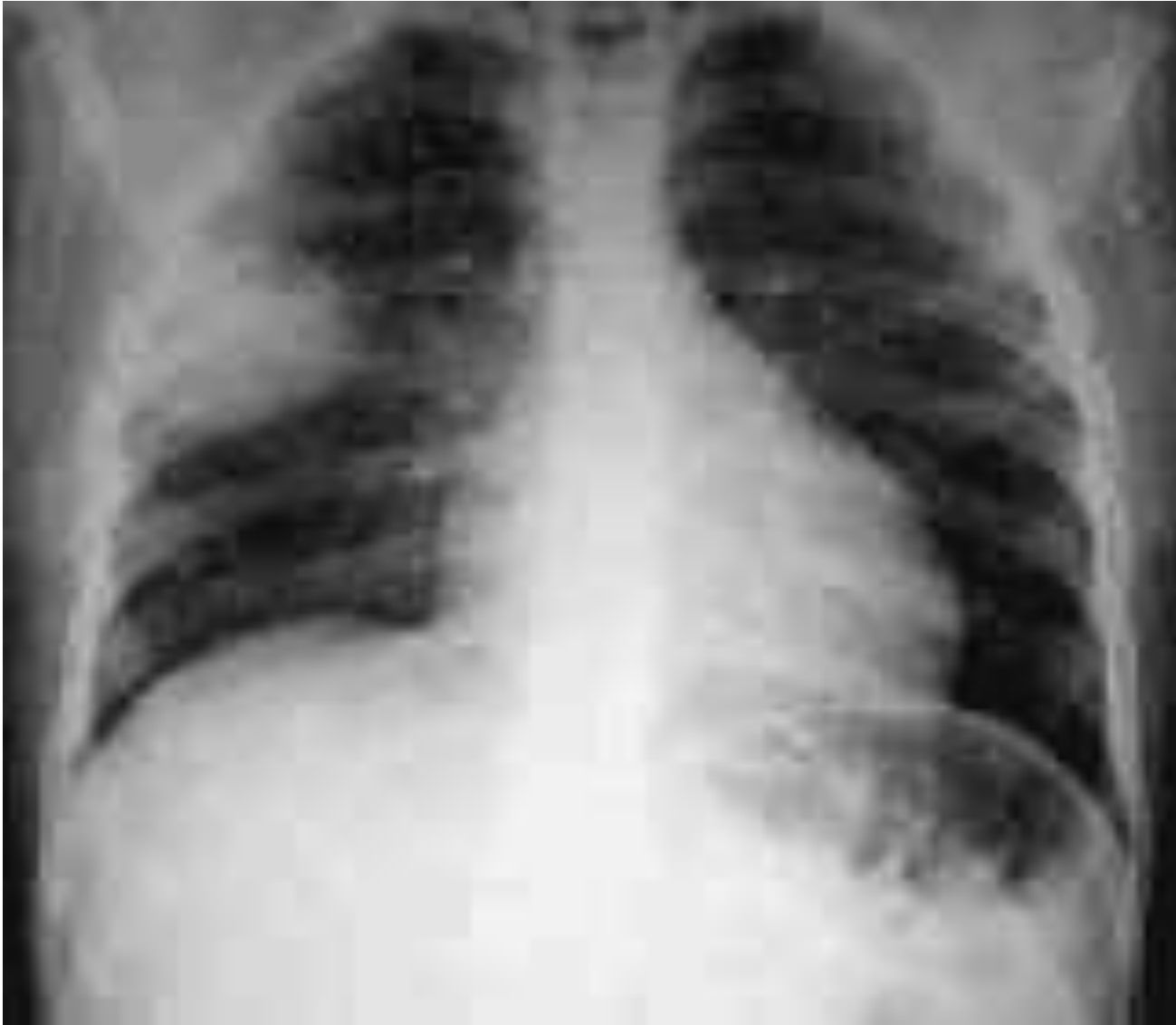Ca microcítico



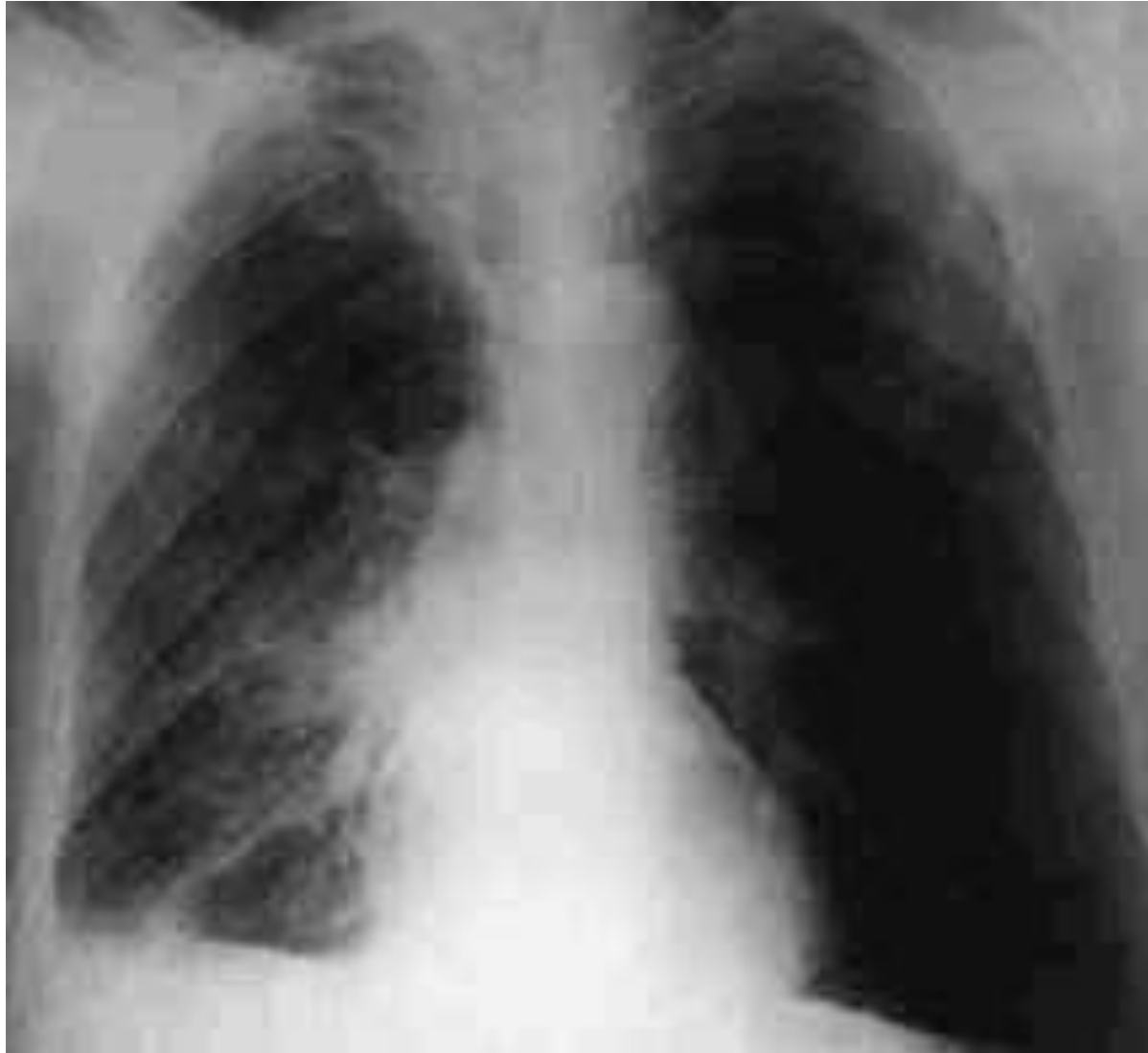Ca microcítico



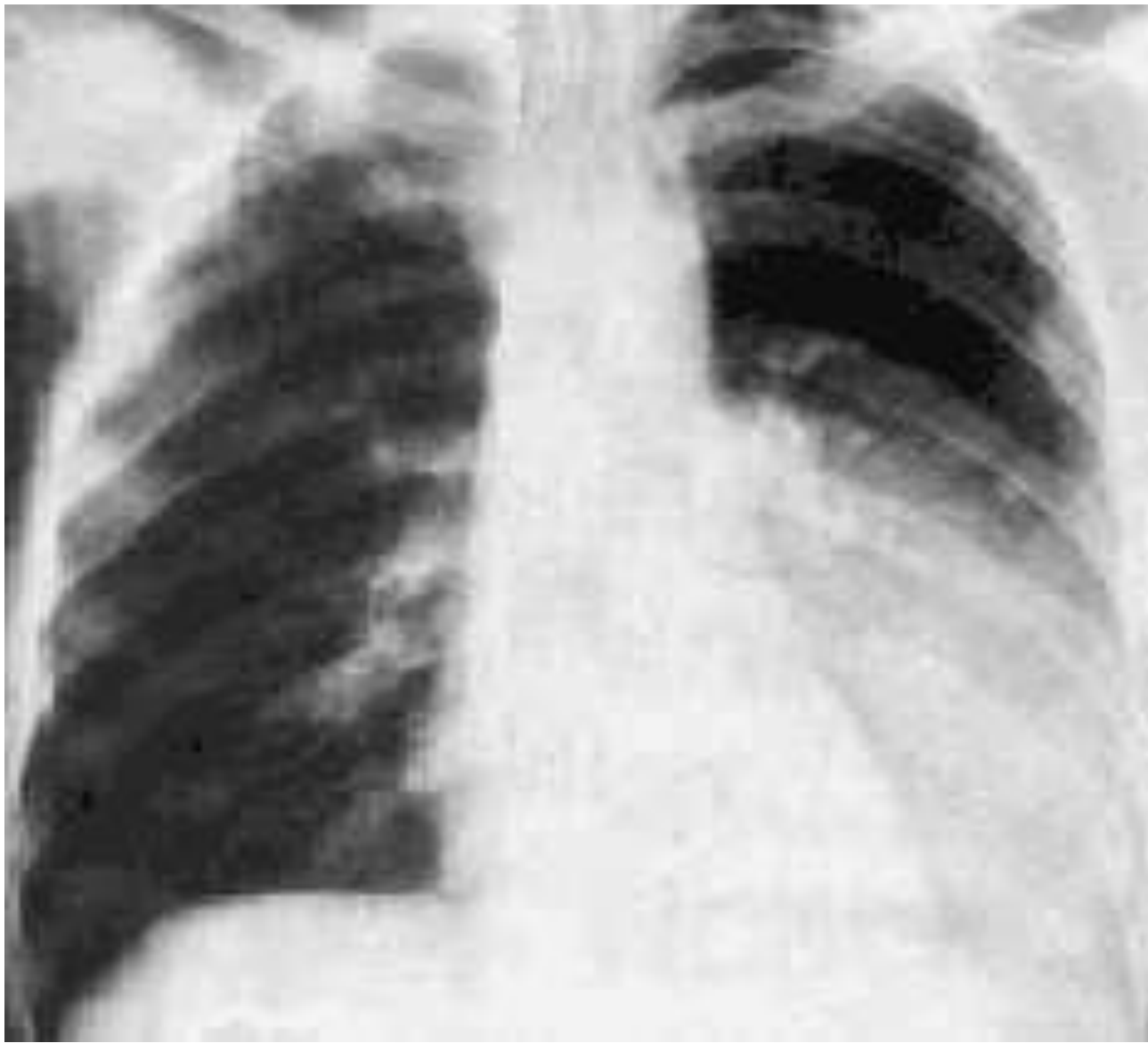
C.Extraño bronquio intermediario



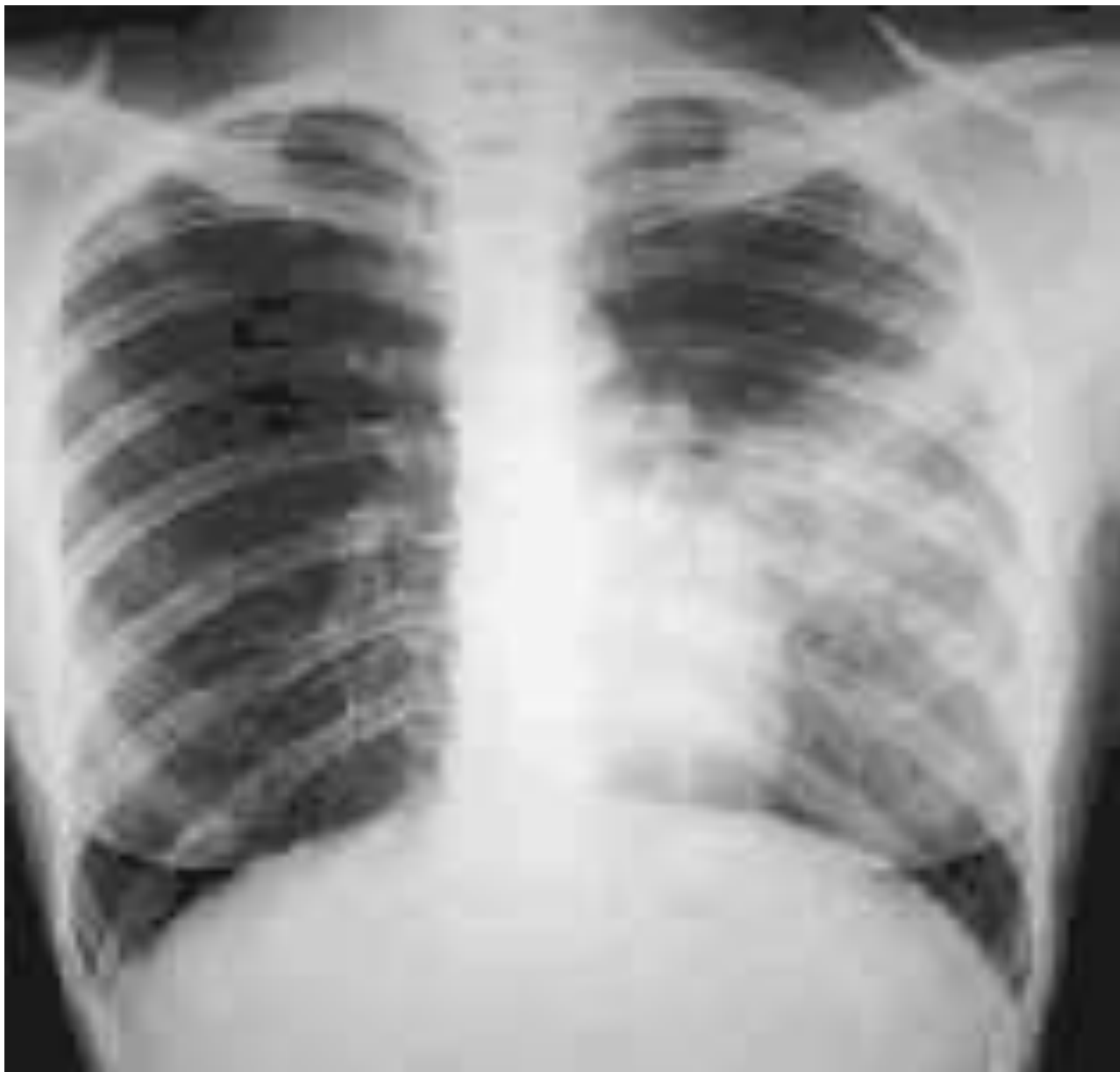Condensación de aspecto nodular



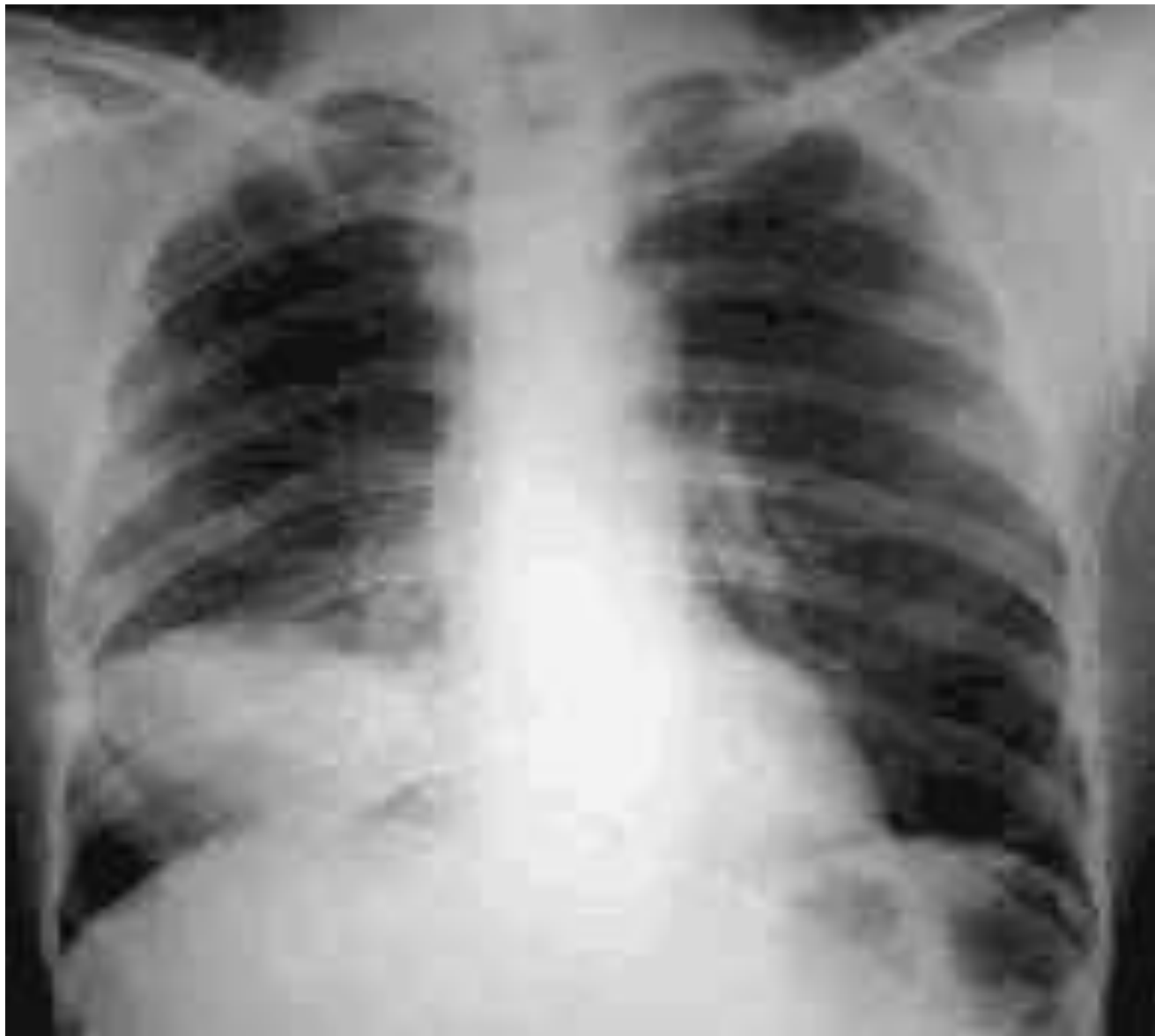Condensación hiliar y derrame pleural con atelectasia



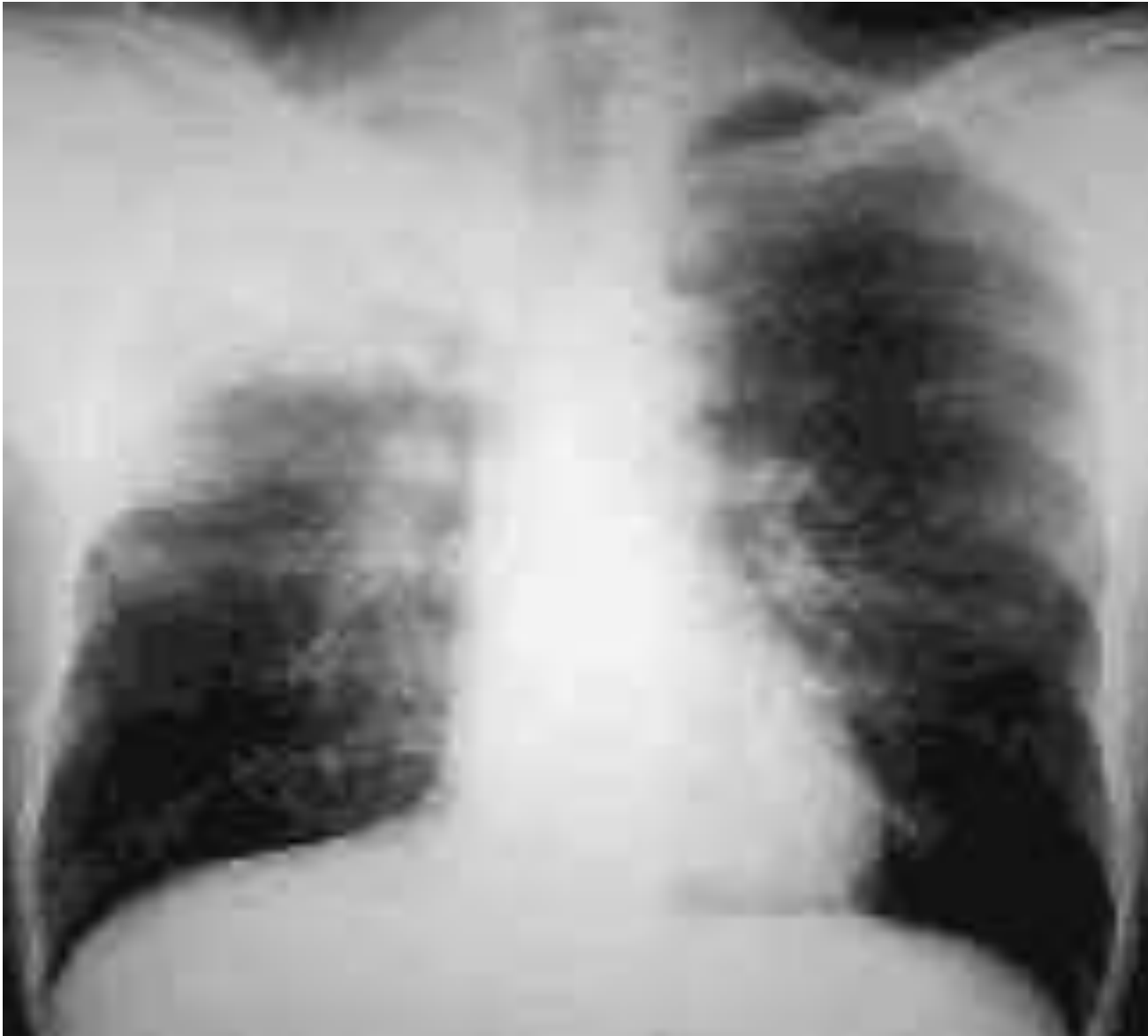Condensación LII



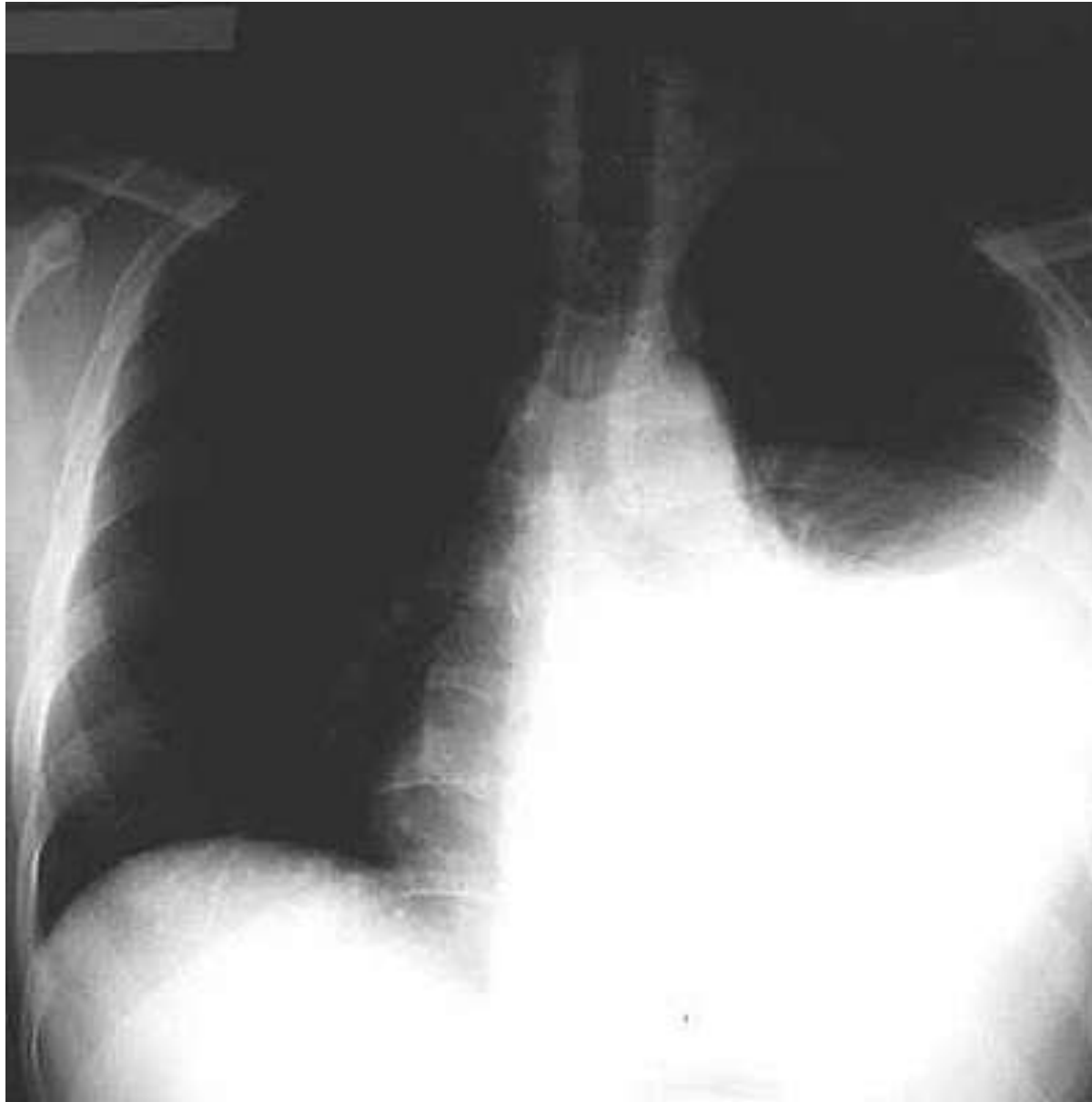Condensación llingula



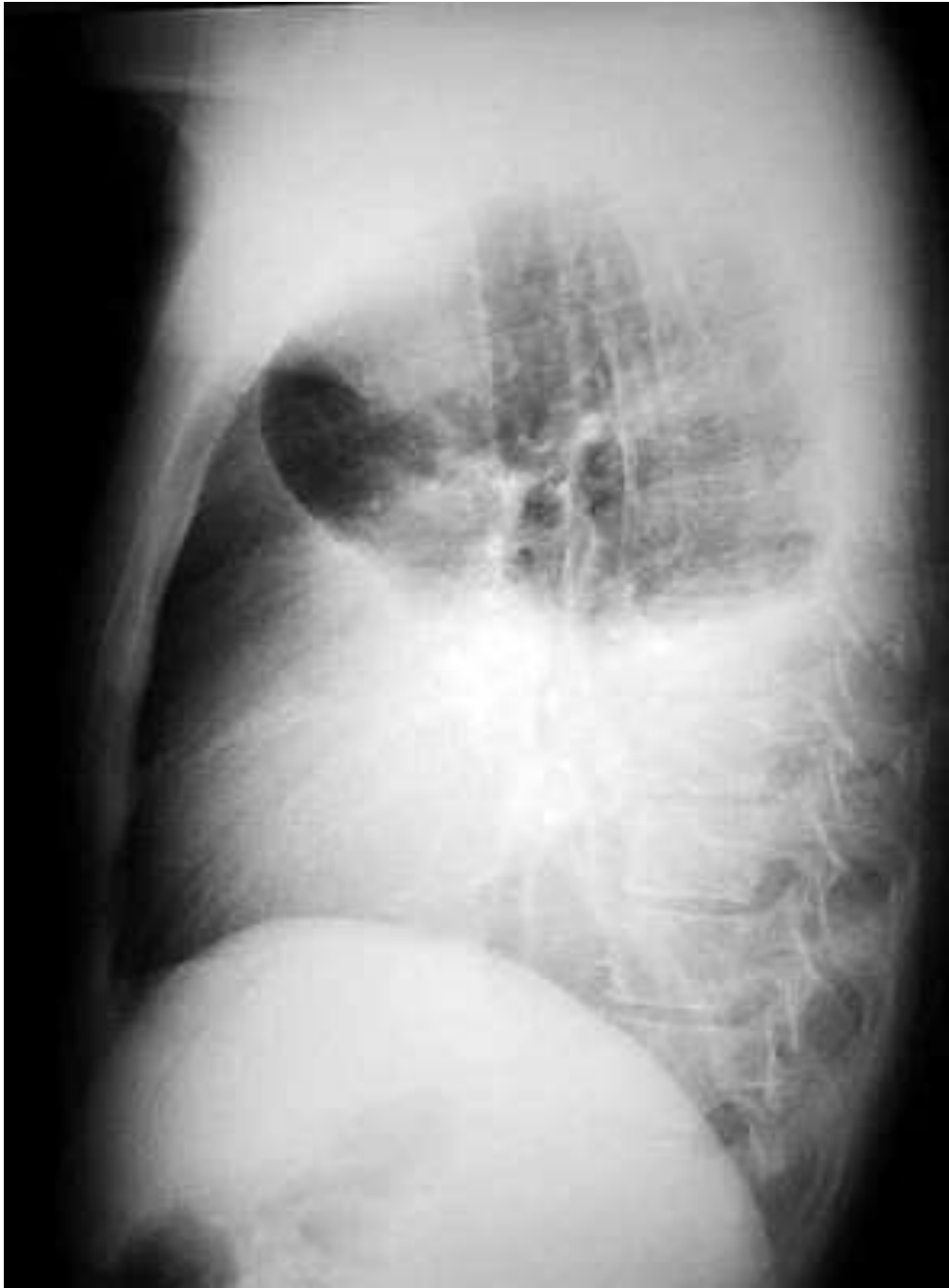
Condensación LMD

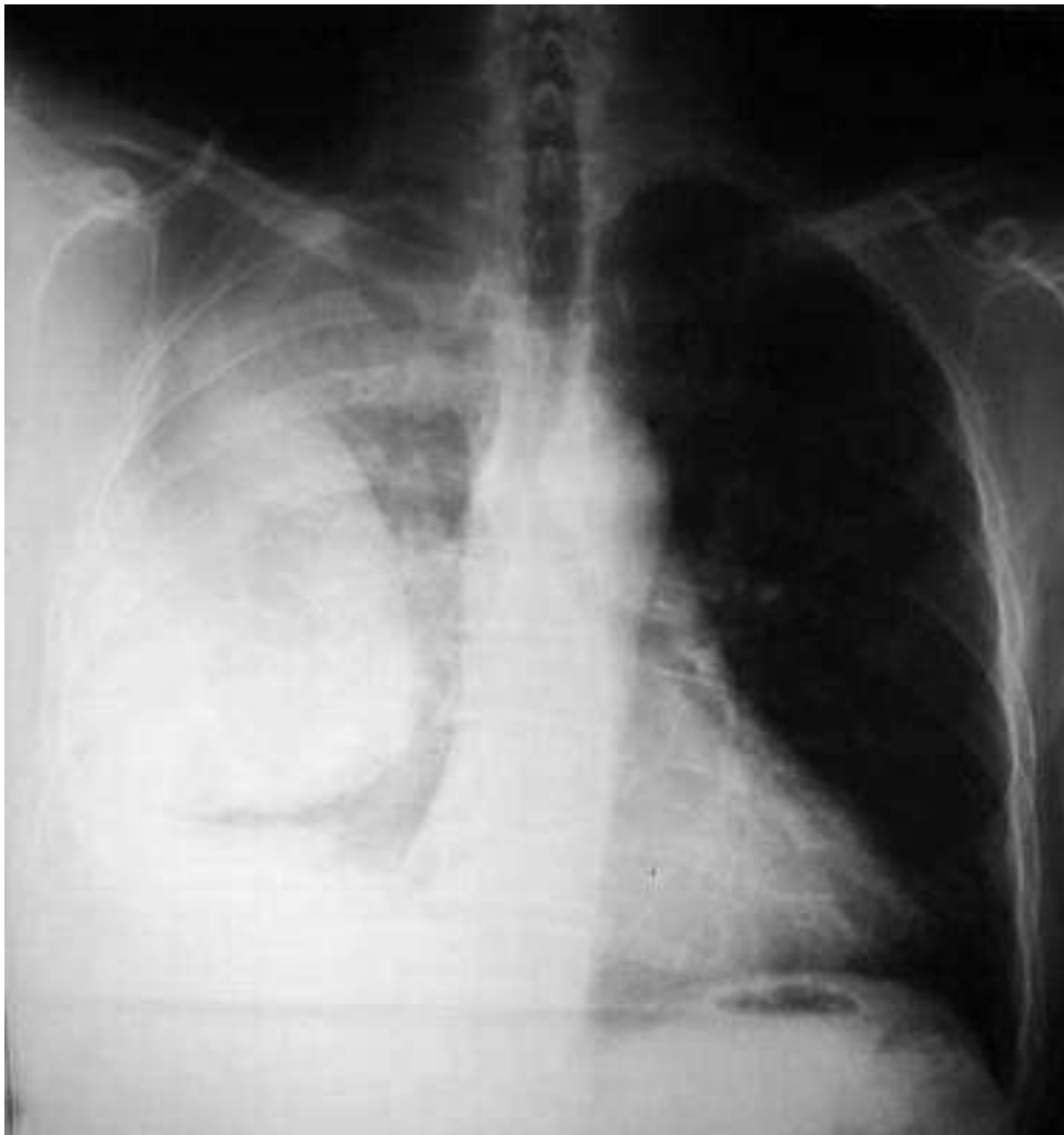

Condensación LSD

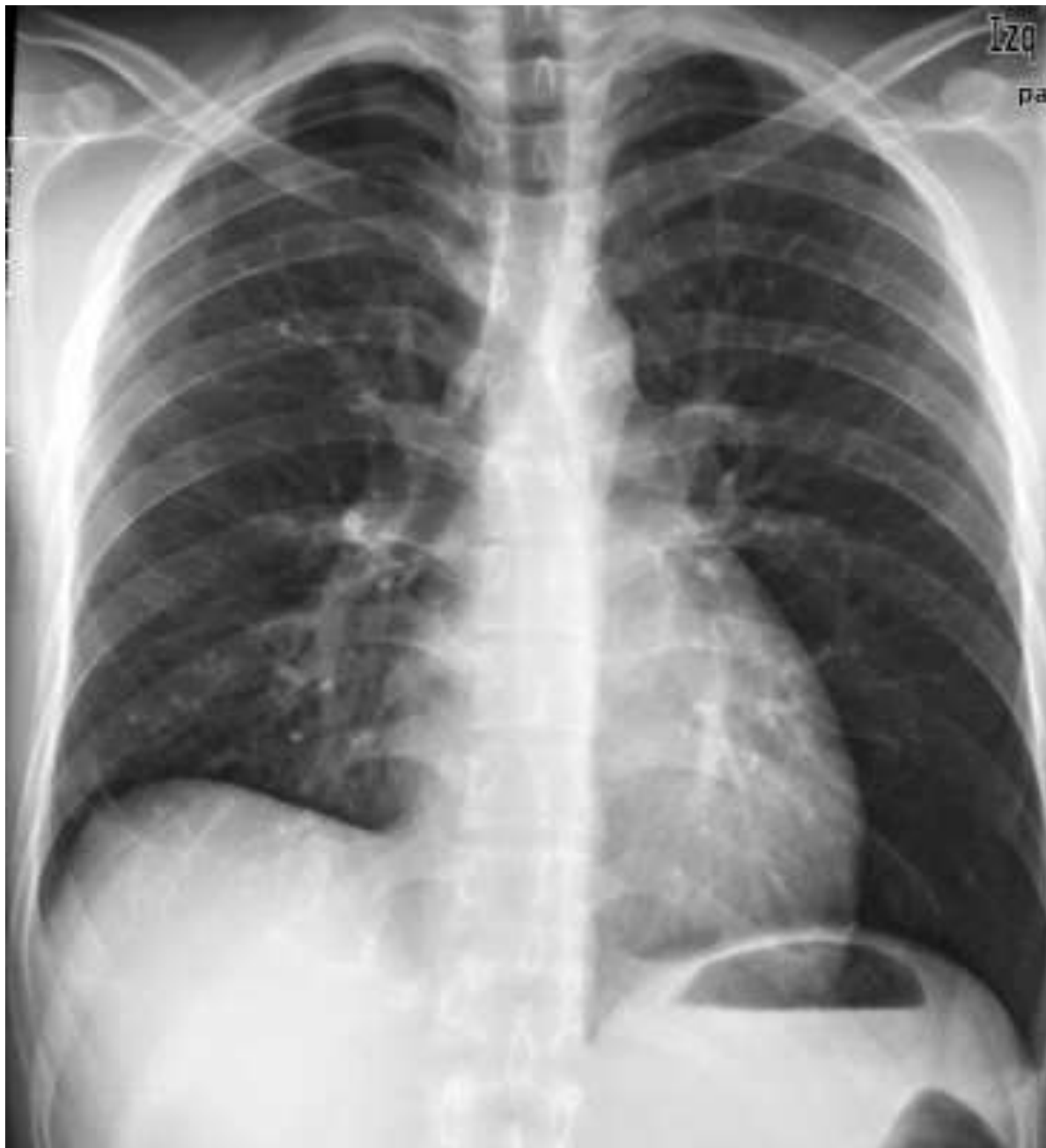

Derrame pleural izdo

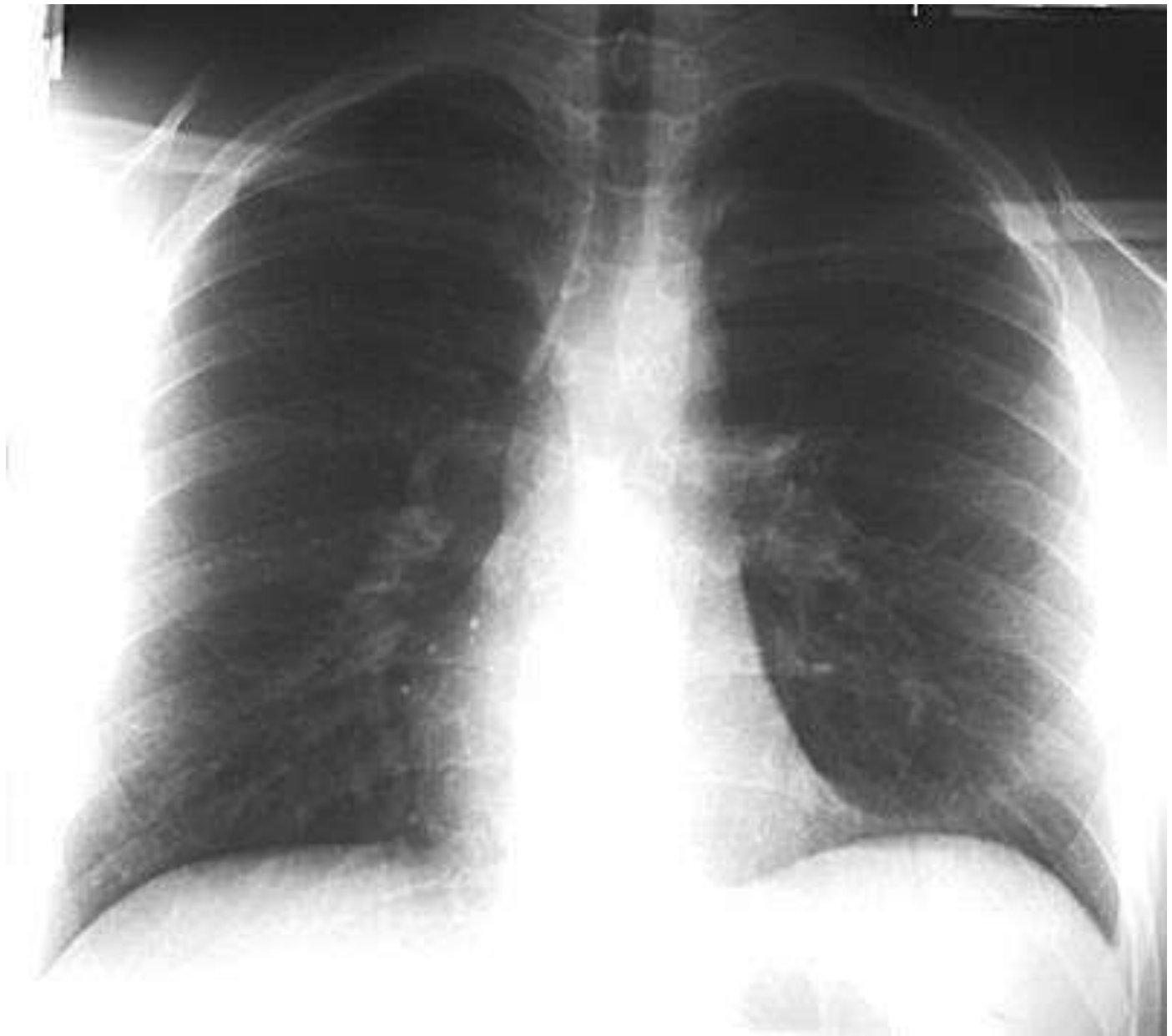



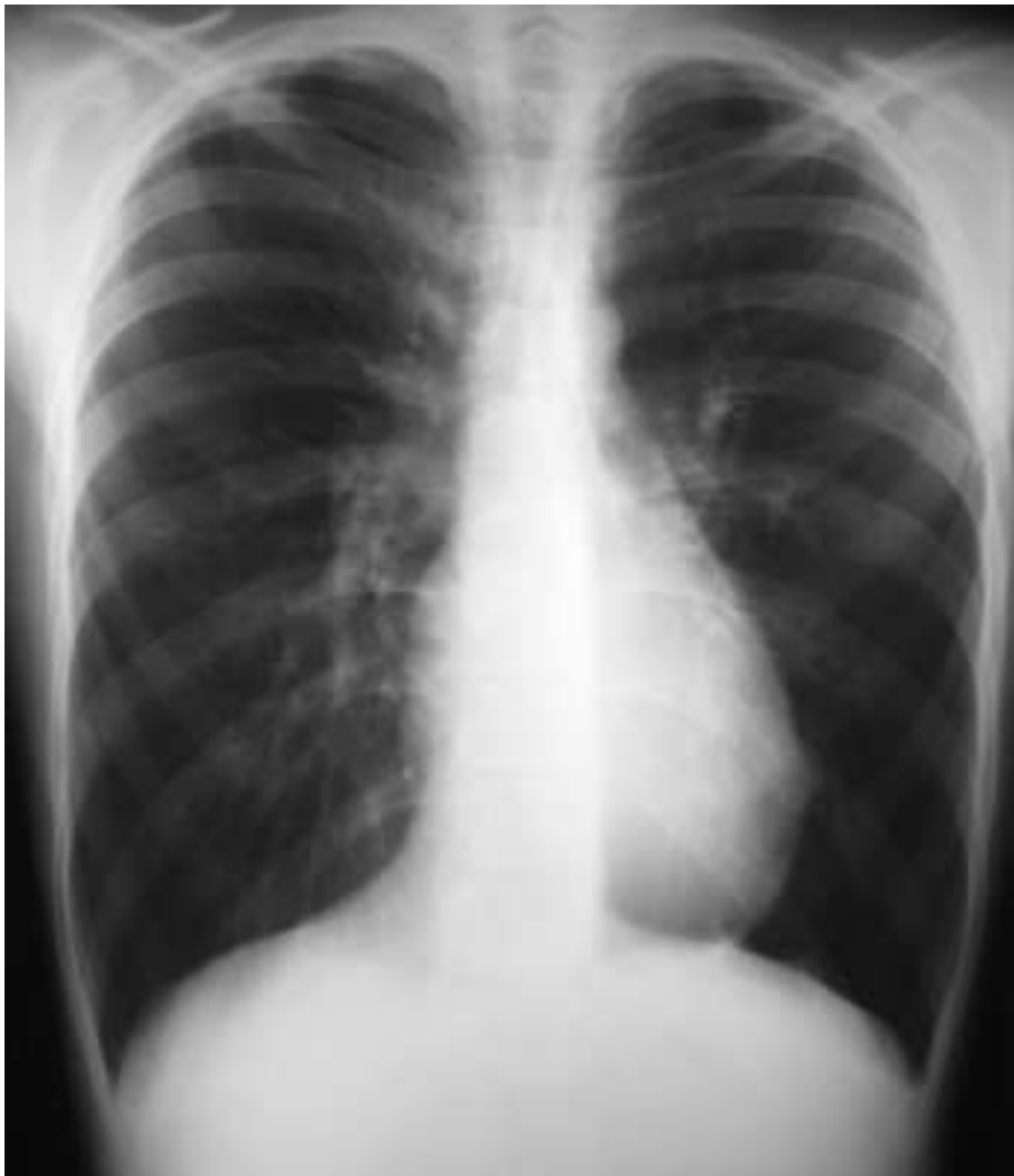Derrame lobulado



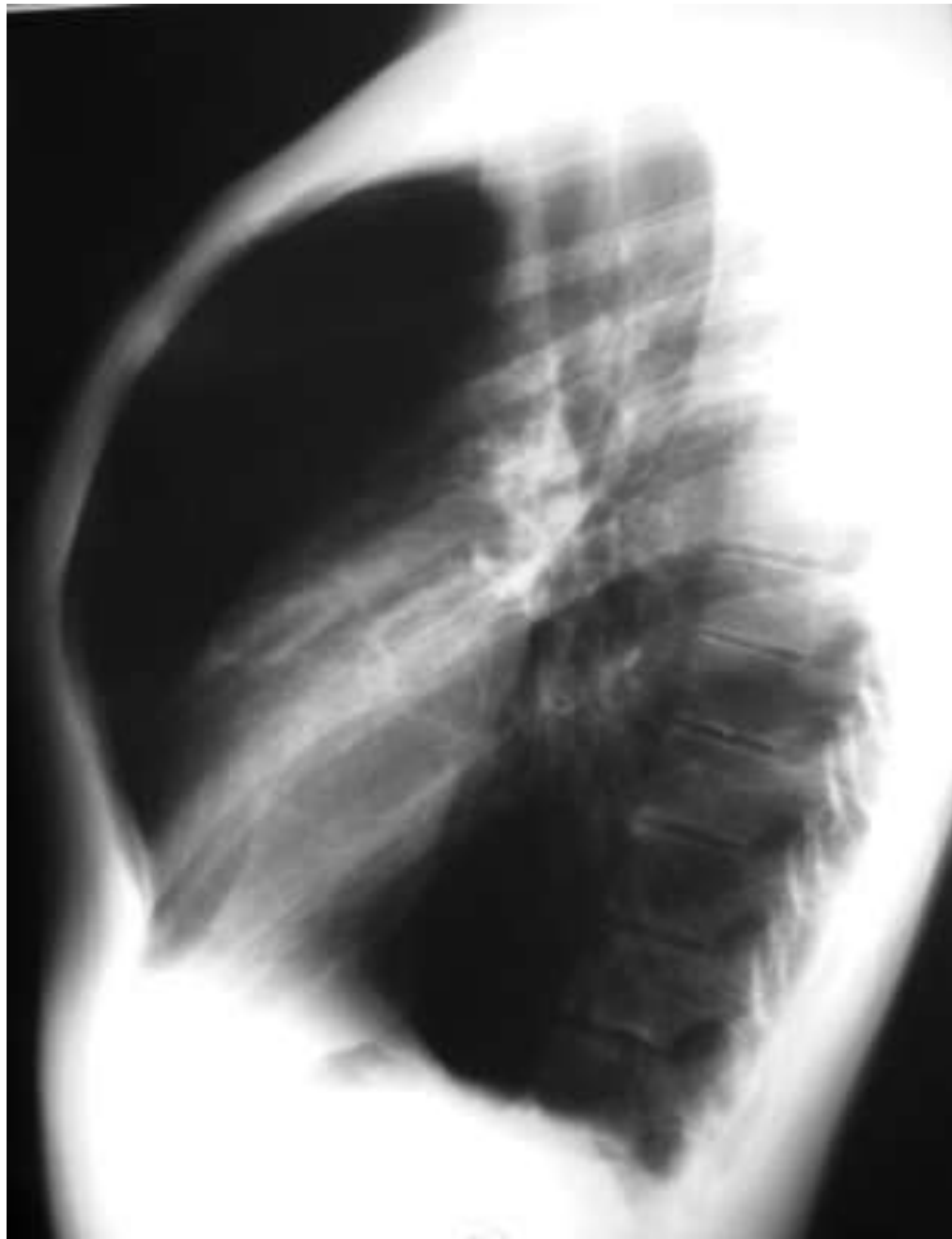
Derrame subpulmonar D

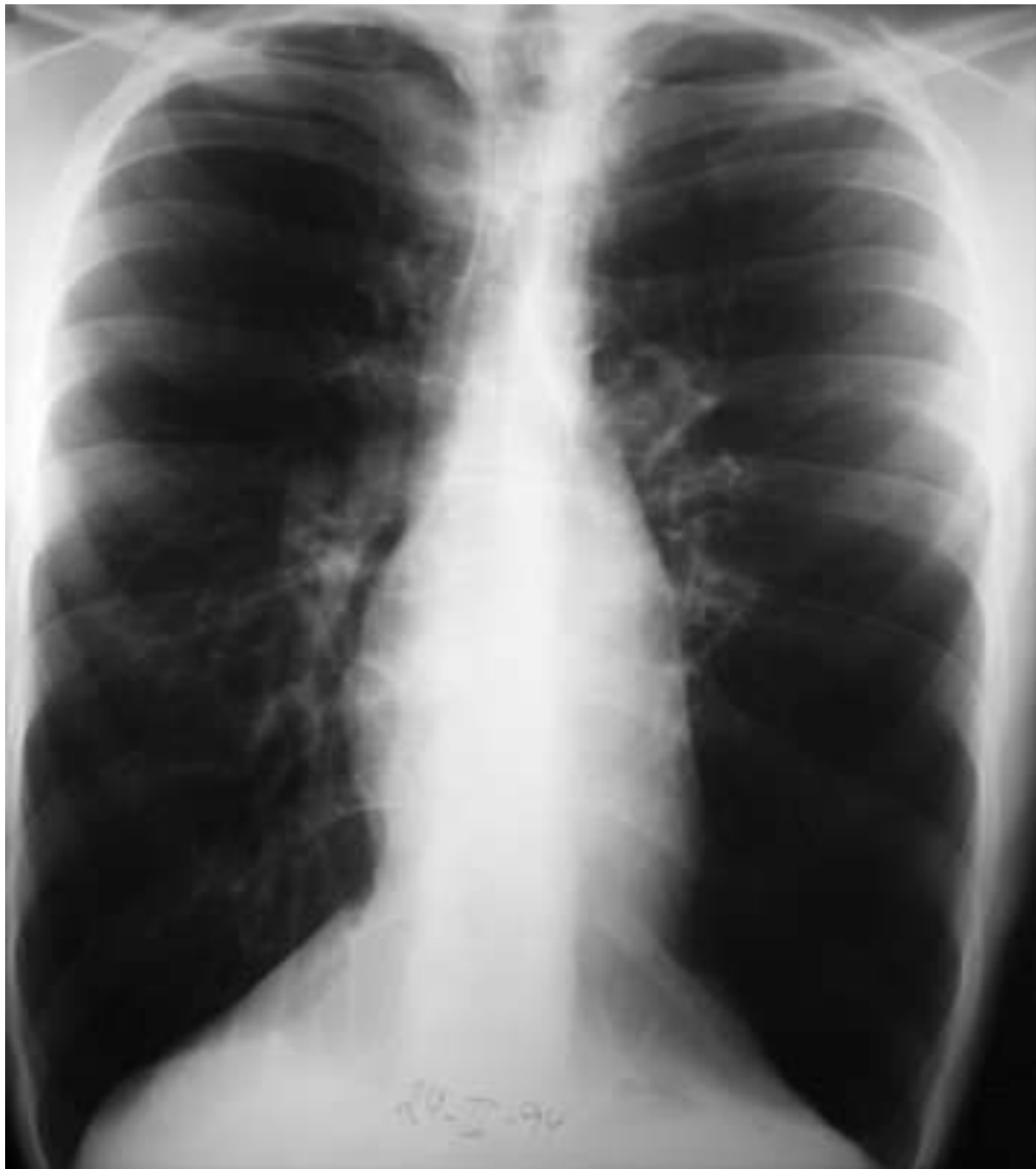

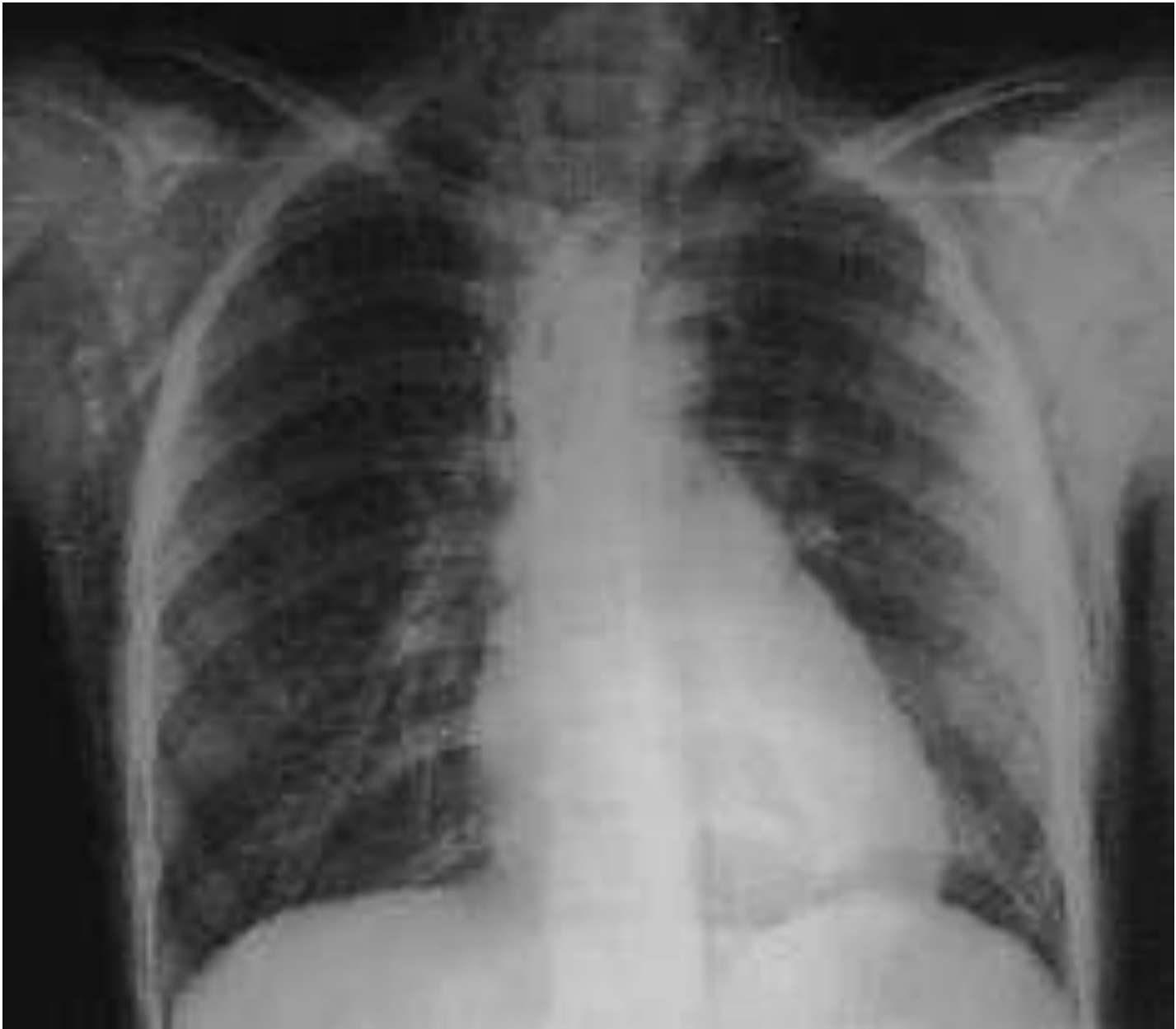Derrame subpulmonar Izdo



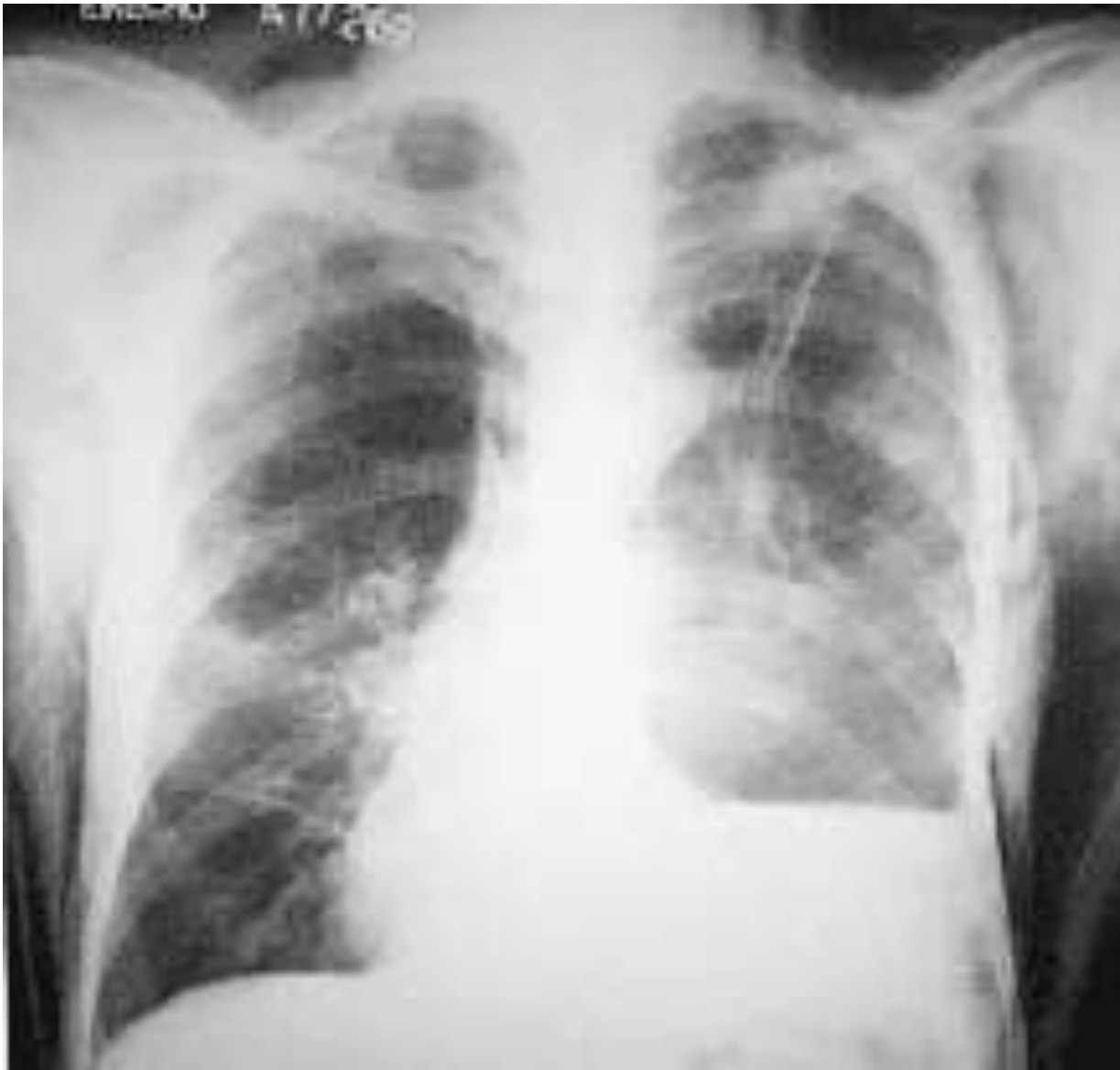enfisema



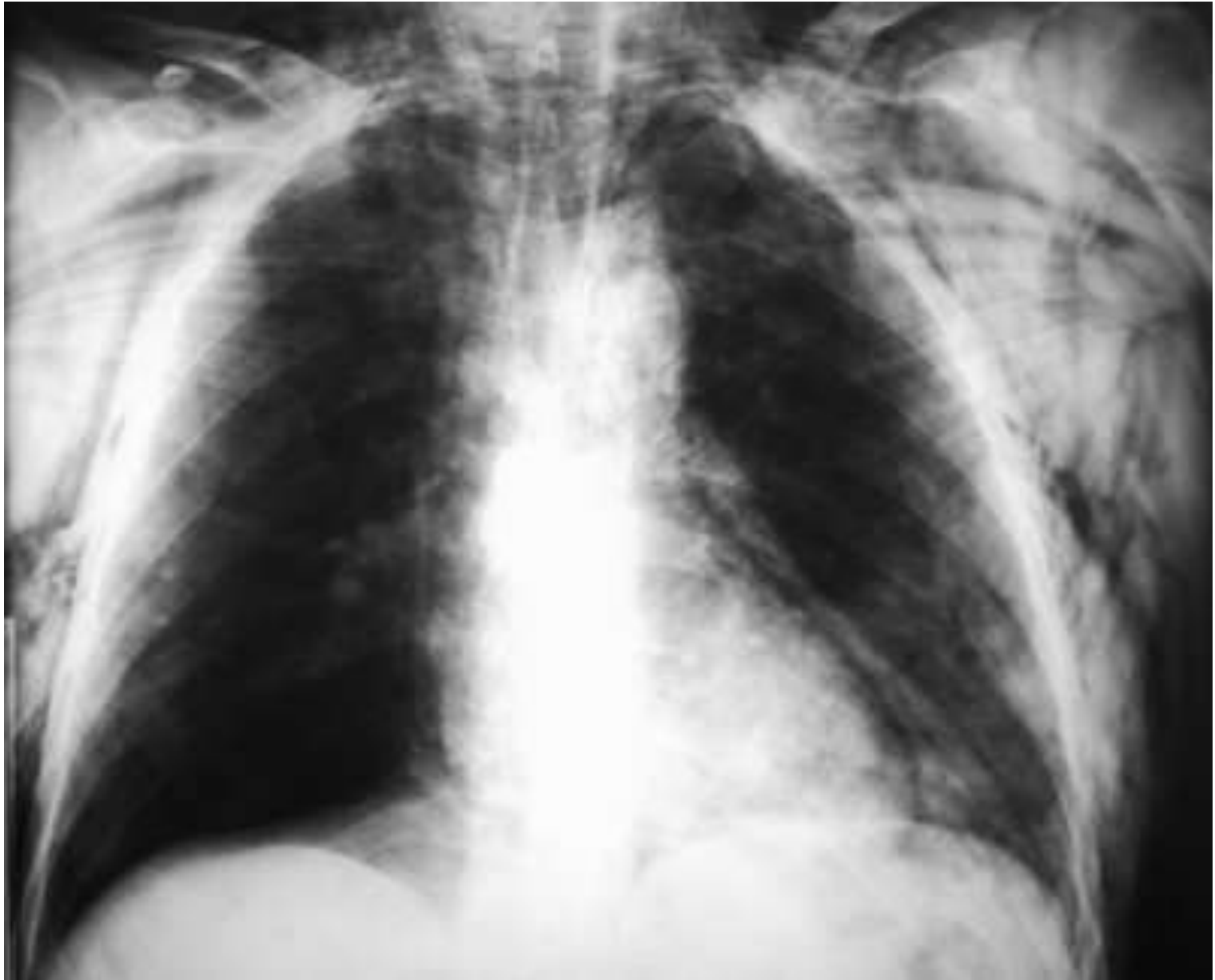



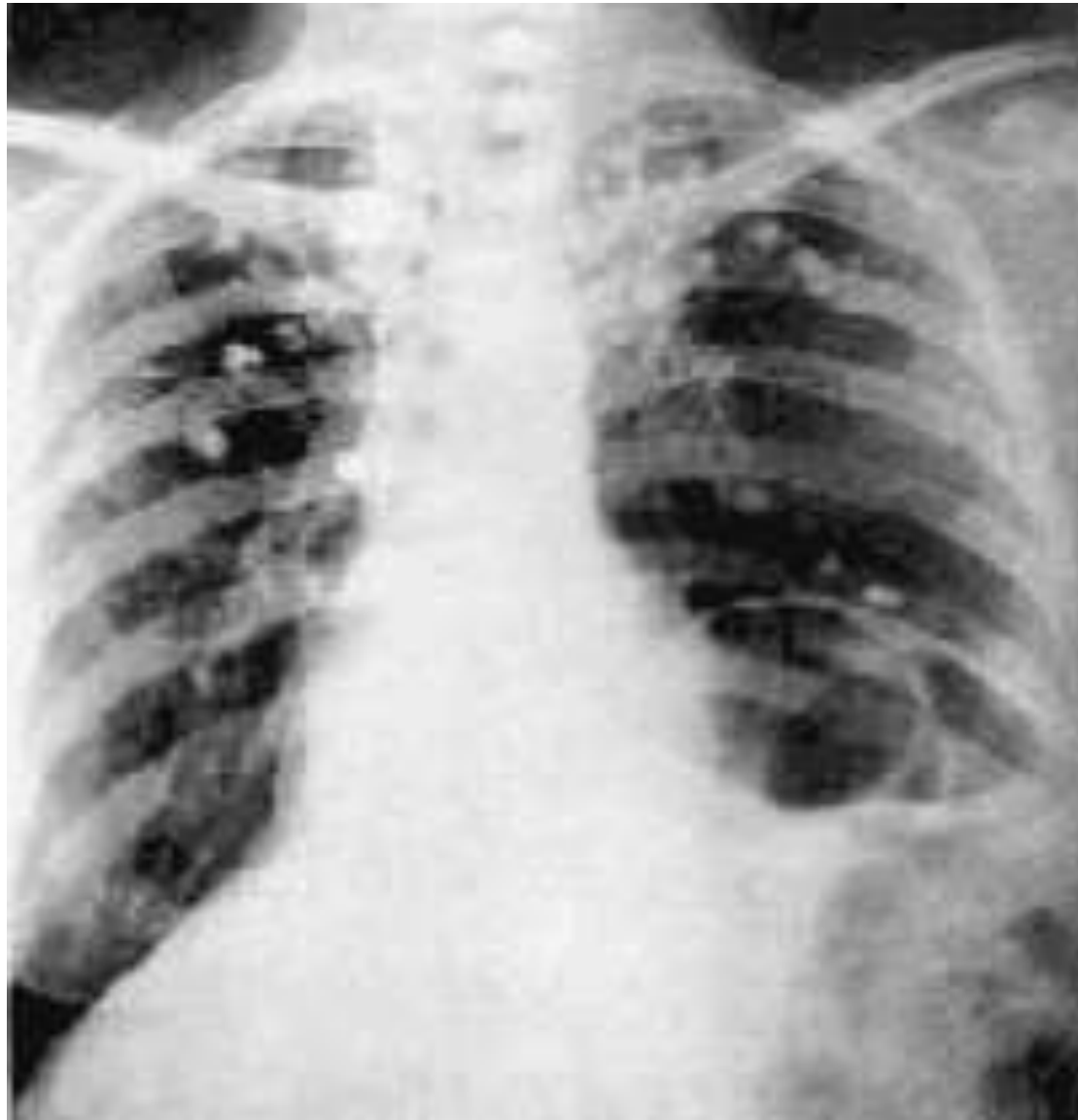Enfisema mediastínico y subcutáneo



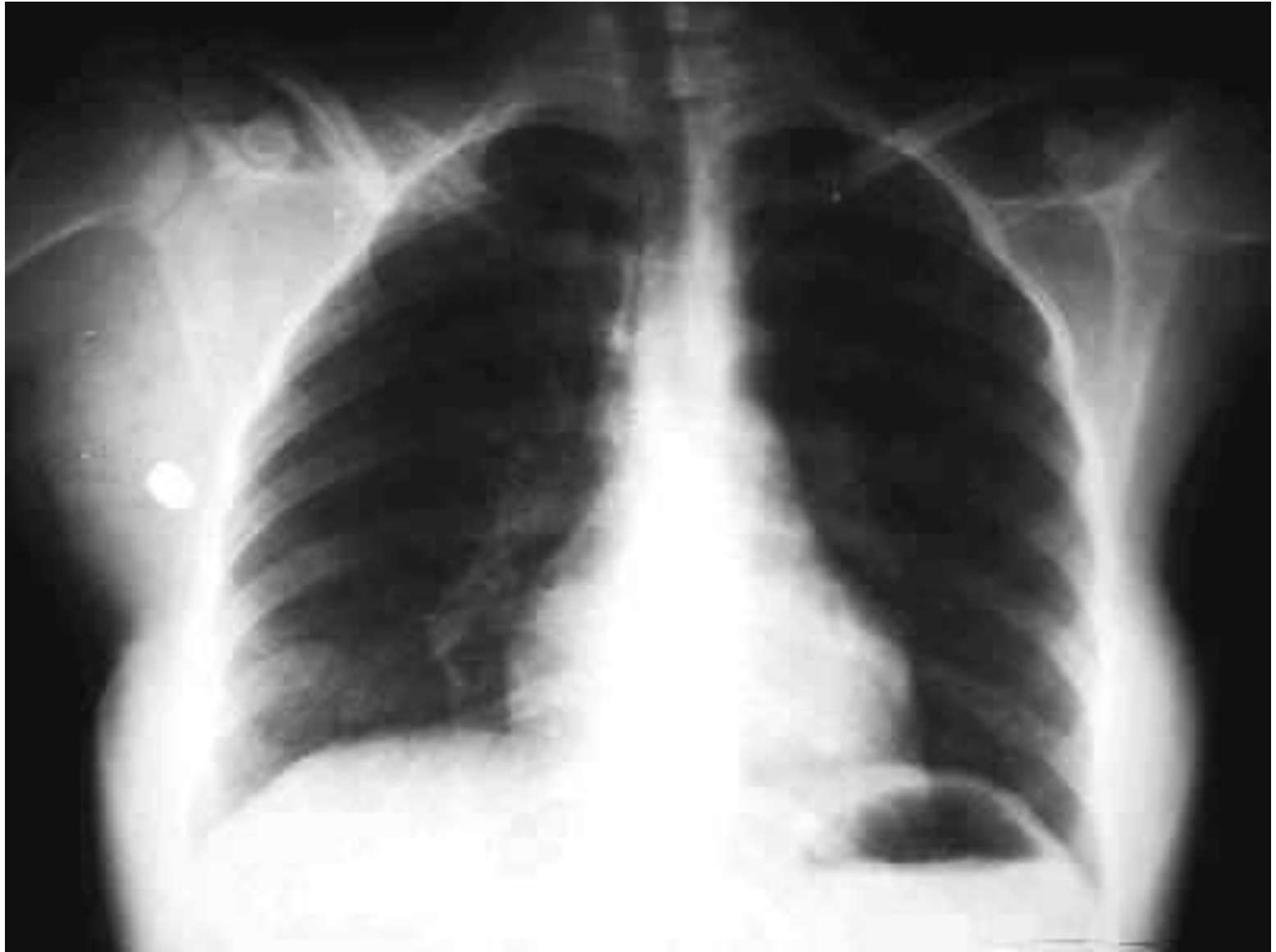Enfisema subcutáneo y hemotórax



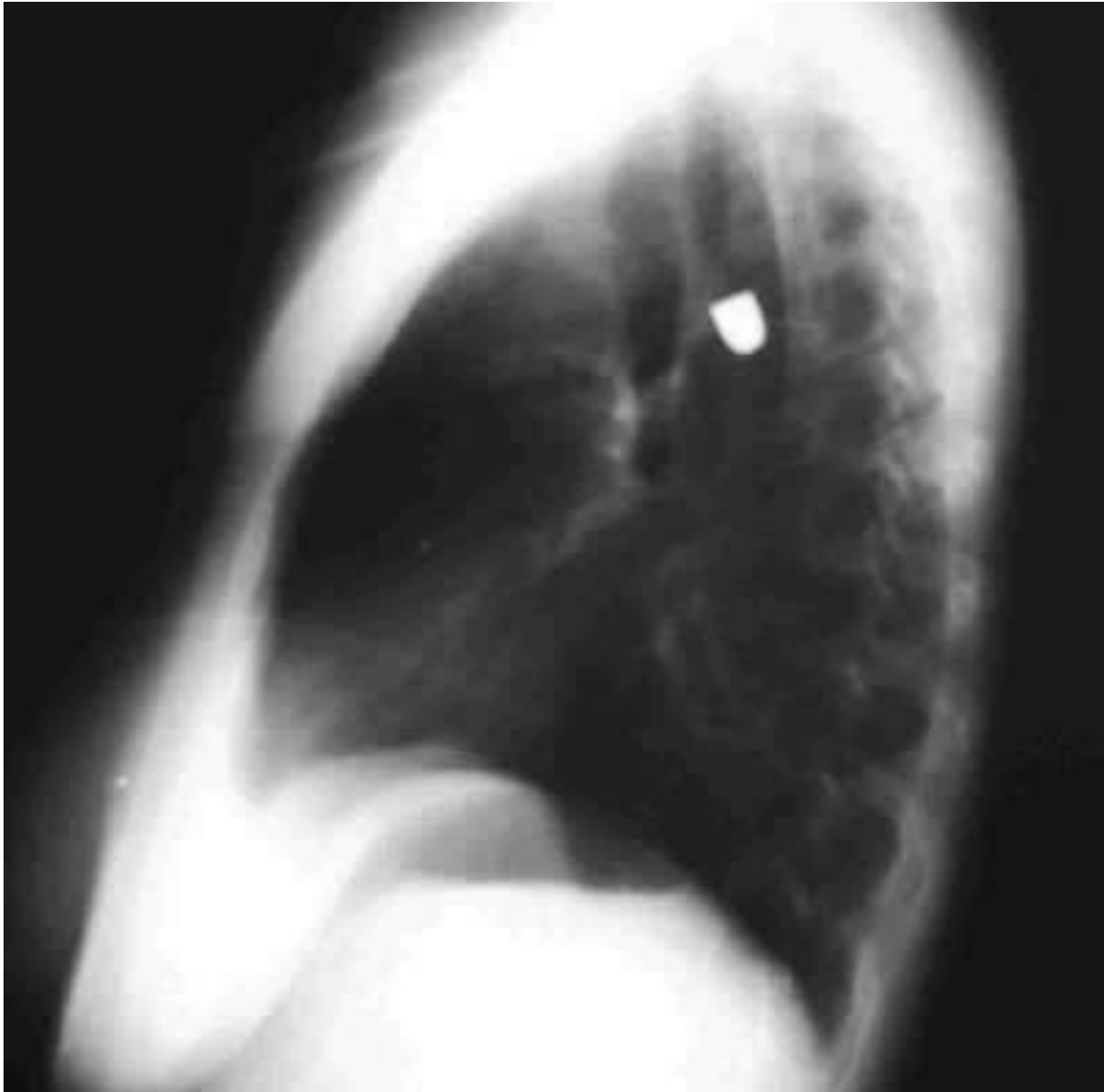
Enfisema subcutáneo

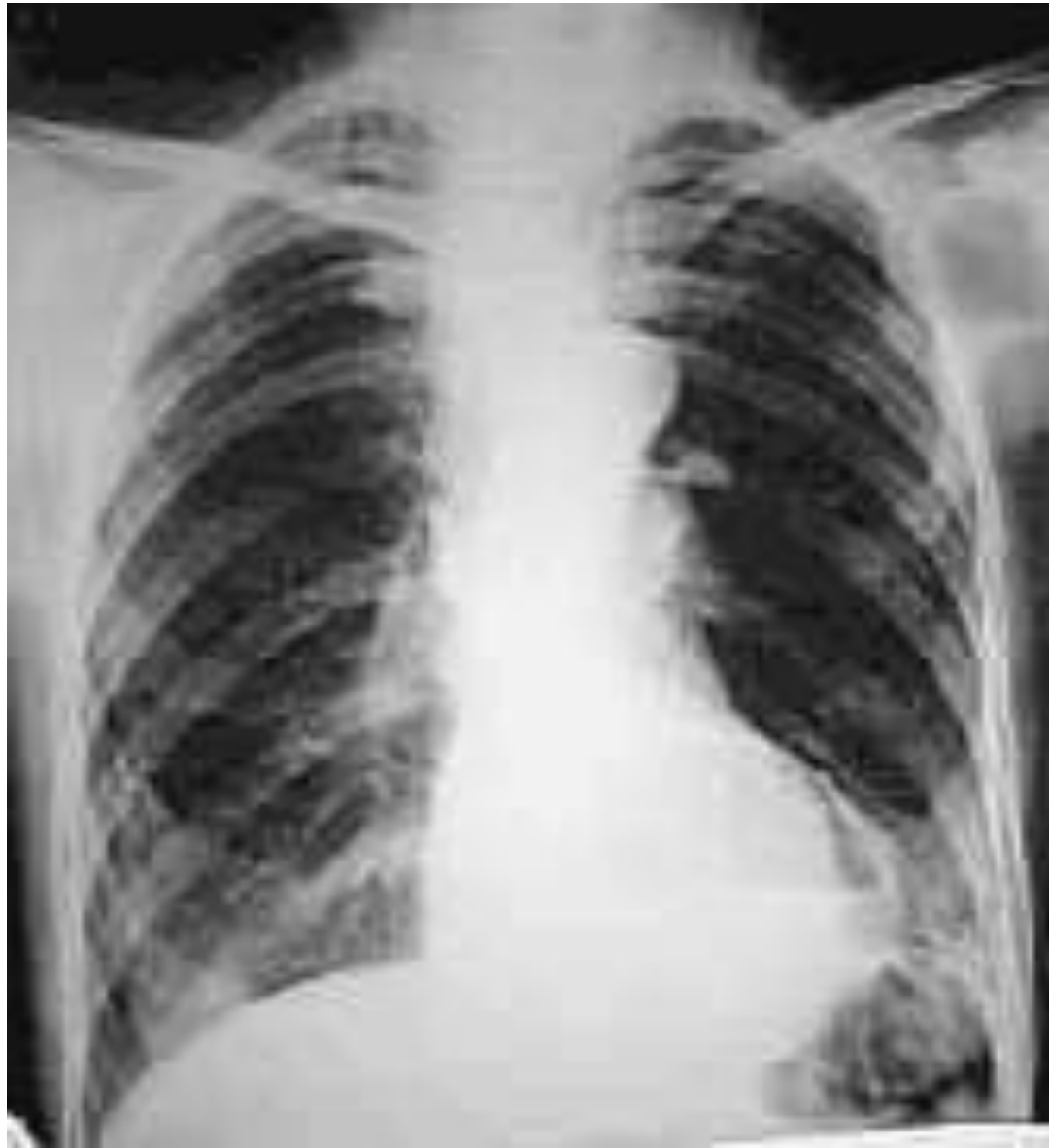

Eventración diafragma izdo

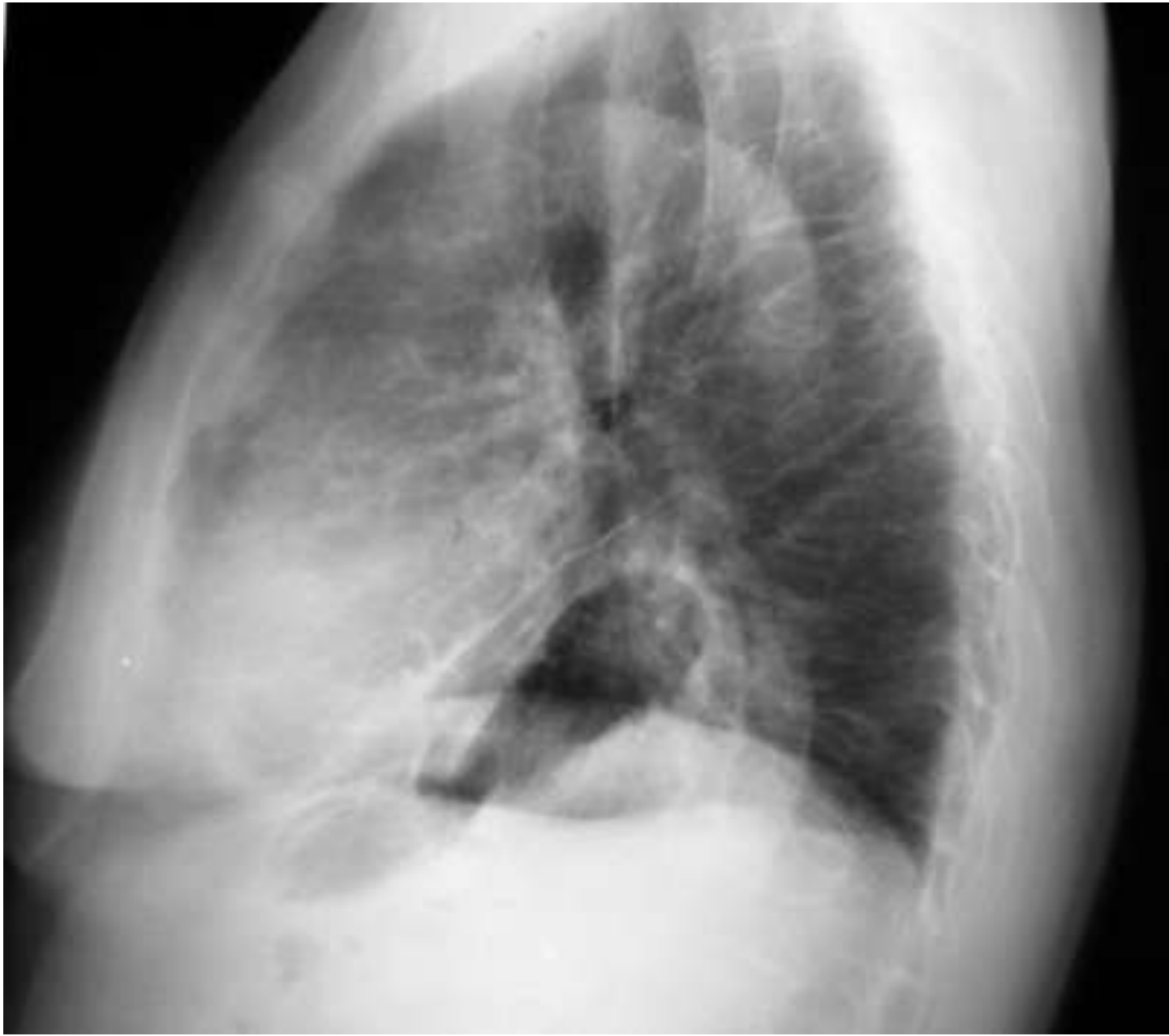

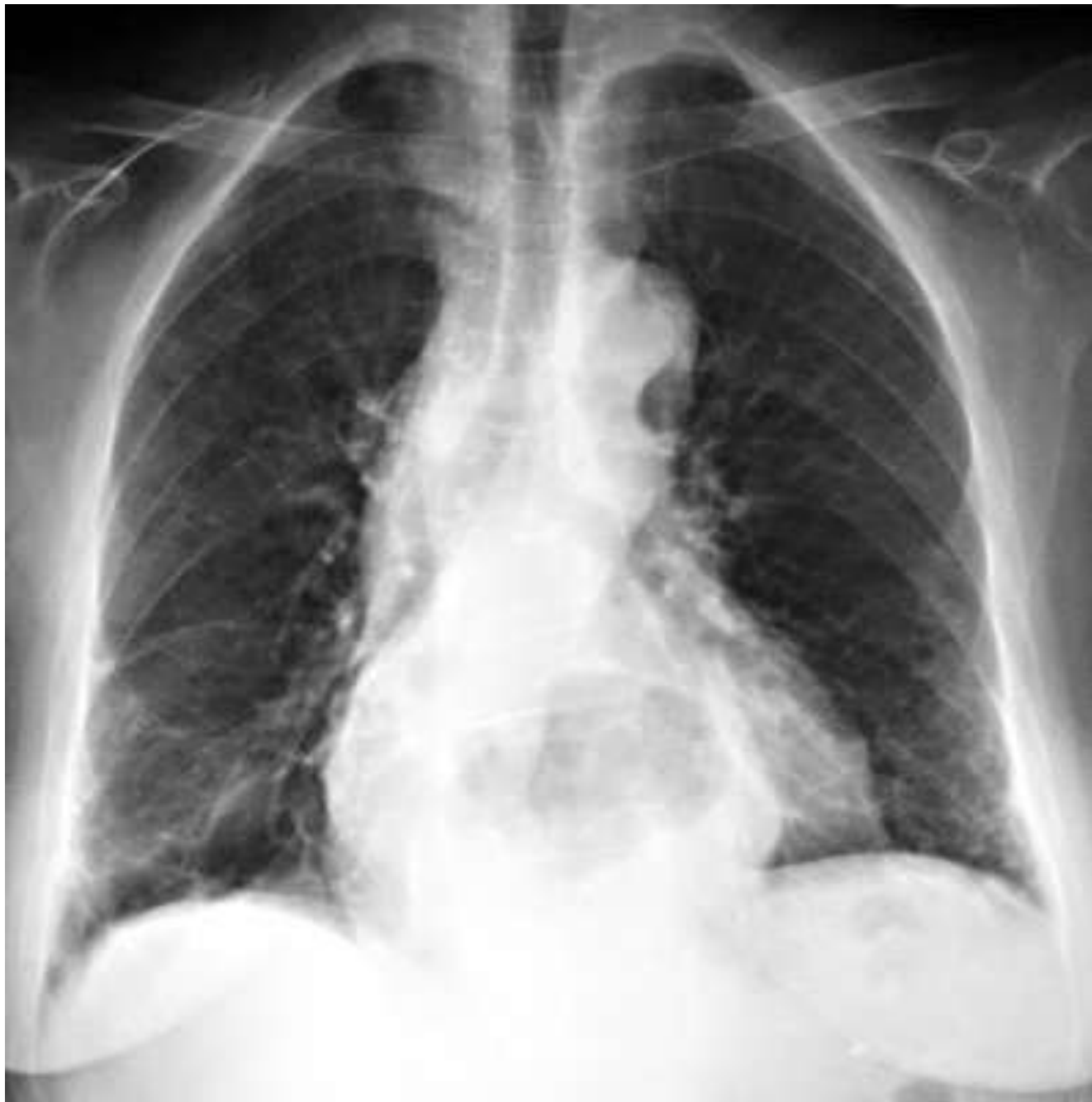Fractura clavícula y bala en partes blandas

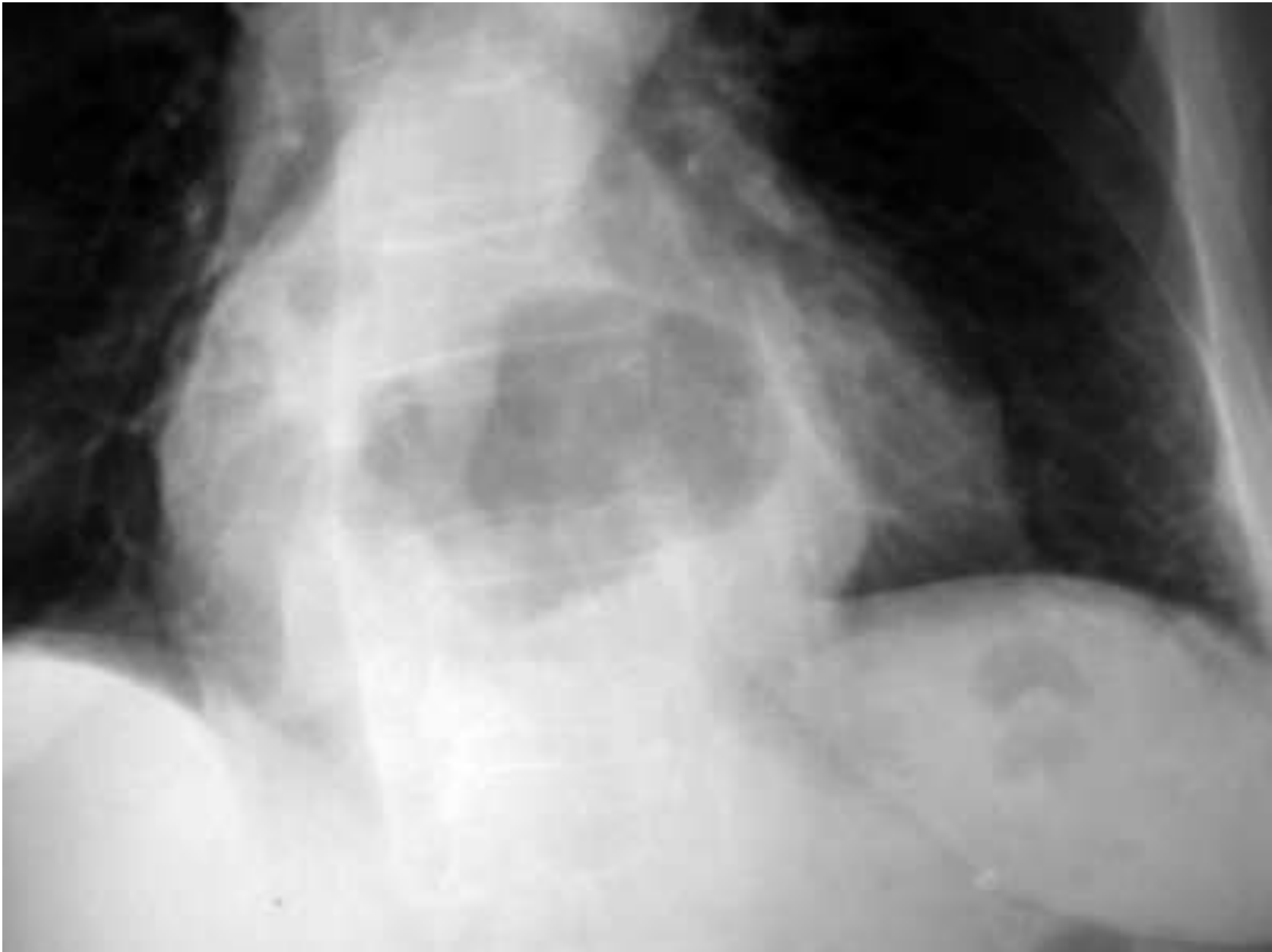


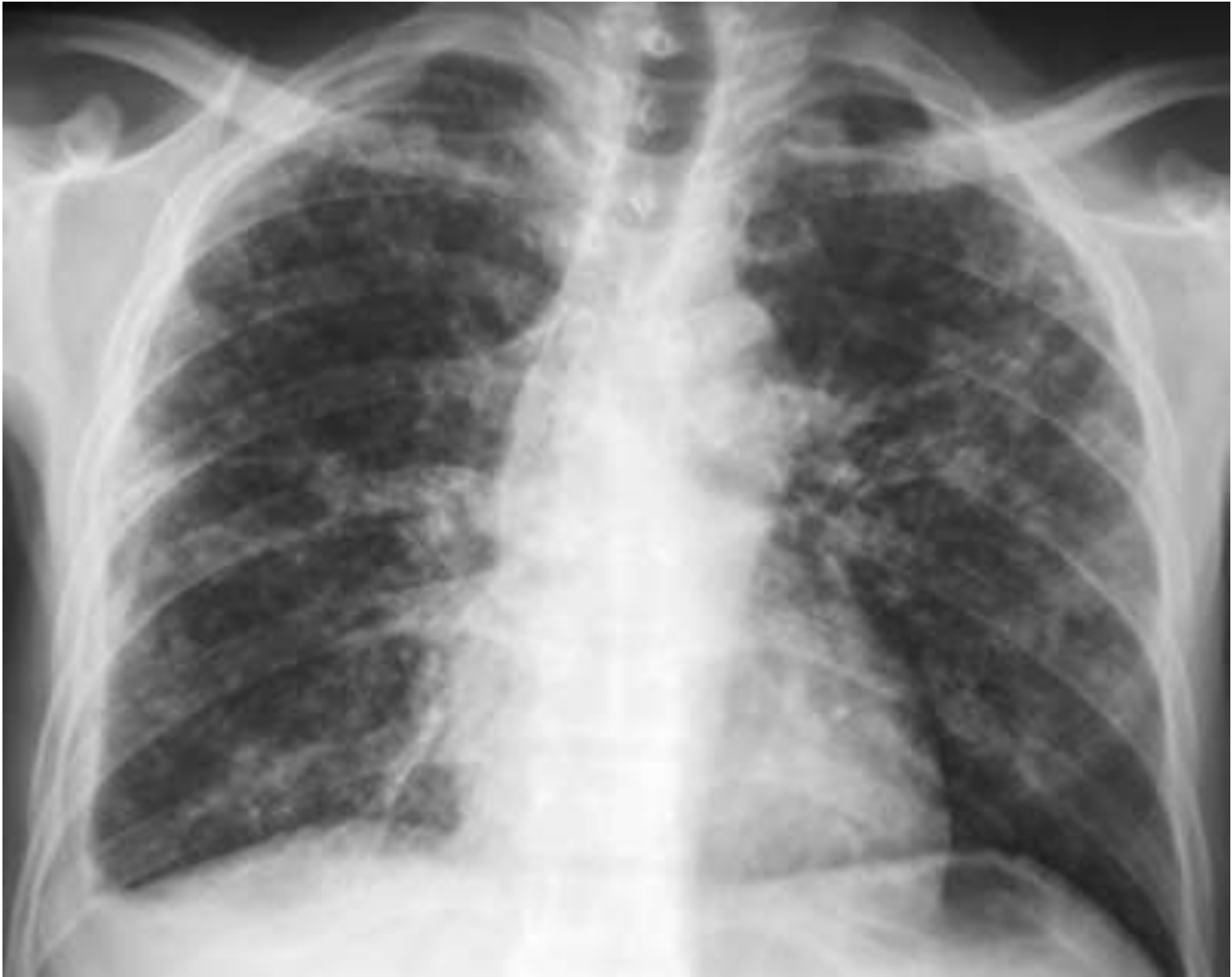
Hernia de hiato

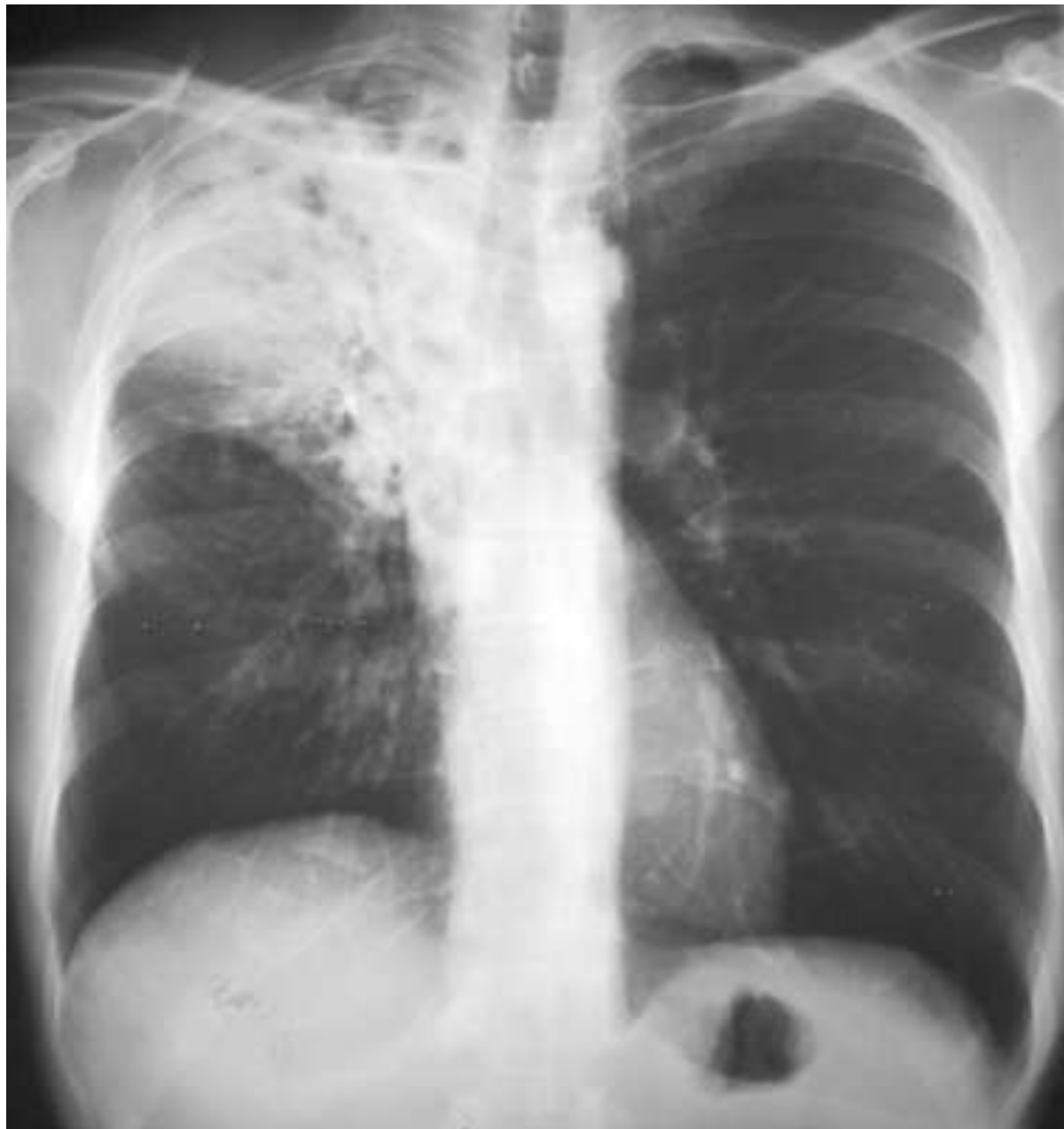




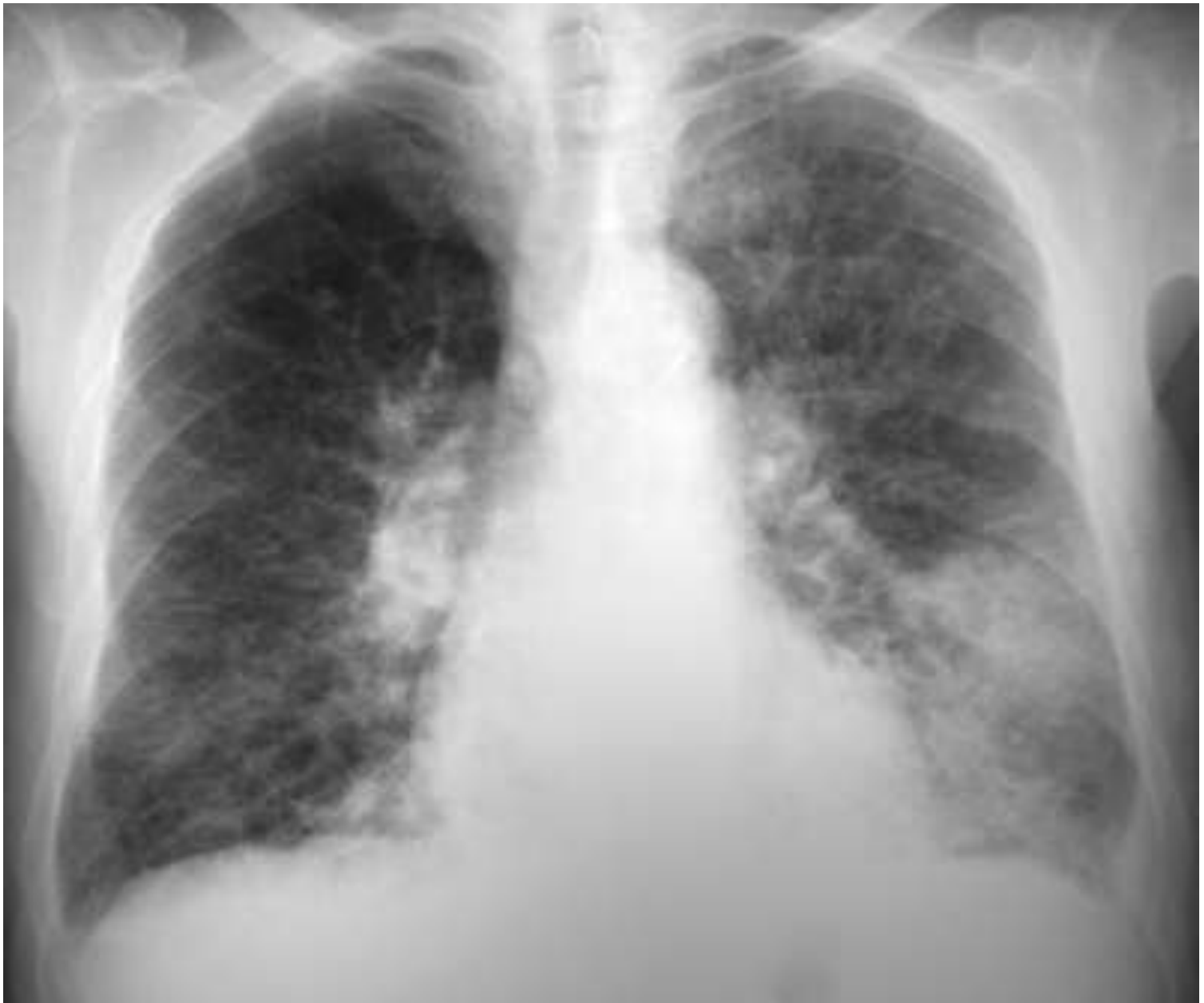


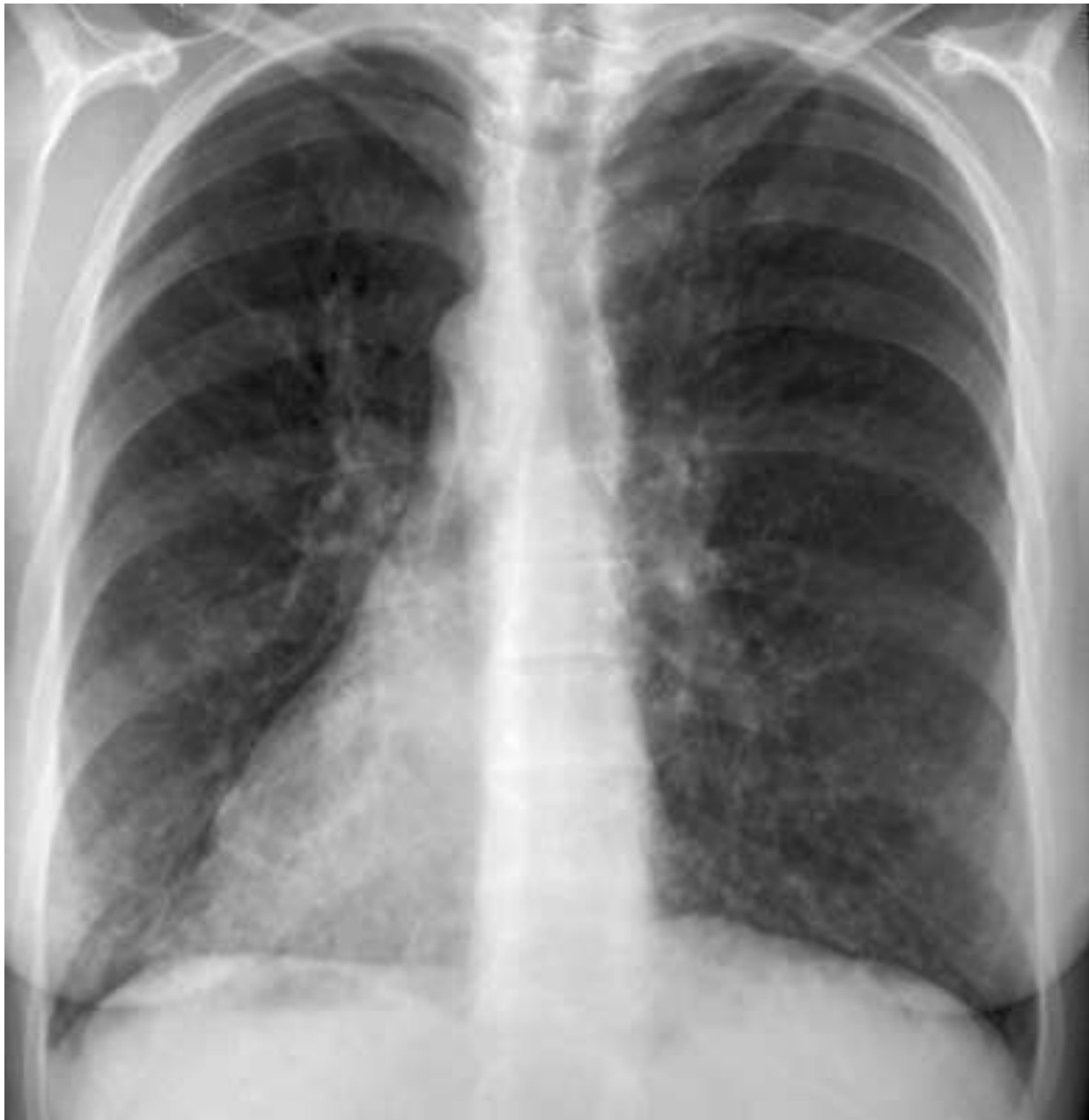Infiltrado alveolar bilateral (TB)



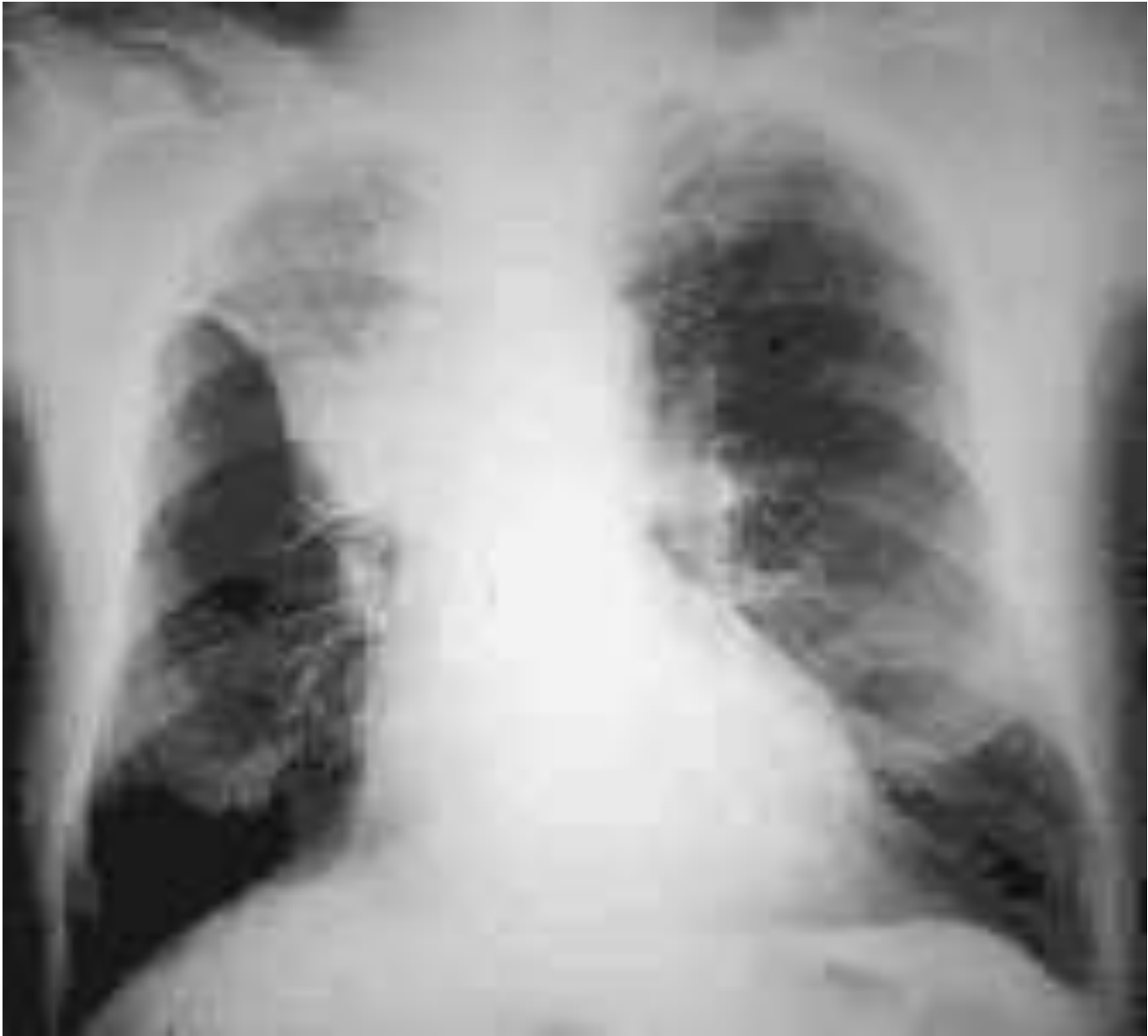Infiltrado alveolar LSD (TB)



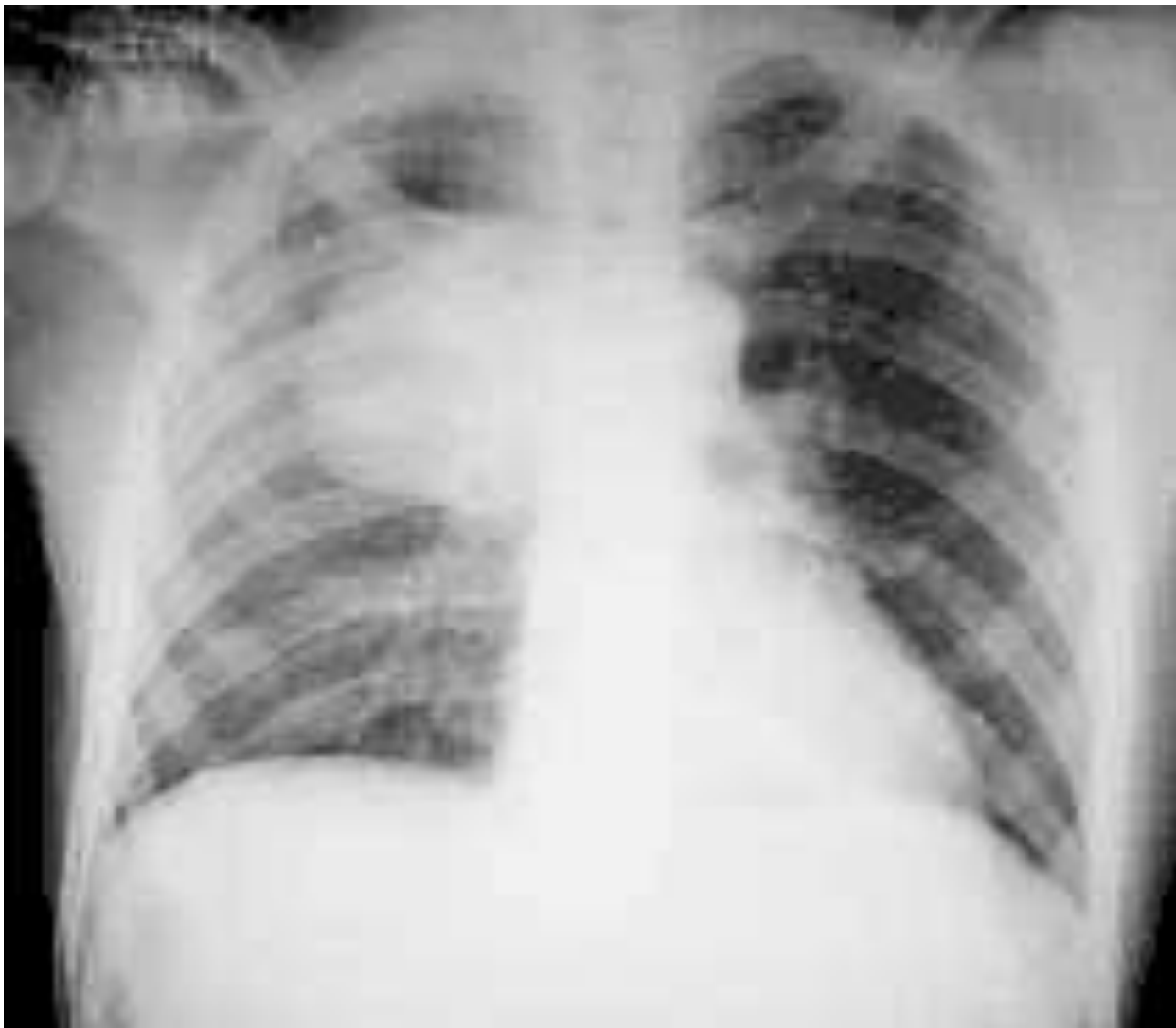Insuficiencia cardiaca

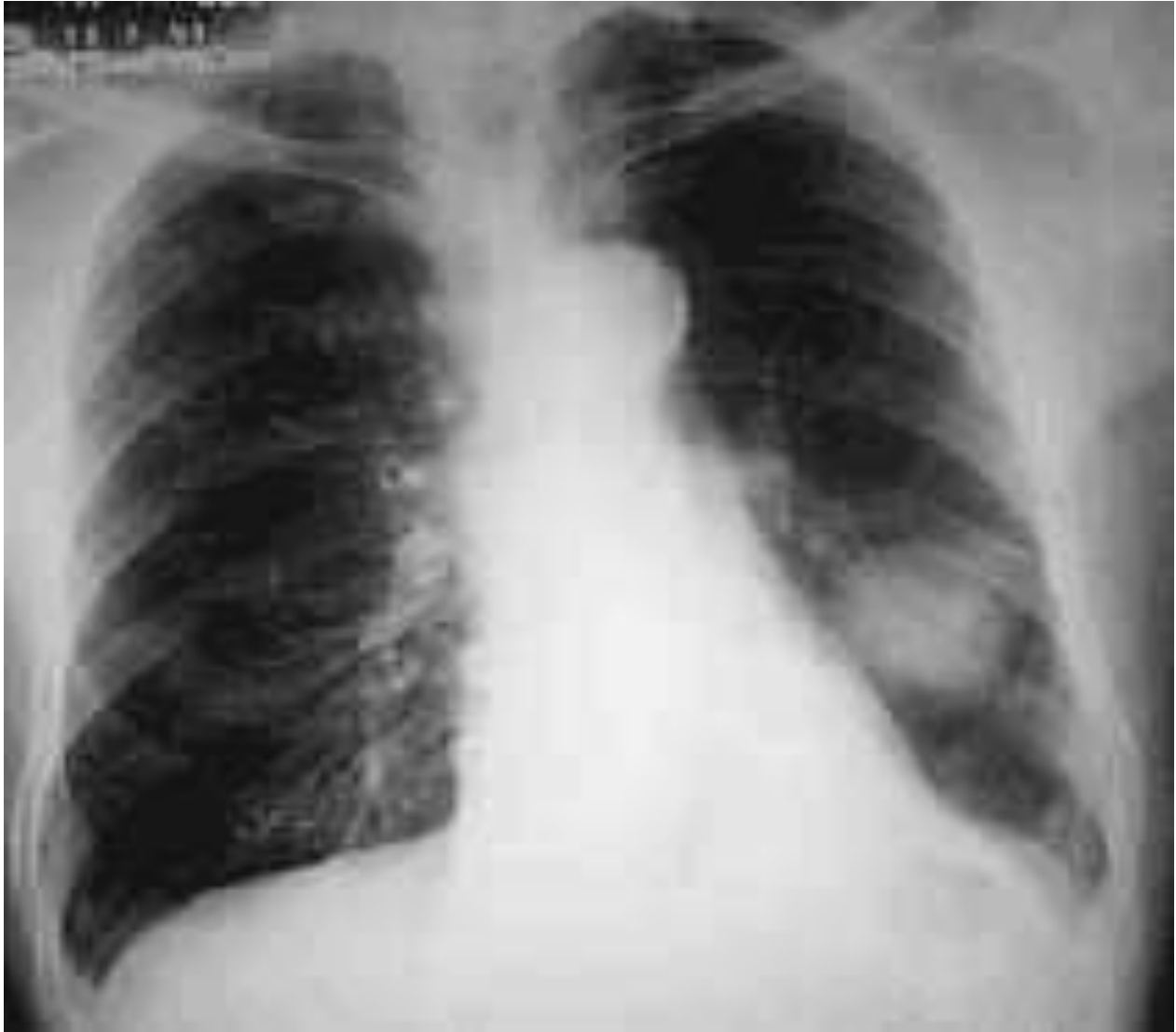

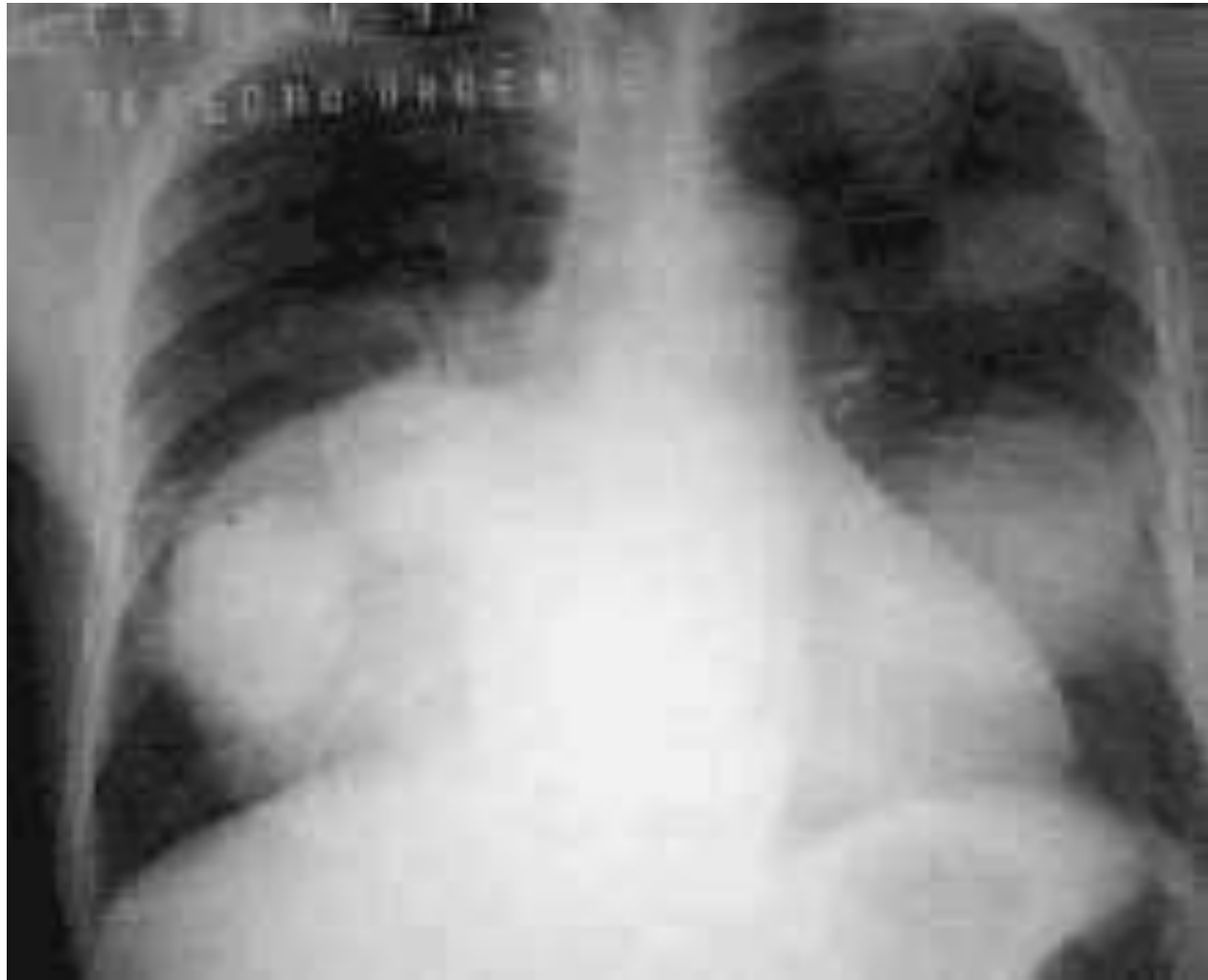S. Kartagener (situs inversus)

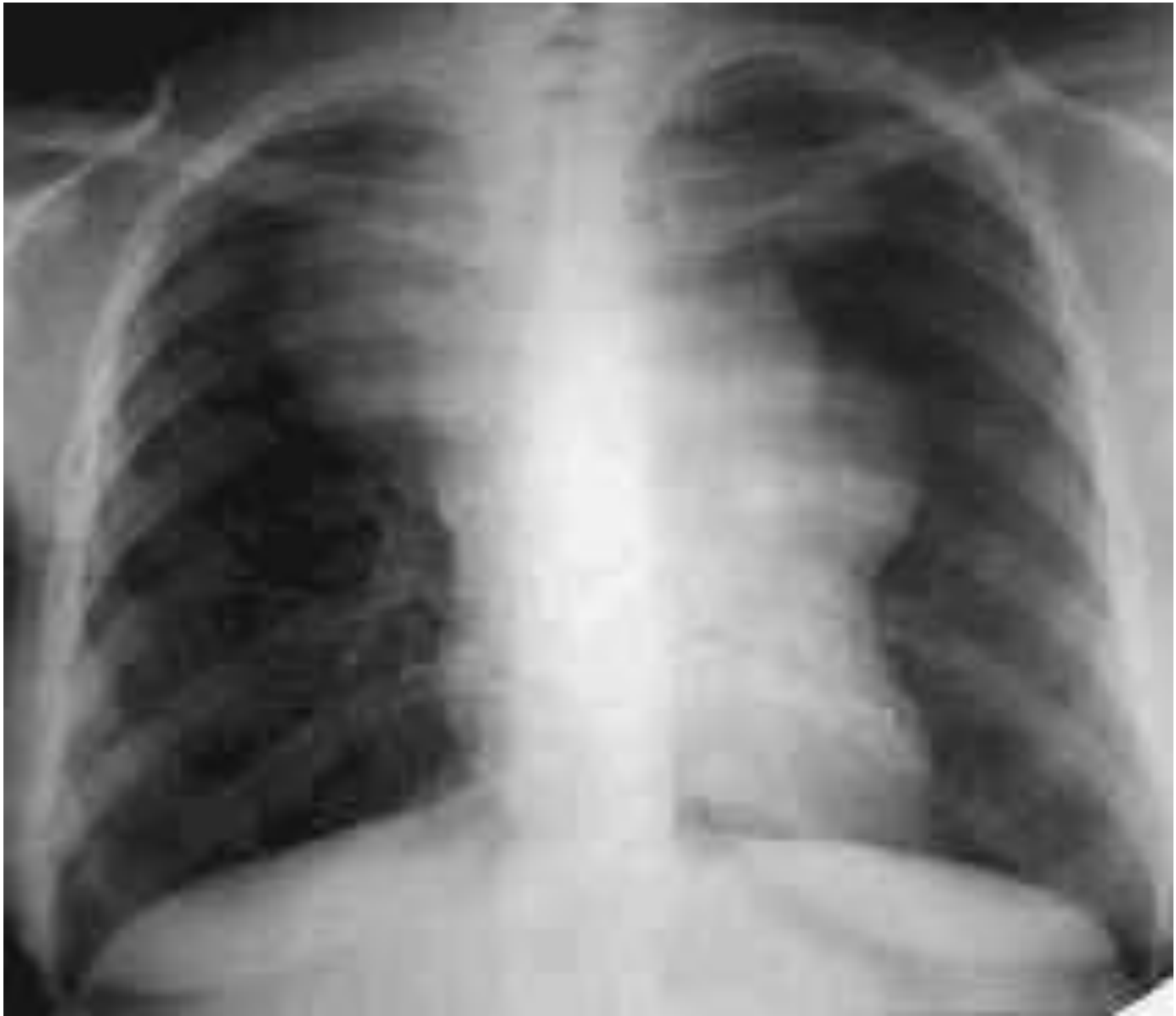

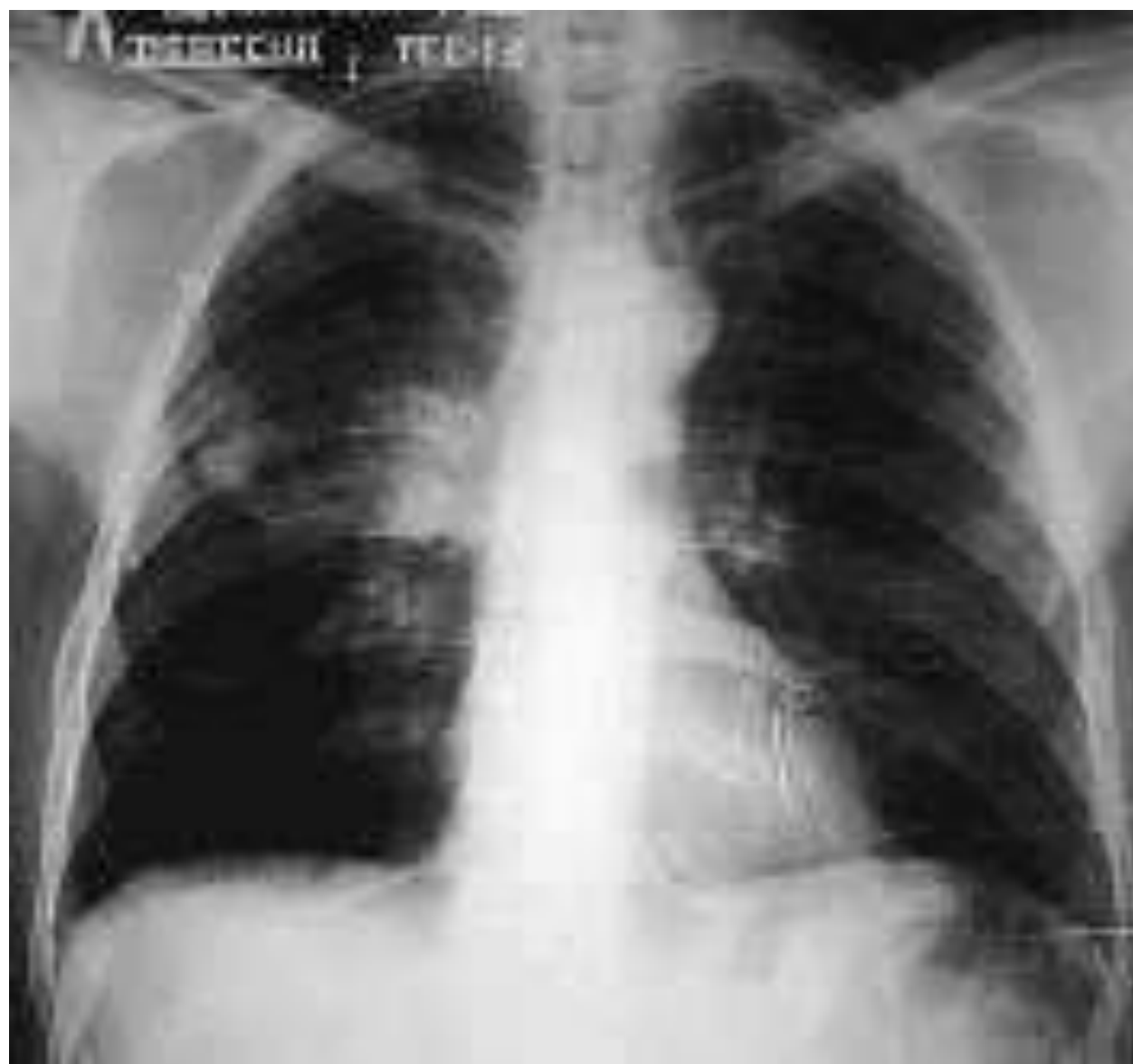Masa LSD

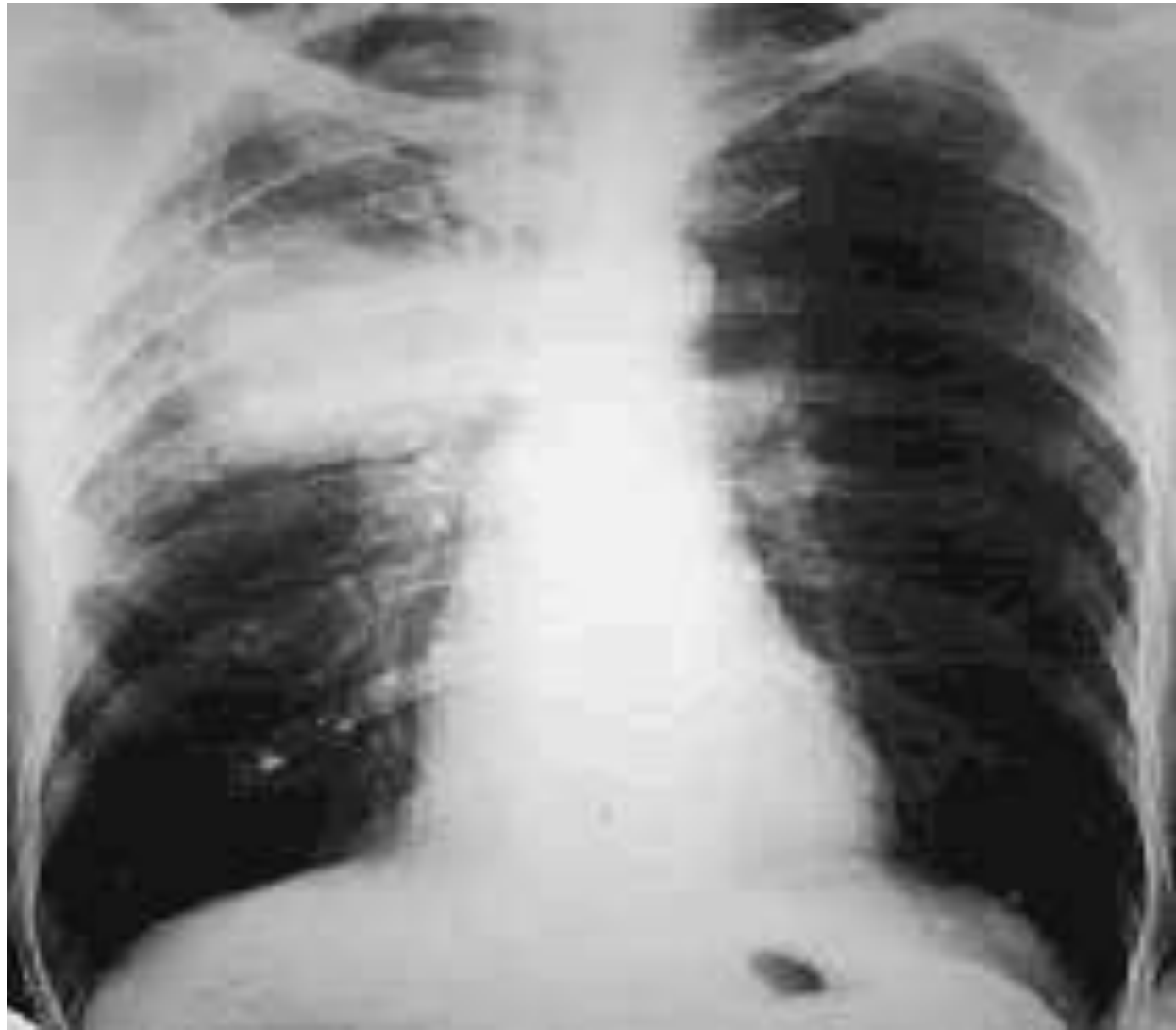

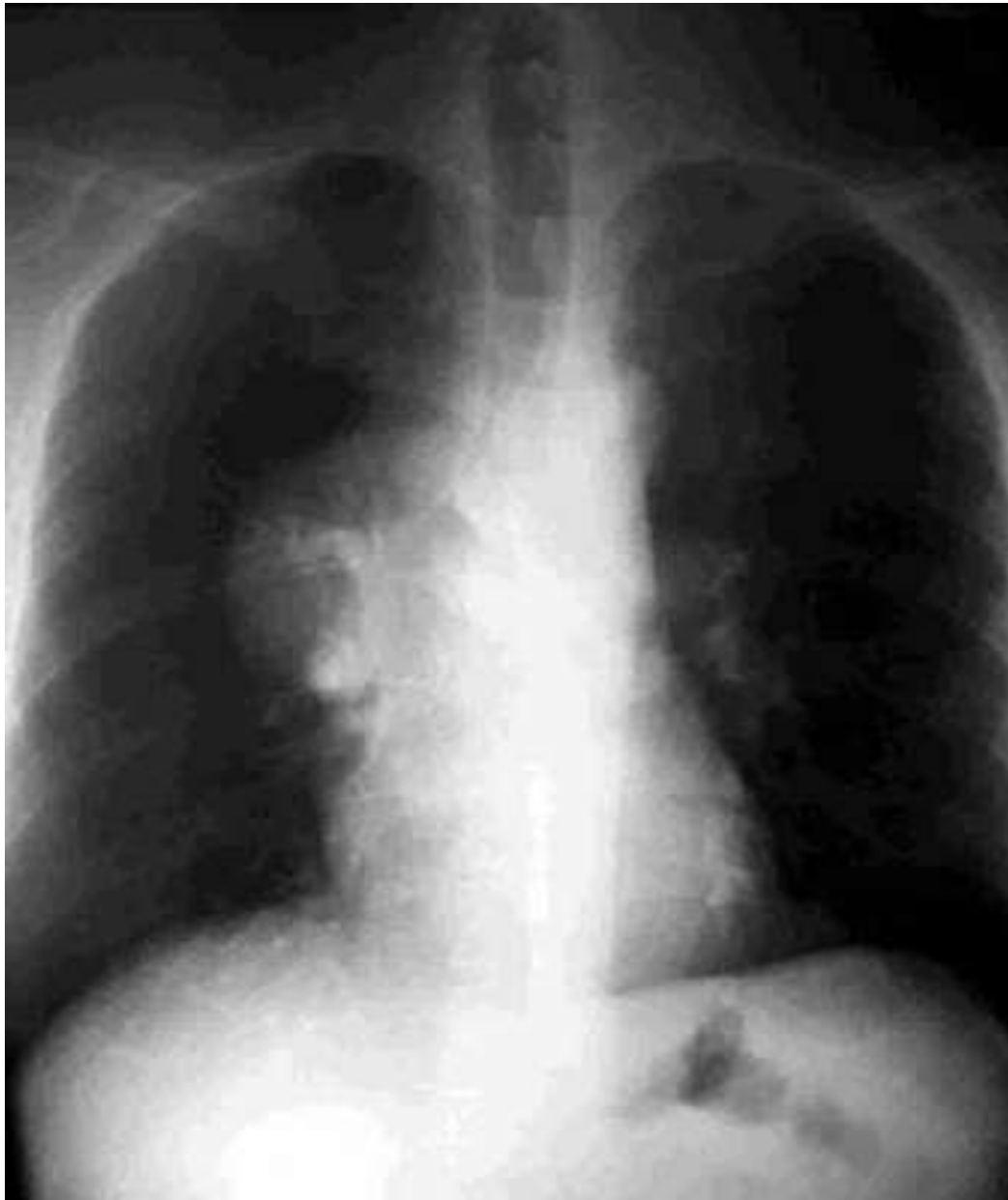





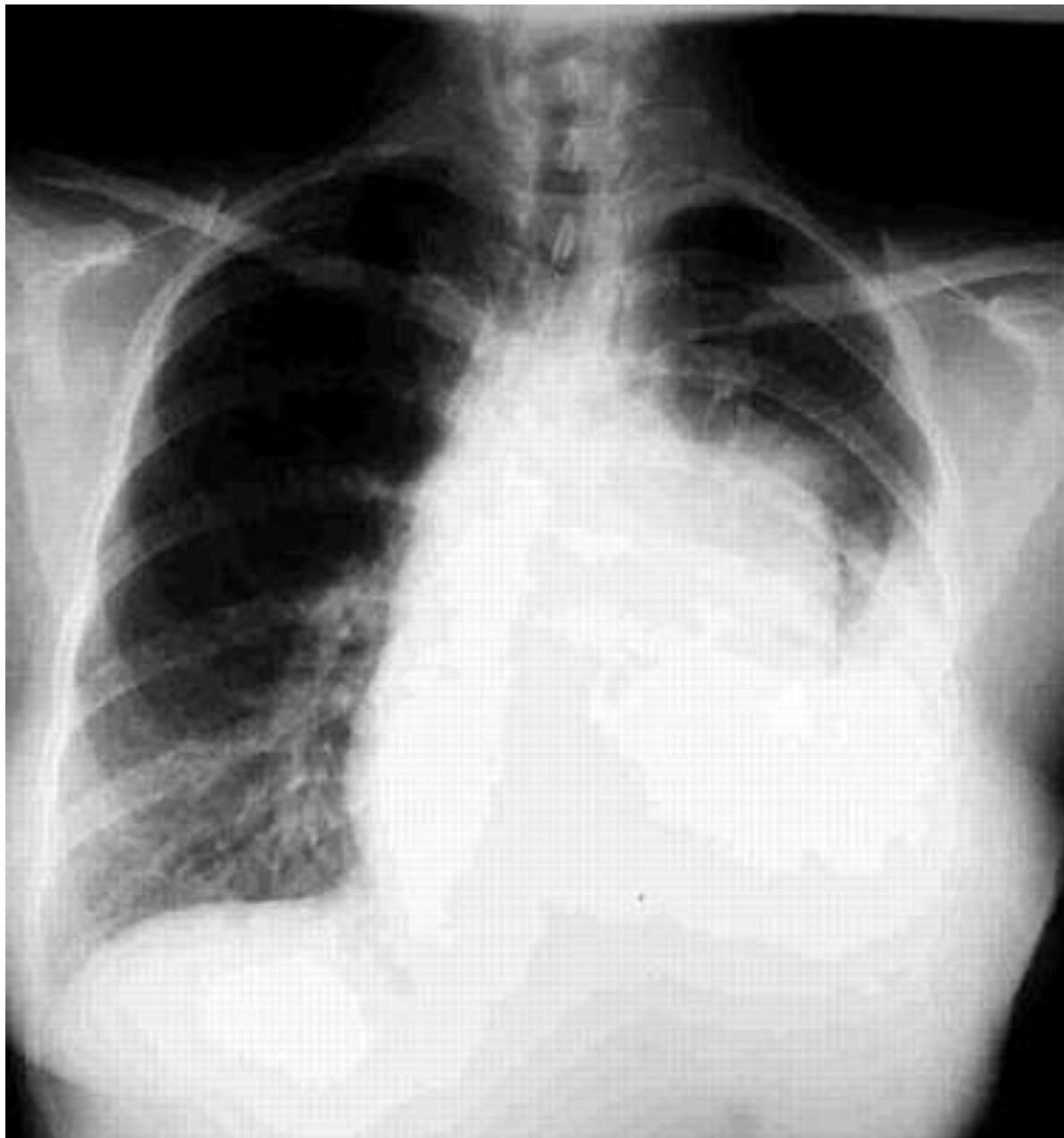




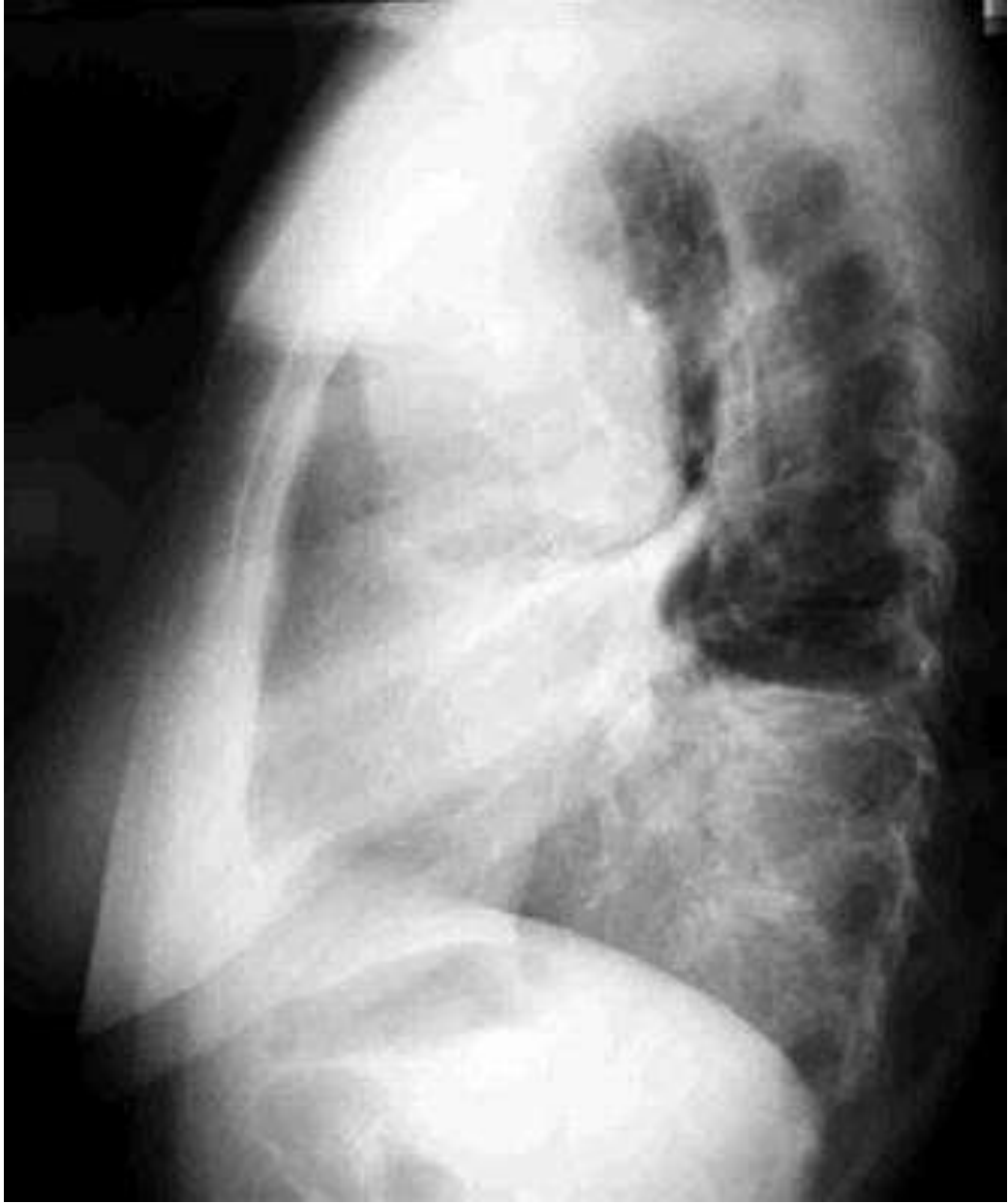

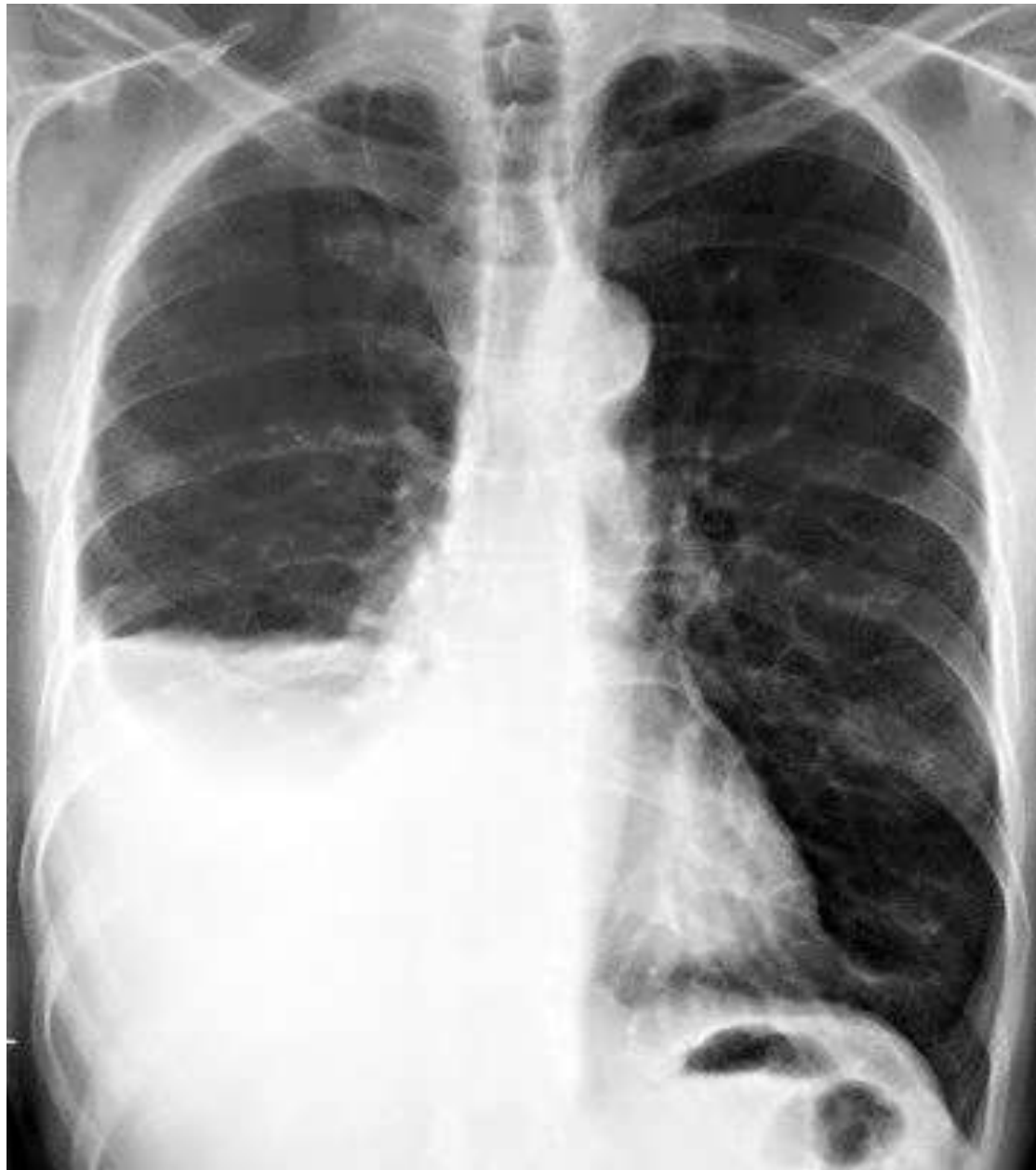Masa mediastino (linfoma cel B)

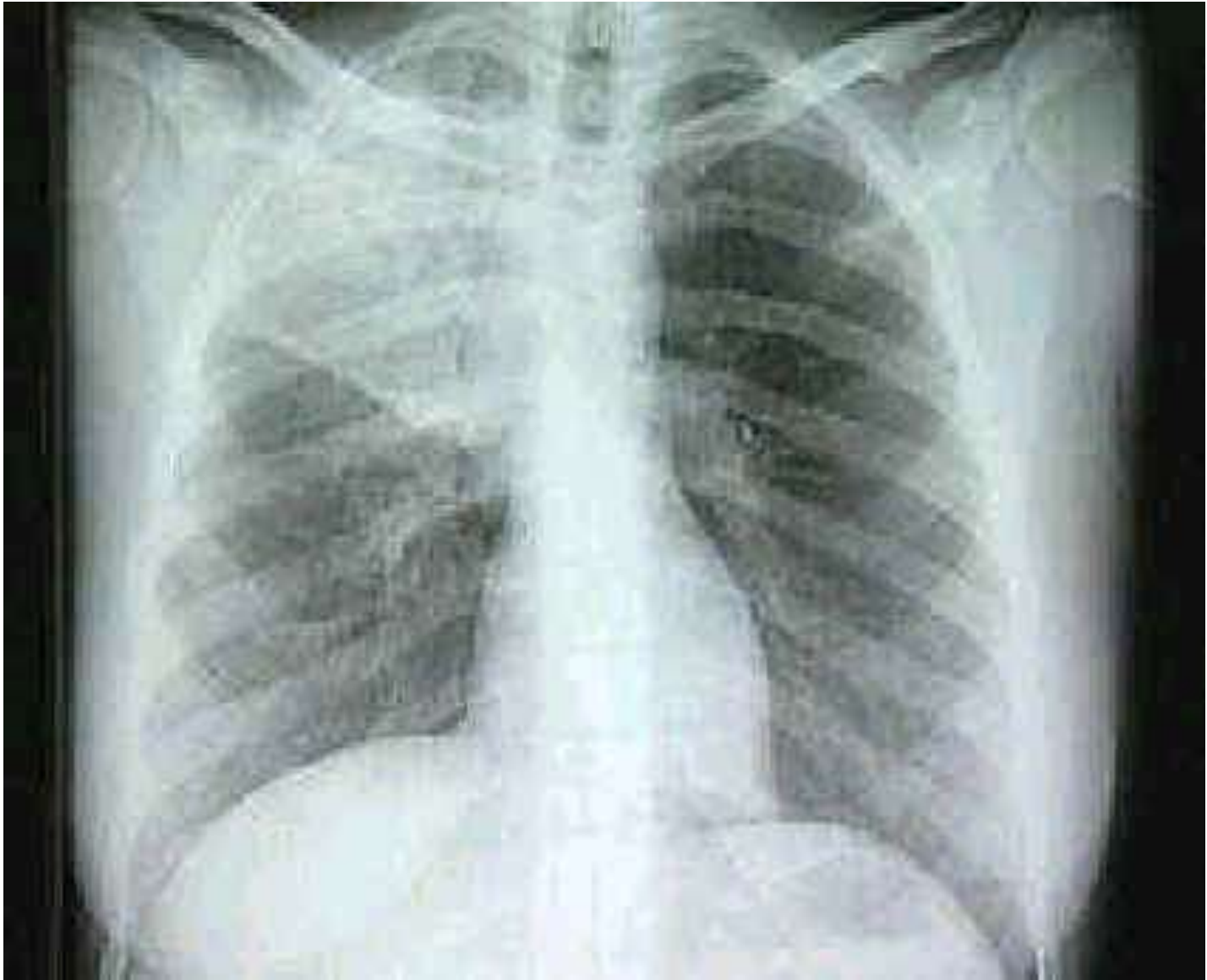

Masa mediastinica y derrame (linfoma linfobl.)

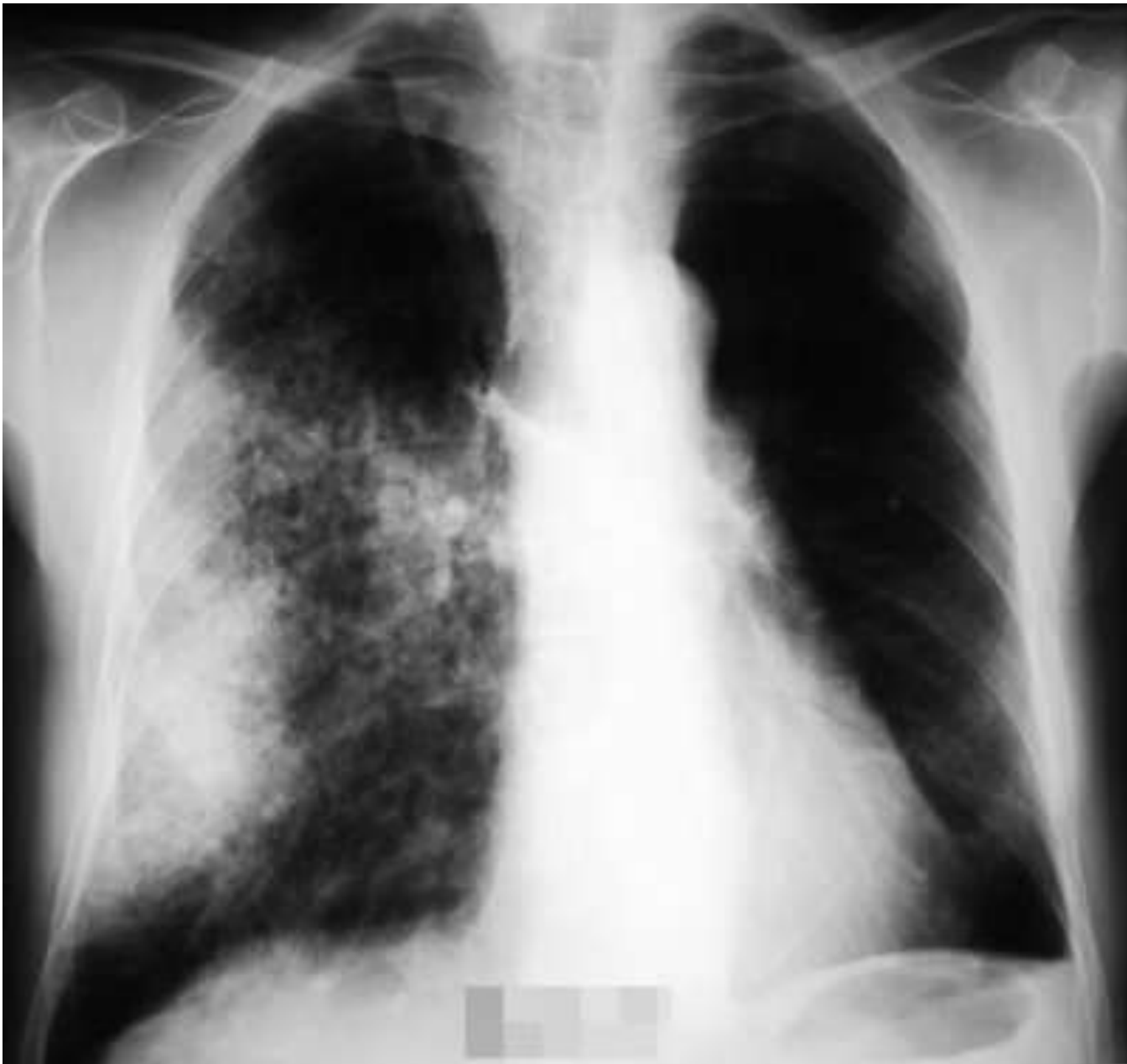



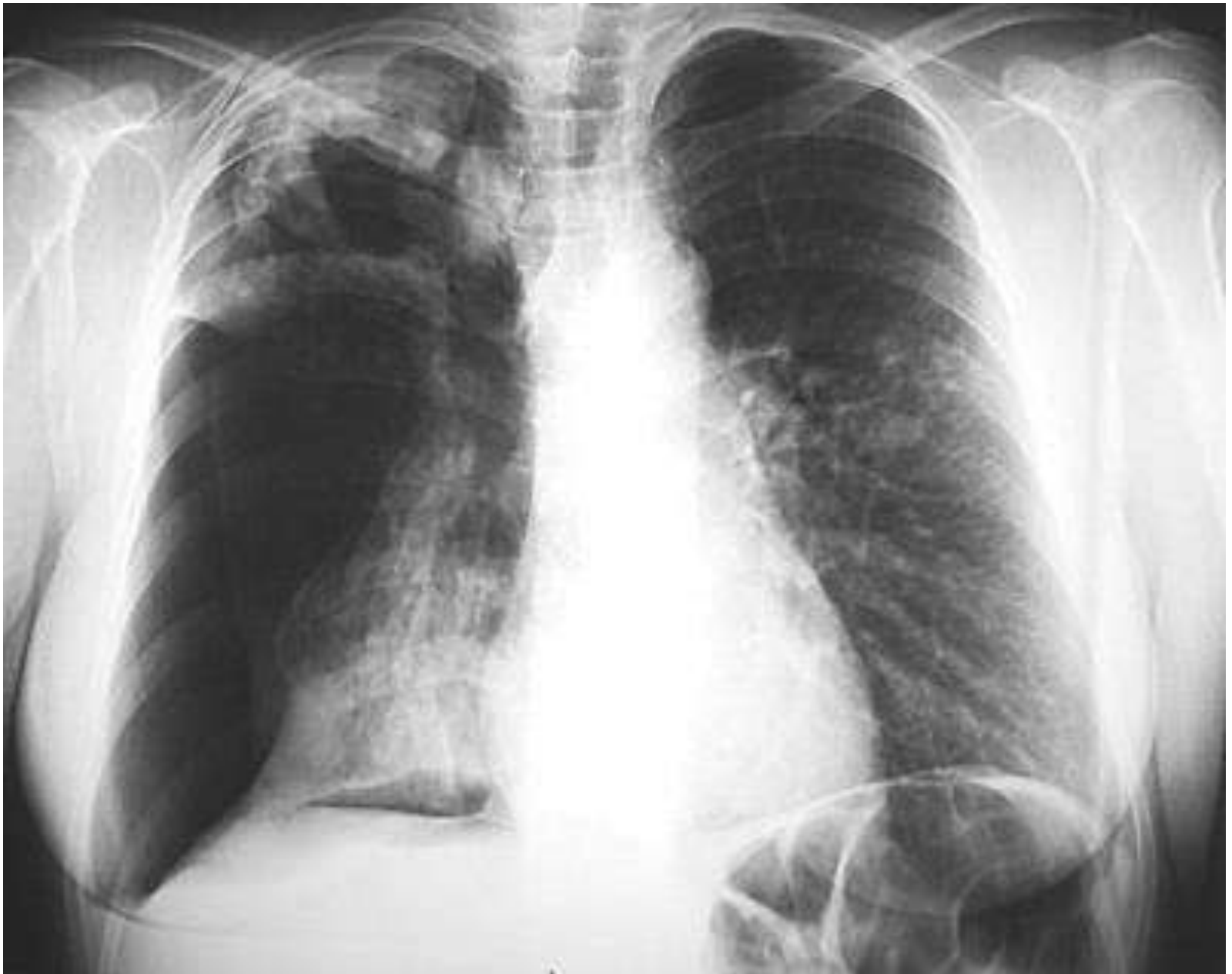Derrame y nódulos (mesotelioma)



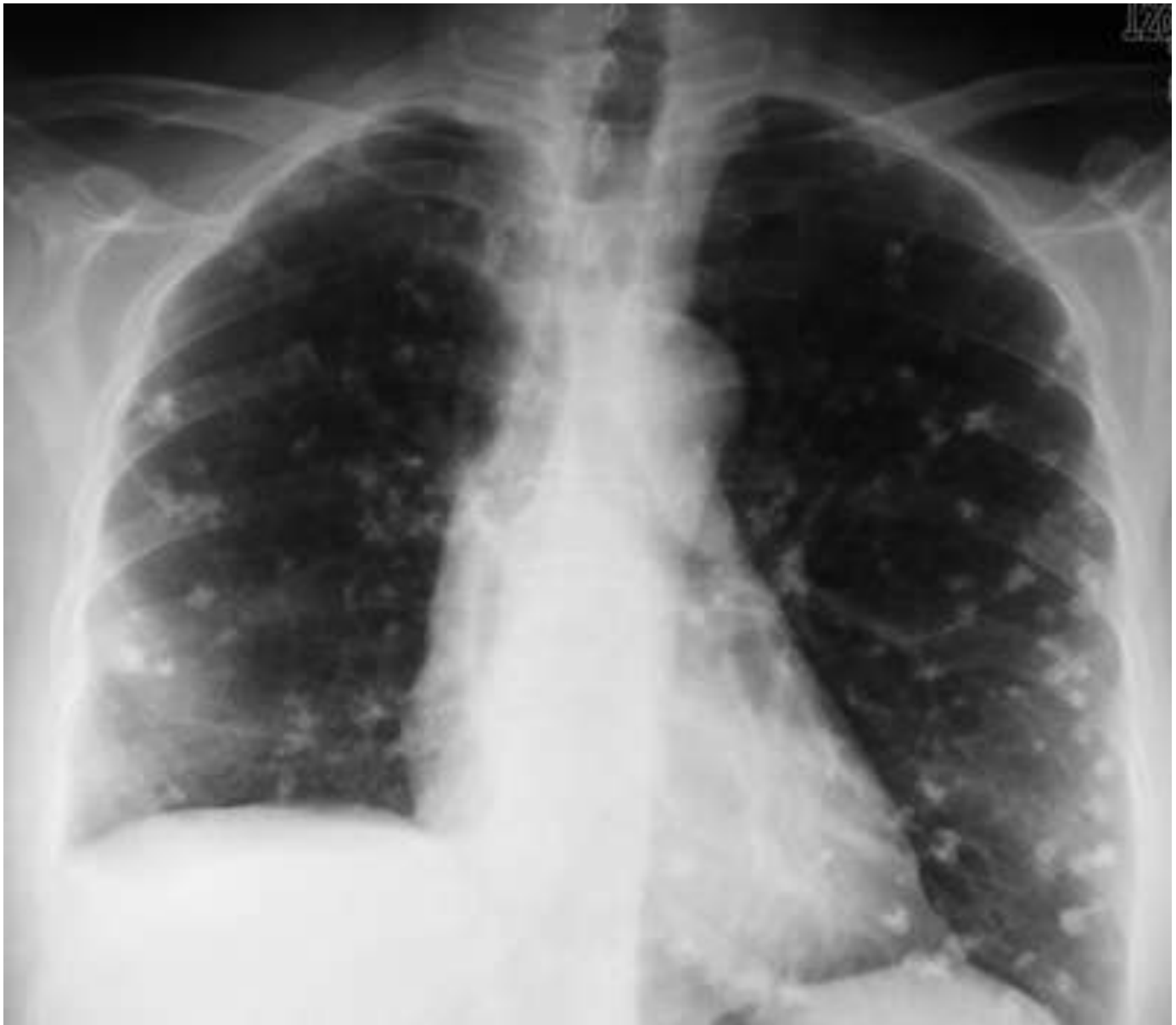Neumonía LSD



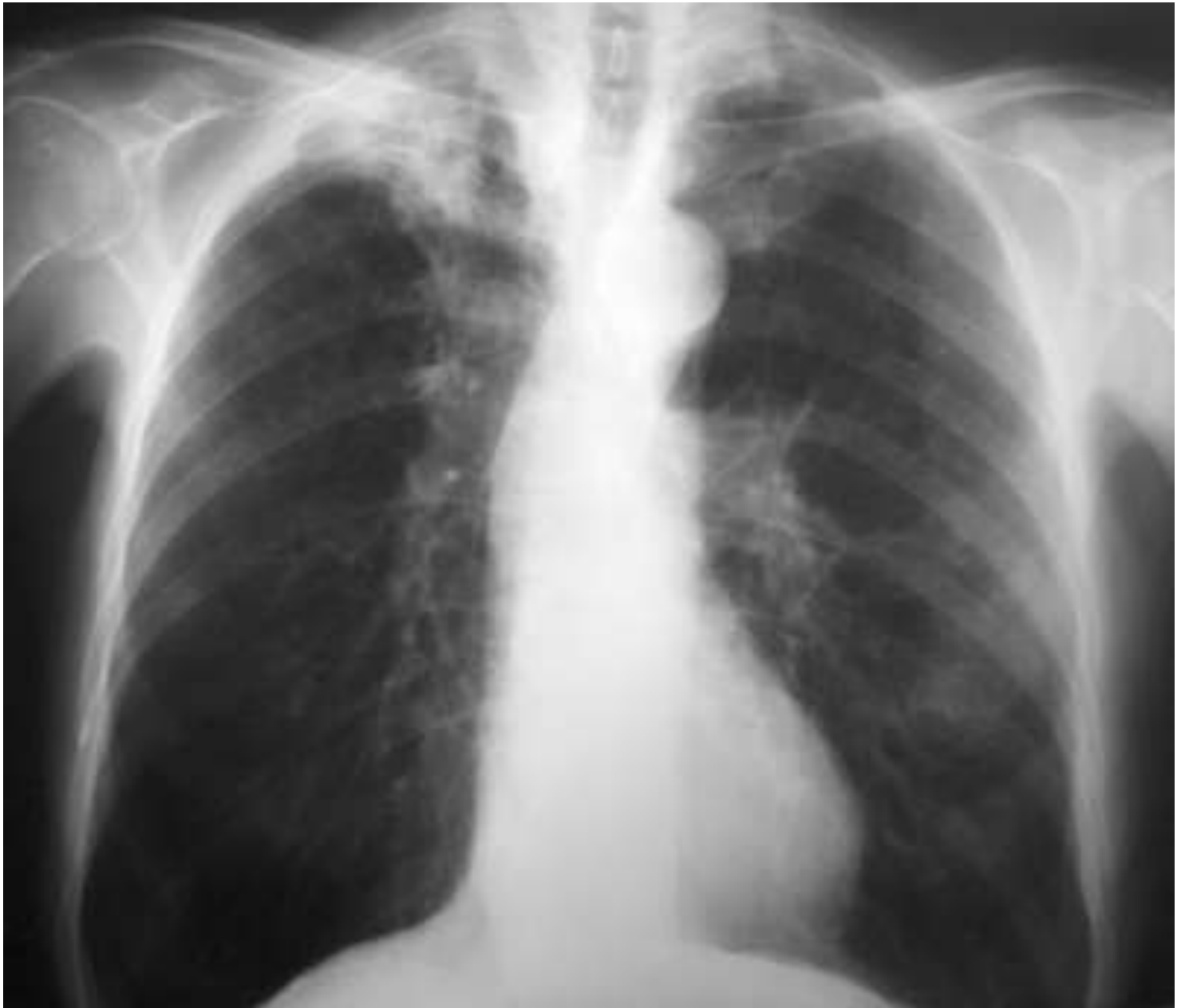Neumonía (patrón alveolar) y paquipleuritis



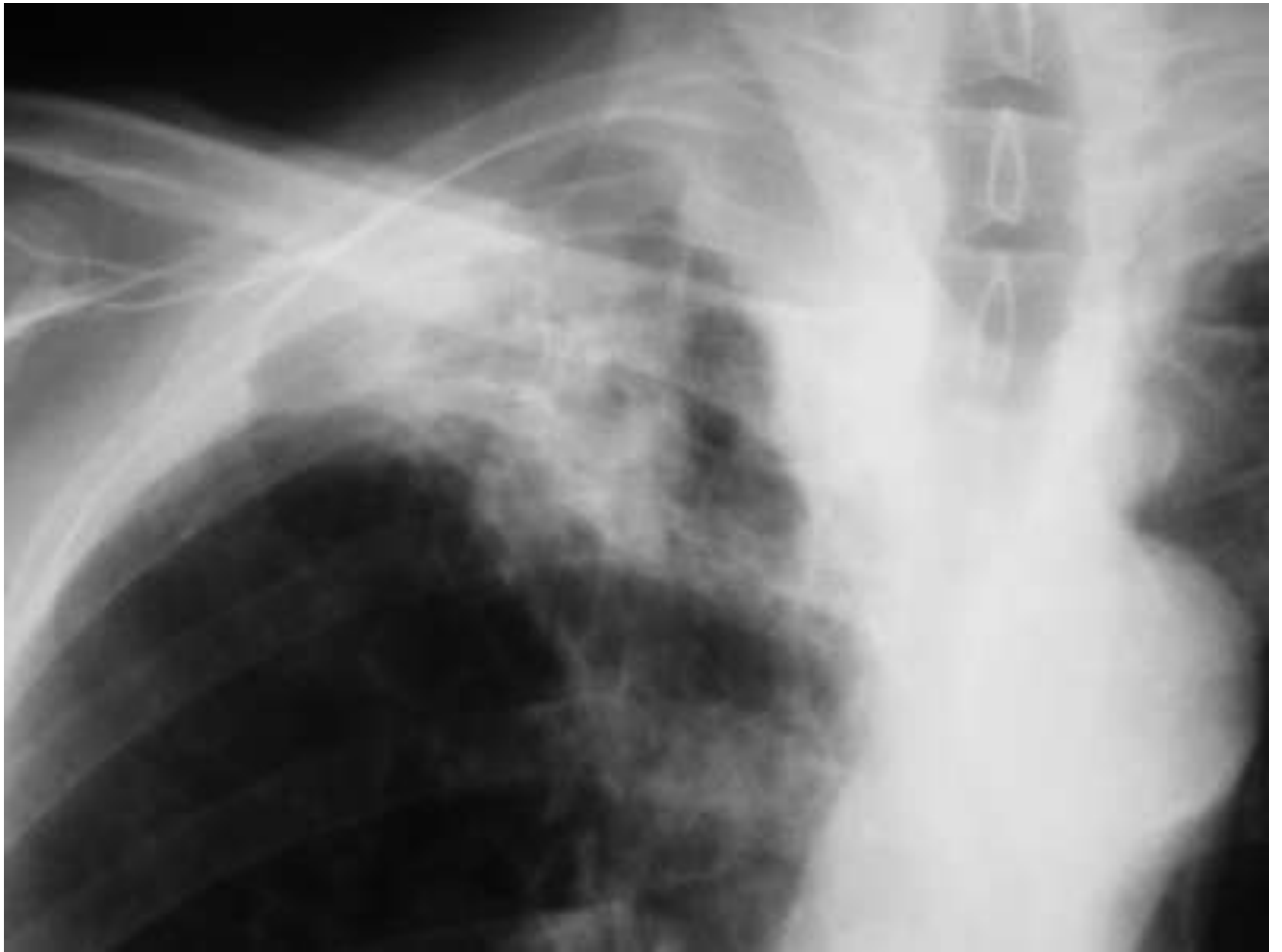Neumotórax y TB apical

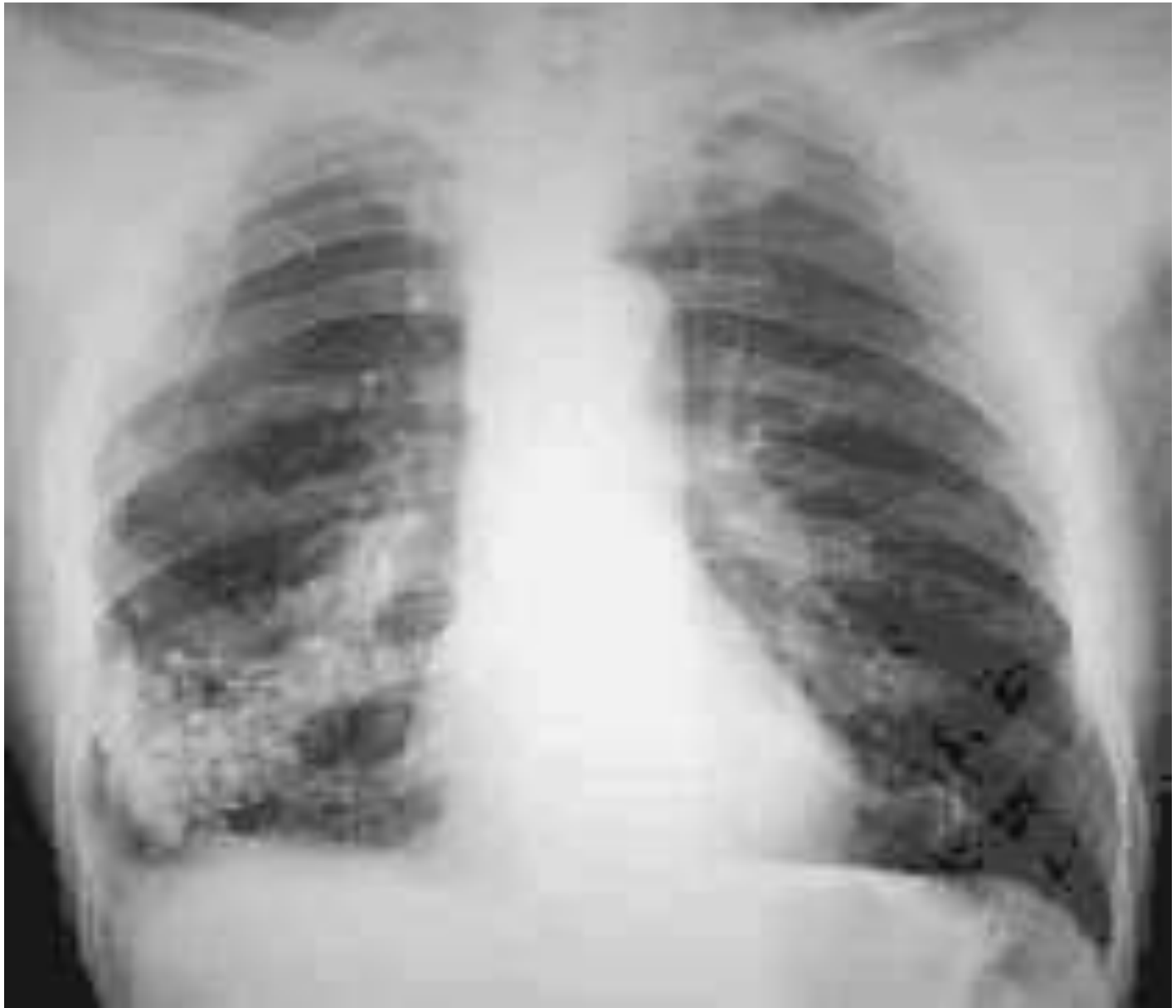

Nódulos calcificados y atelectasia LID (adenoca y varicela antigua)

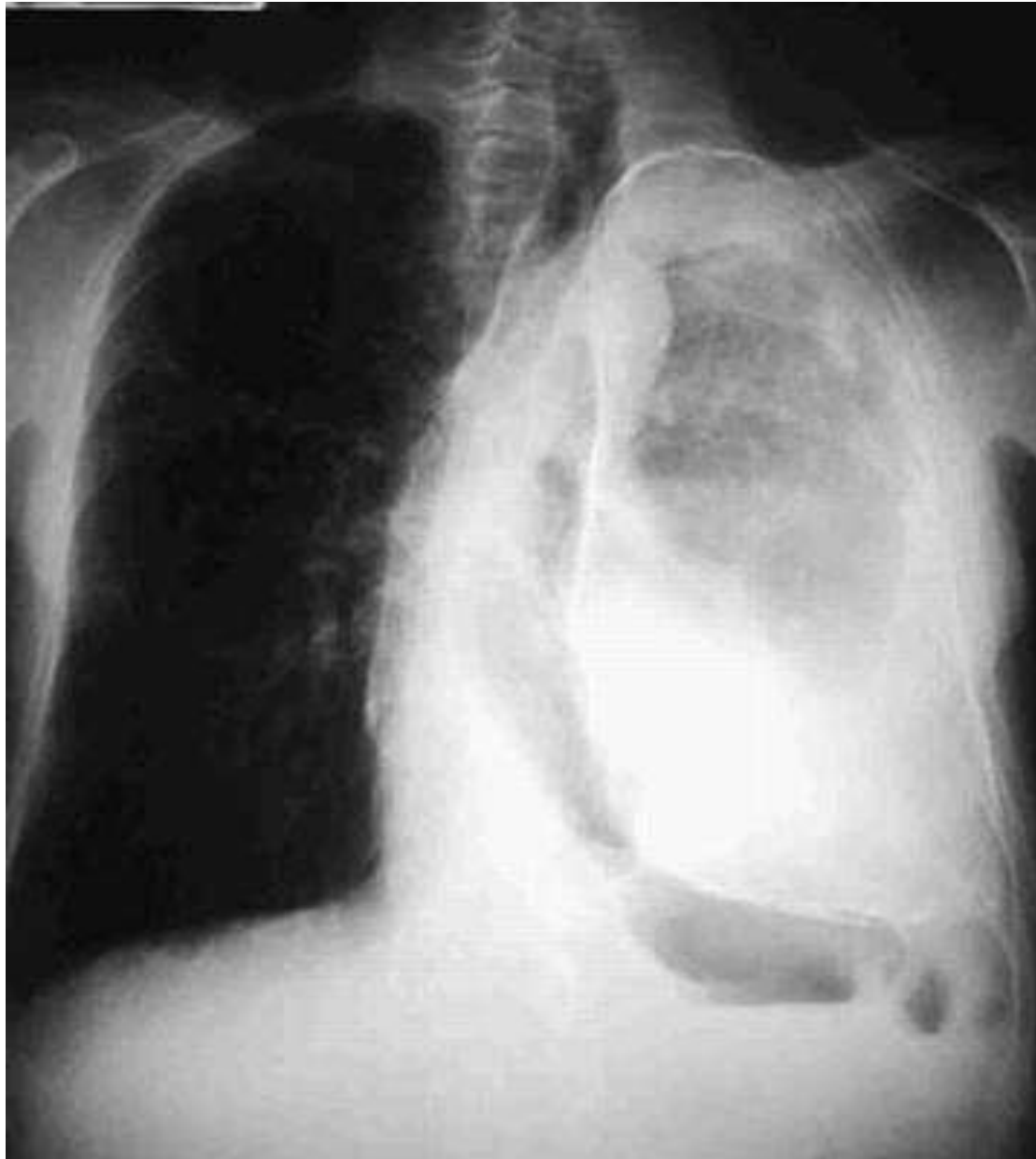


T. Pancoast

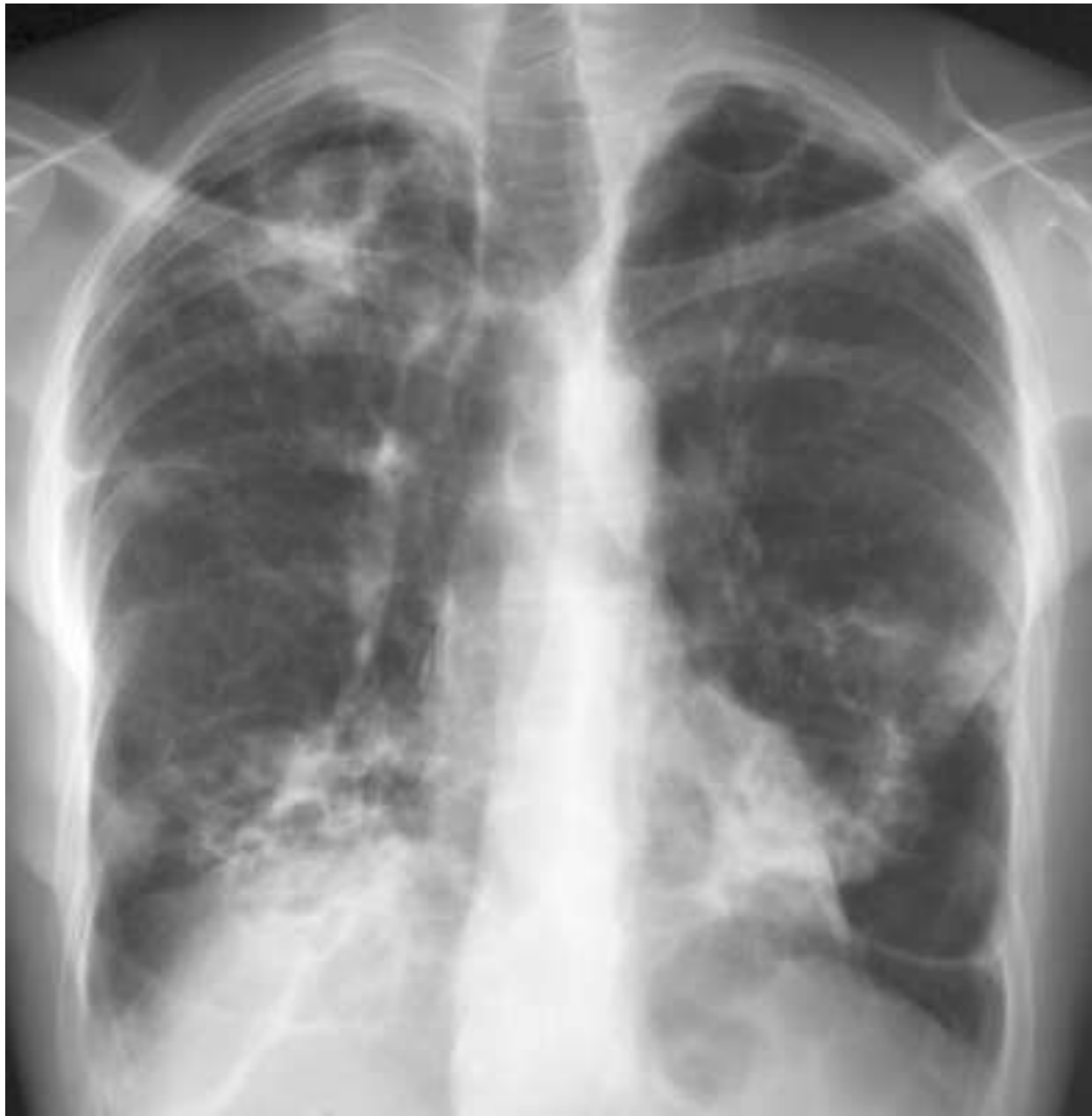



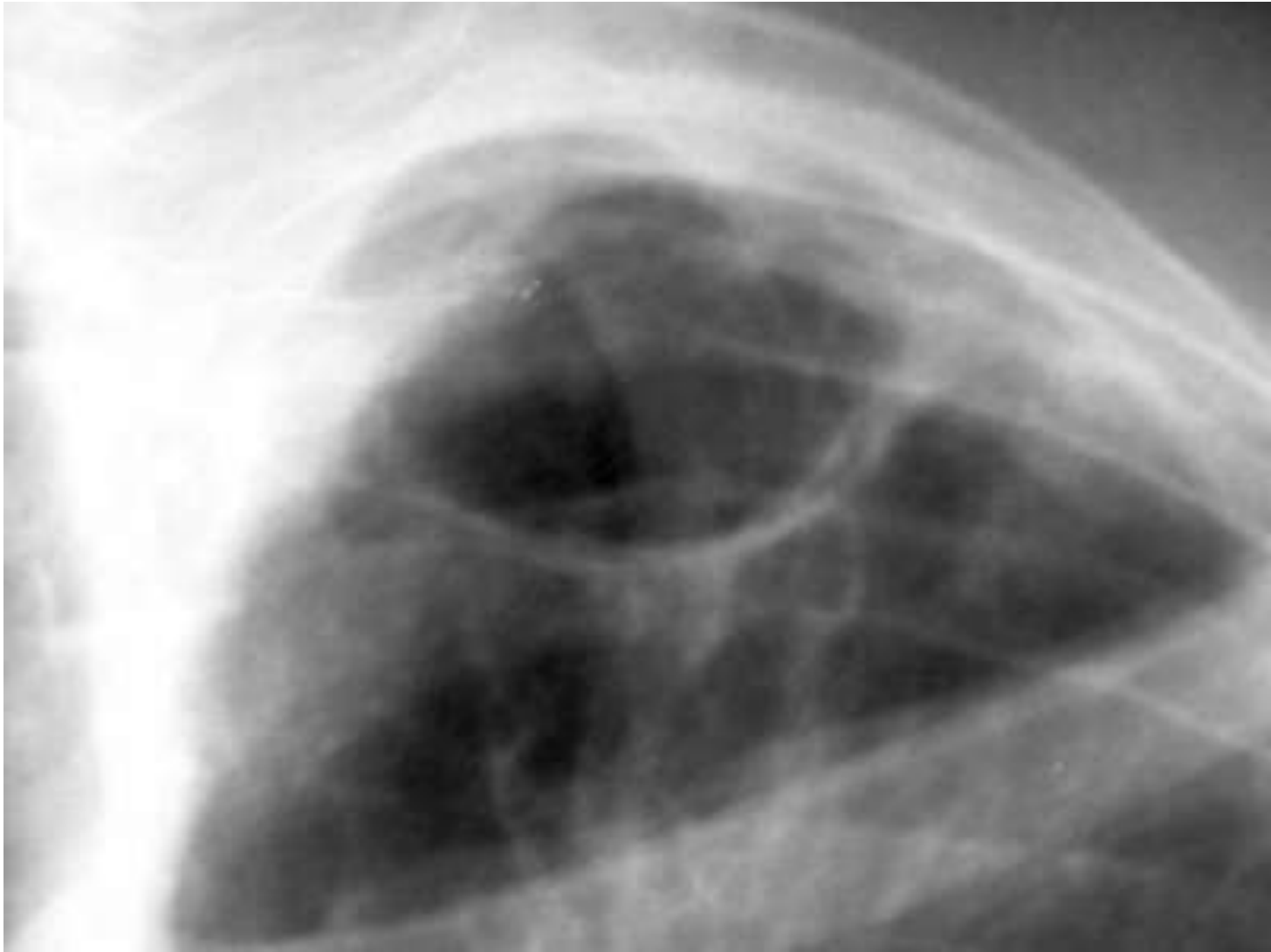
Paquipleuritis derecha

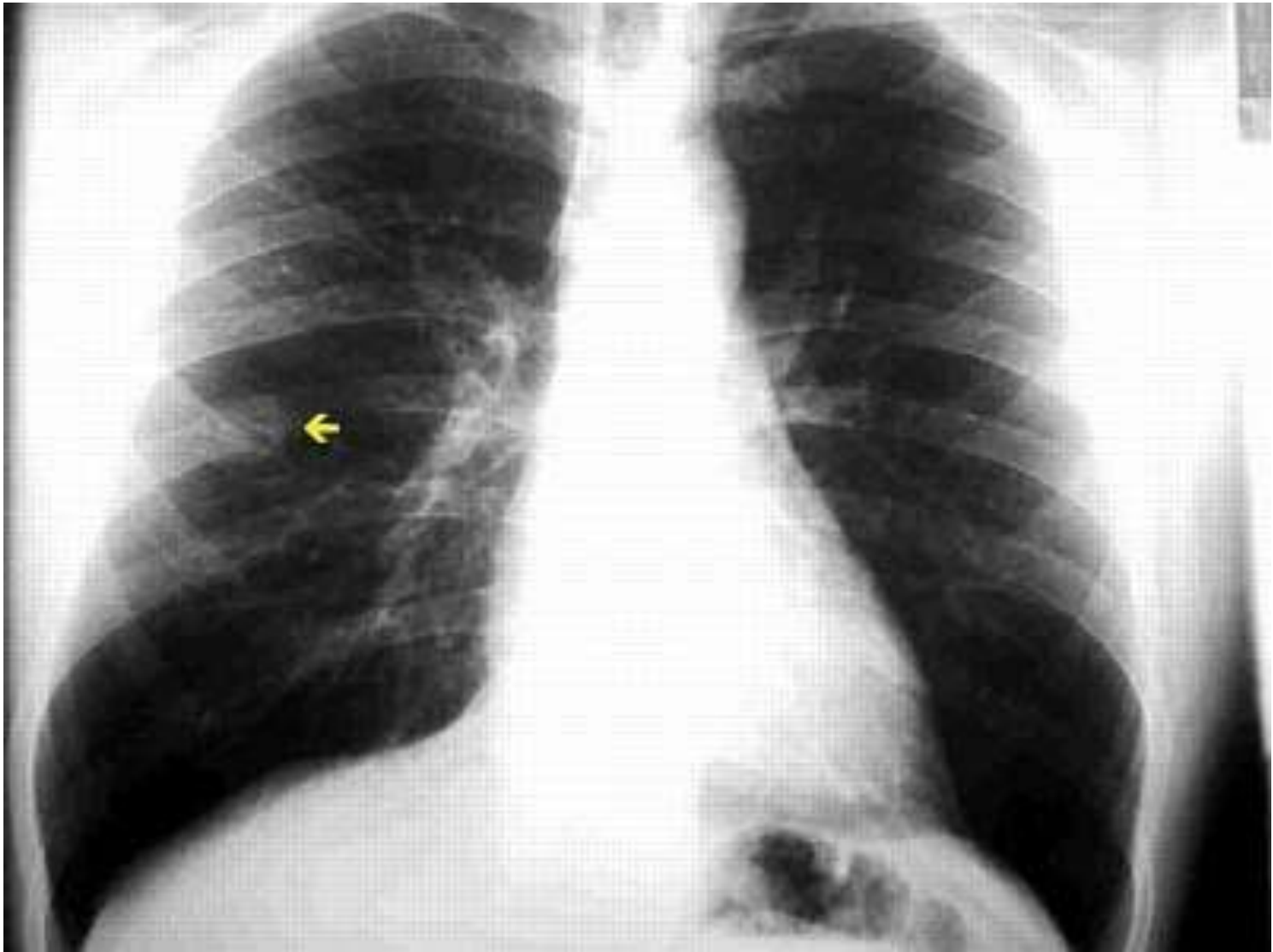


Paquipleuritis izda calcificada

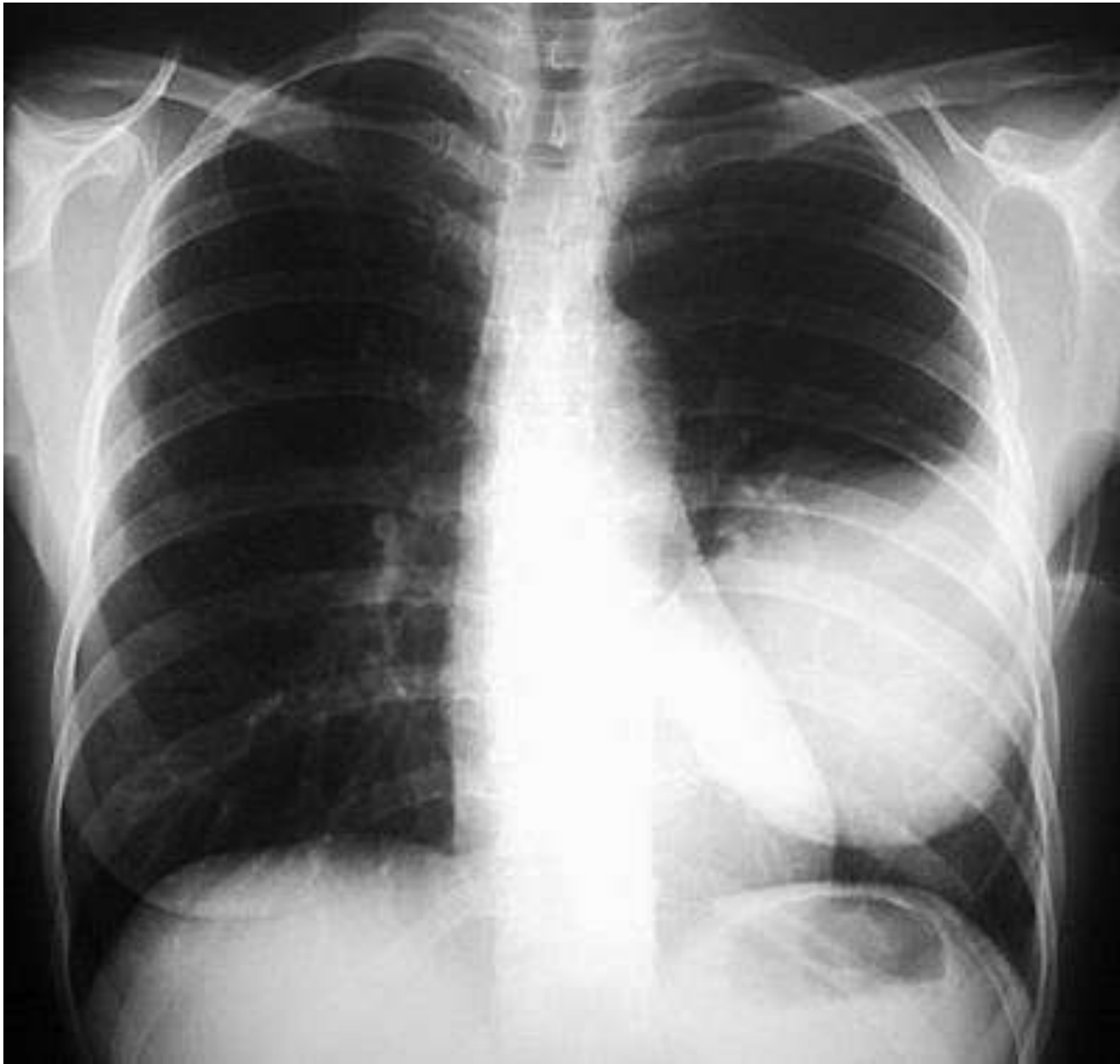

Patrón destructivo con bullas (fibrosis quística v/s aspergilosis)

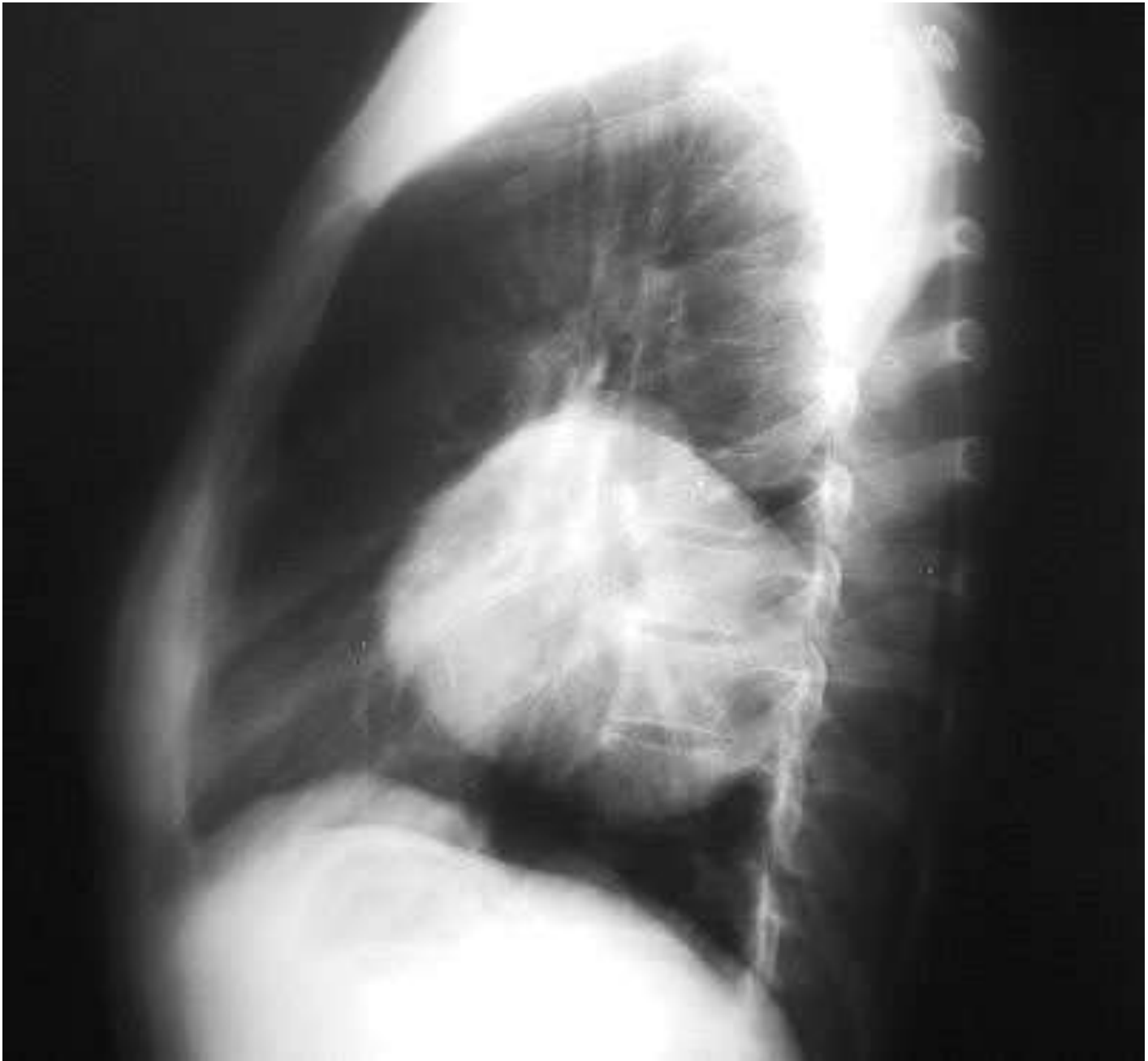


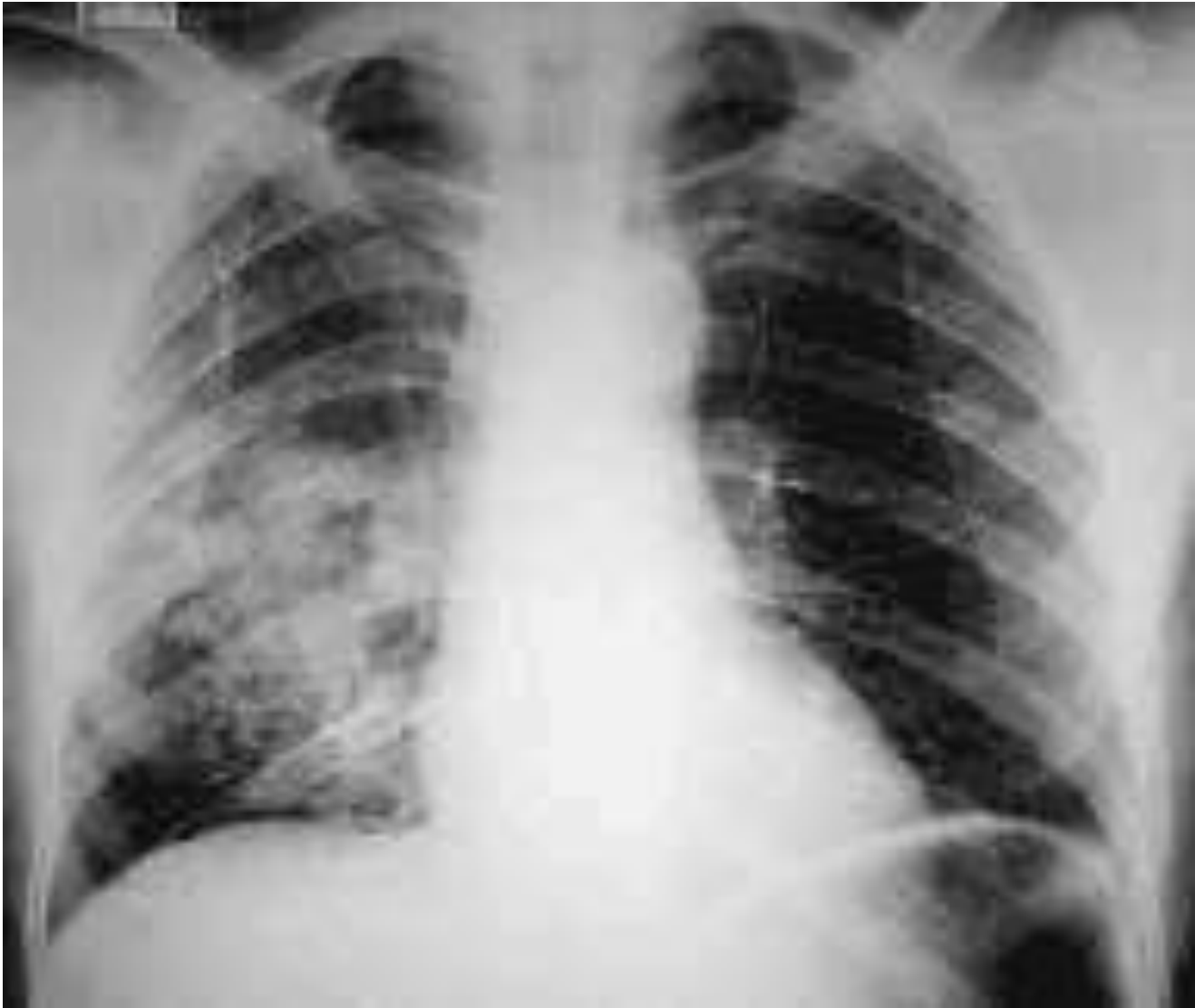
Pseudonódulo (callo de fractura)

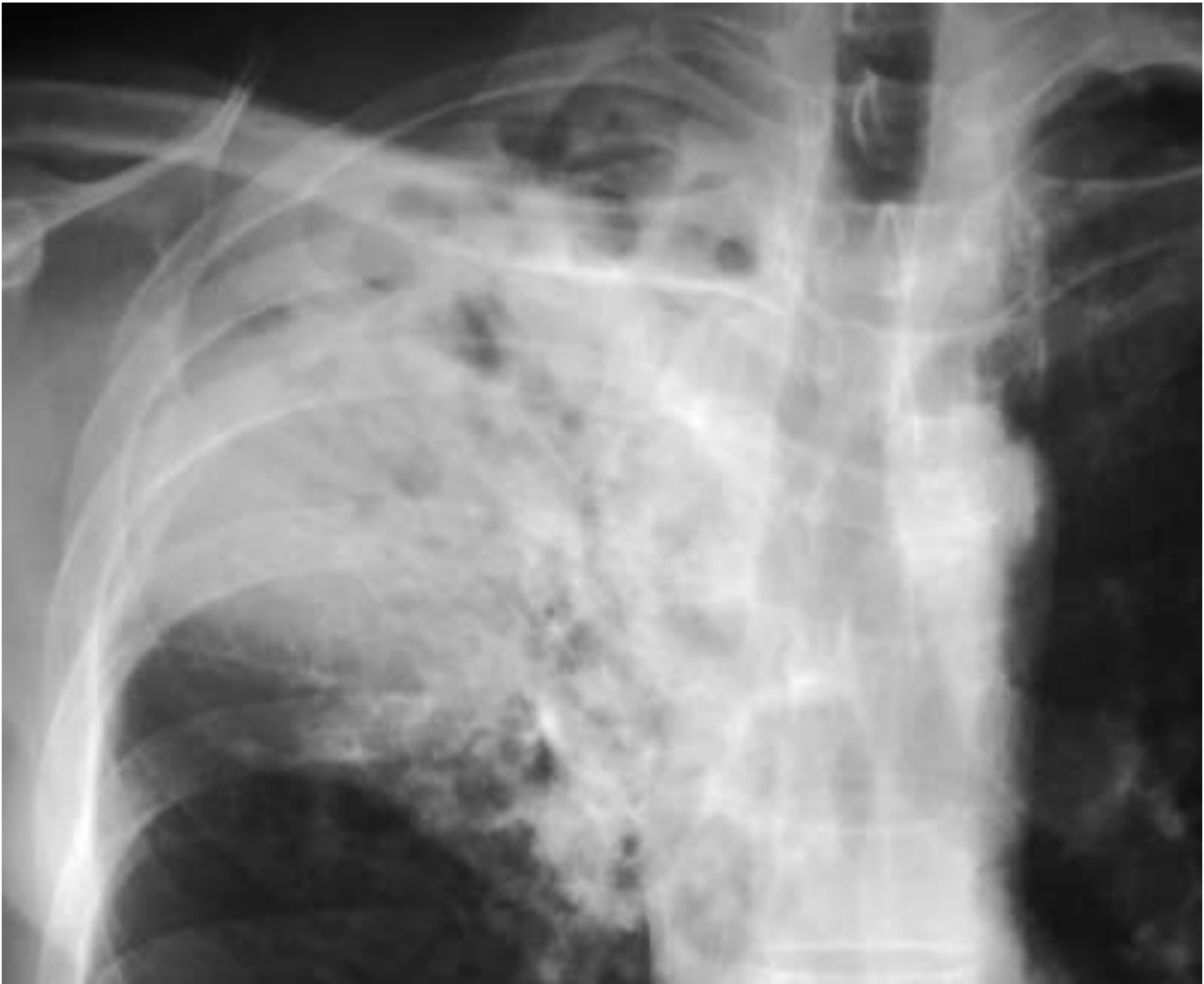

Quiste hidatídico

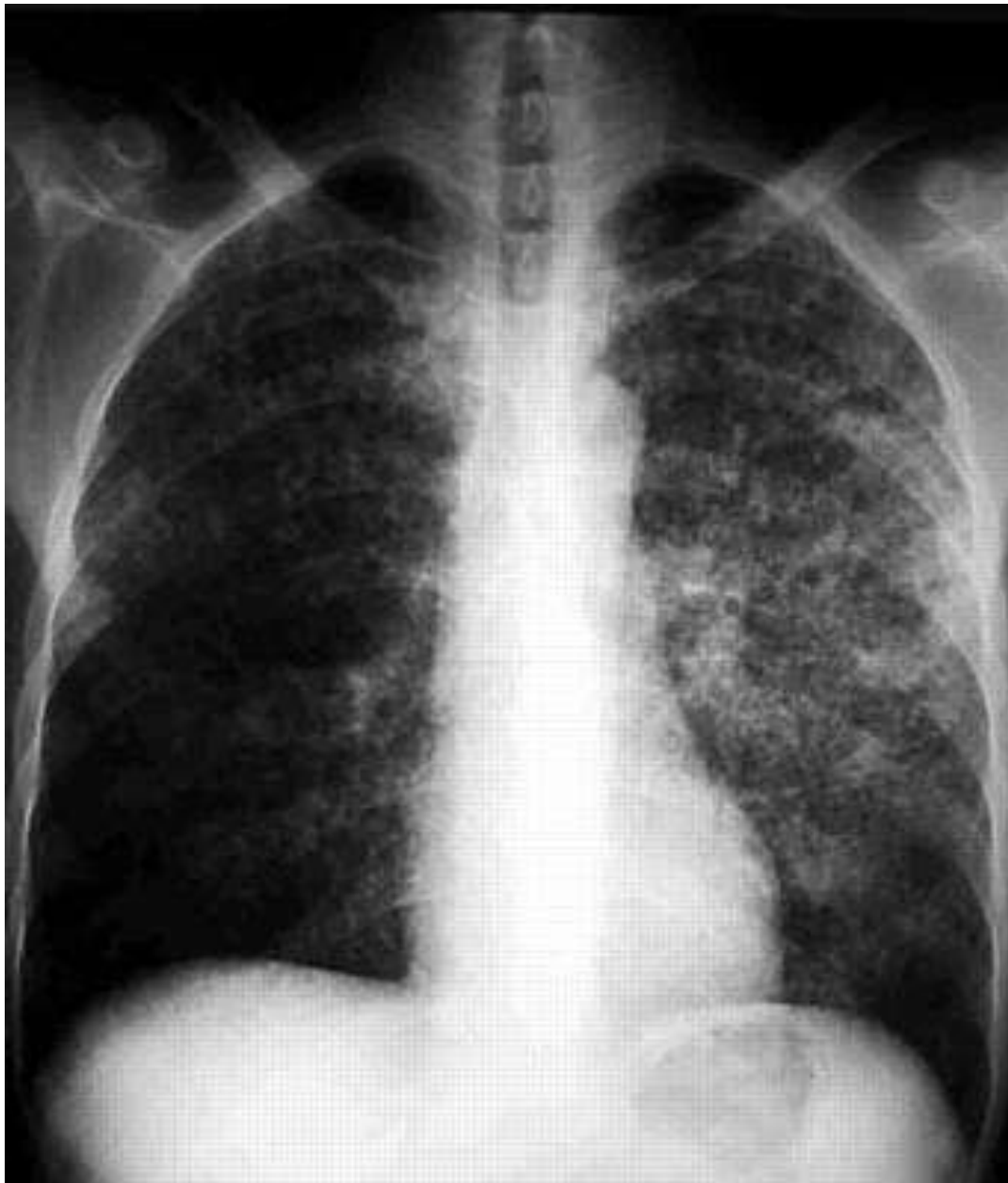




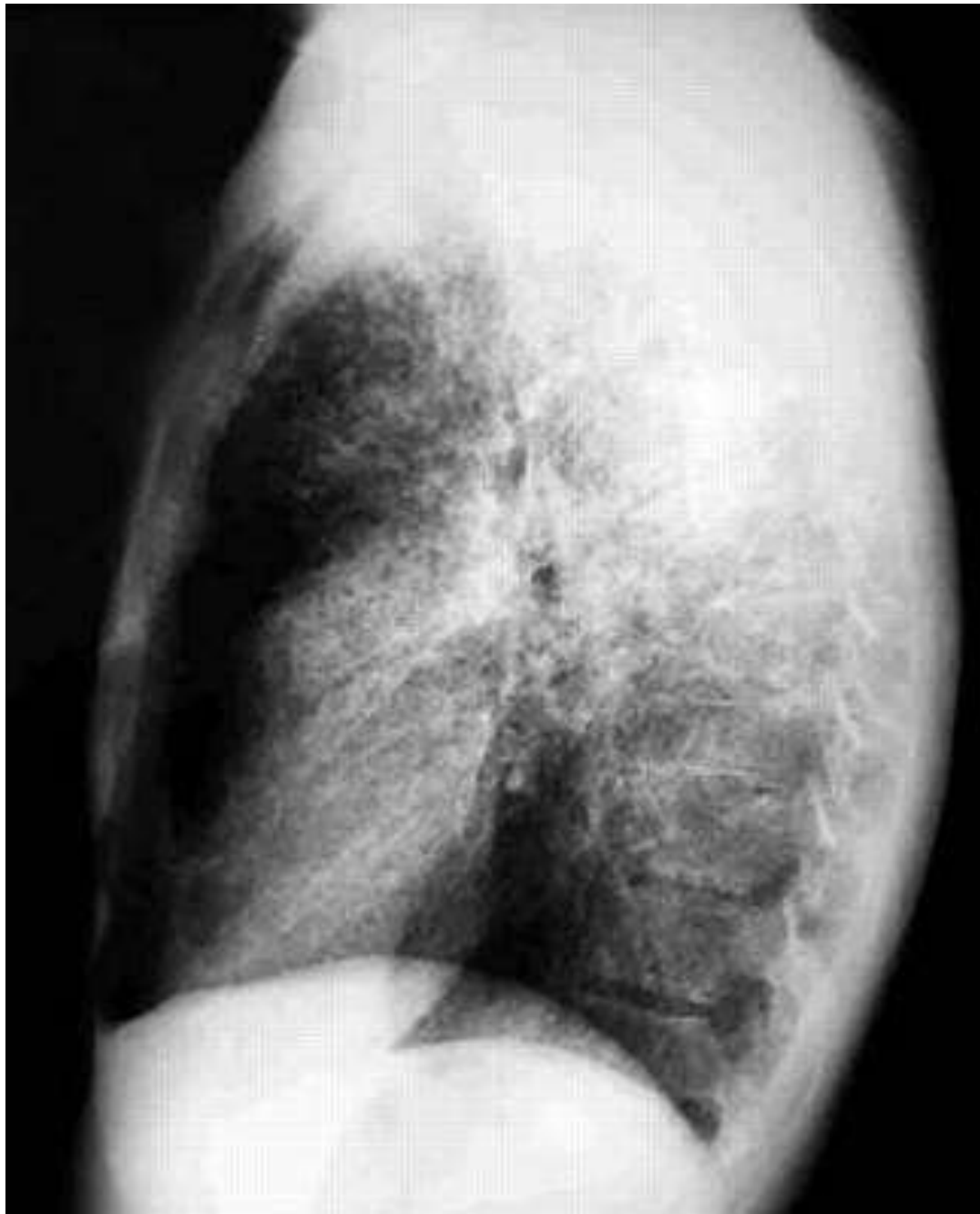Bronconeumonía dcha

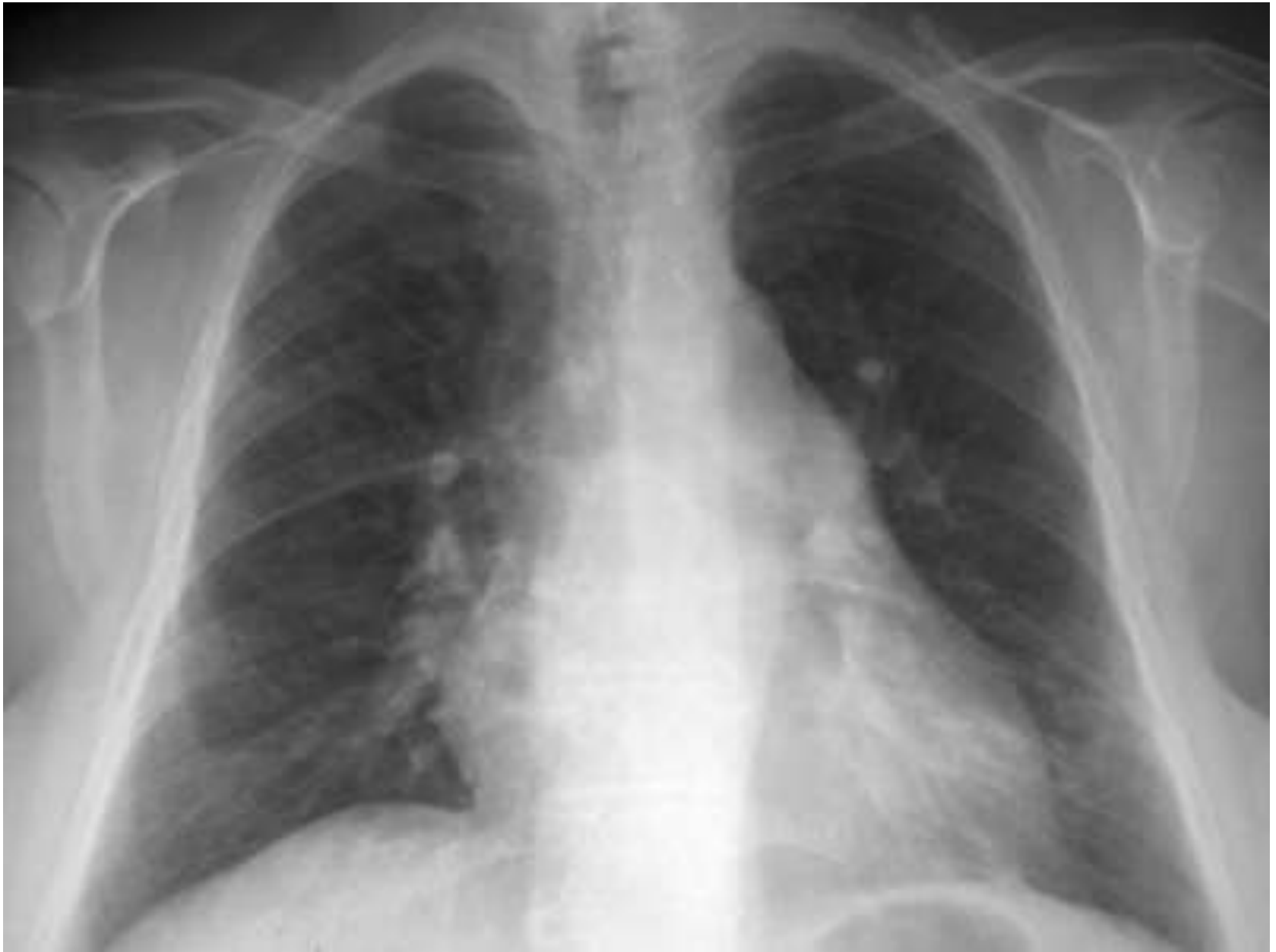

Infiltrado alveolar en LSD (TB)

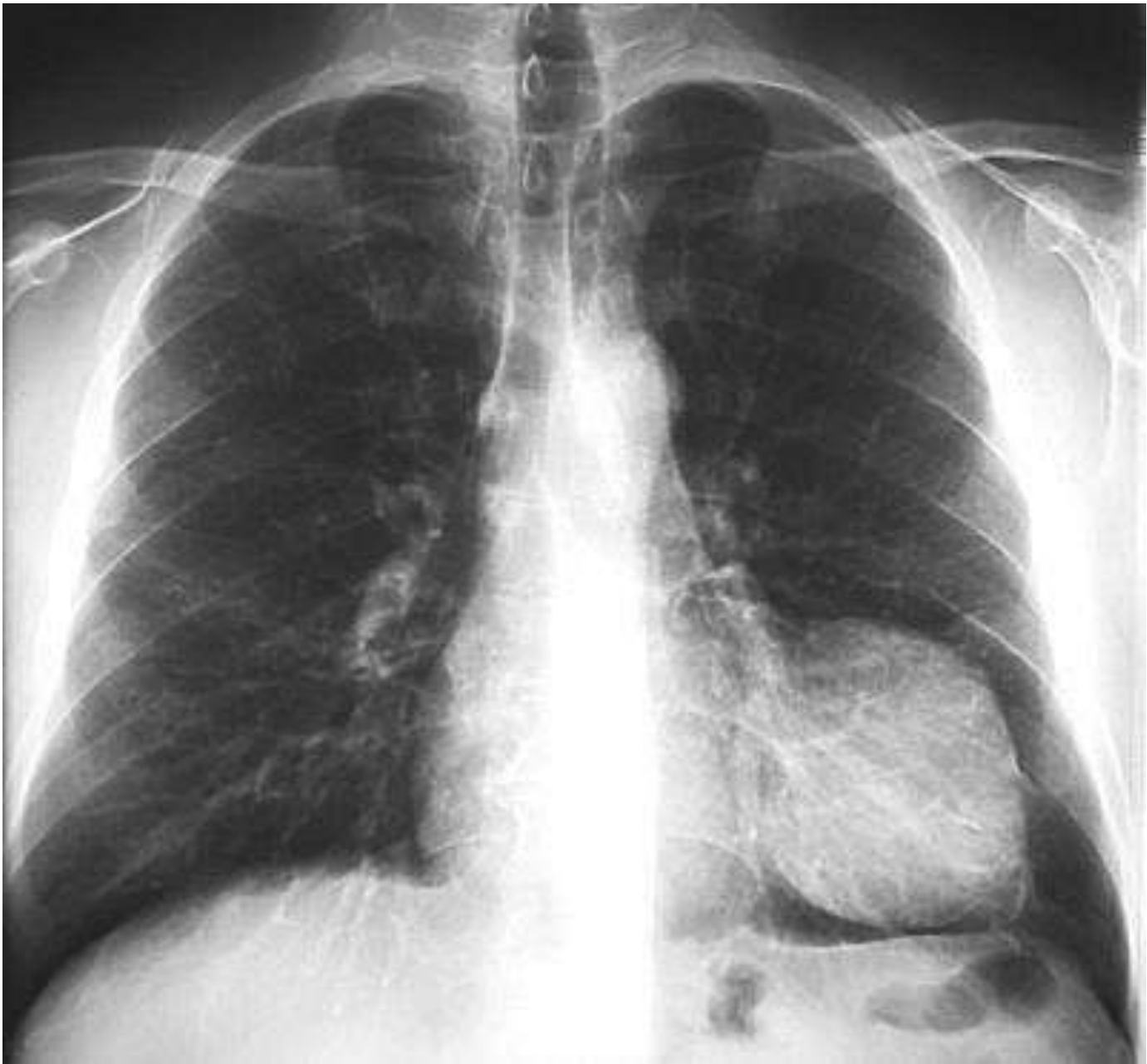

TB miliar

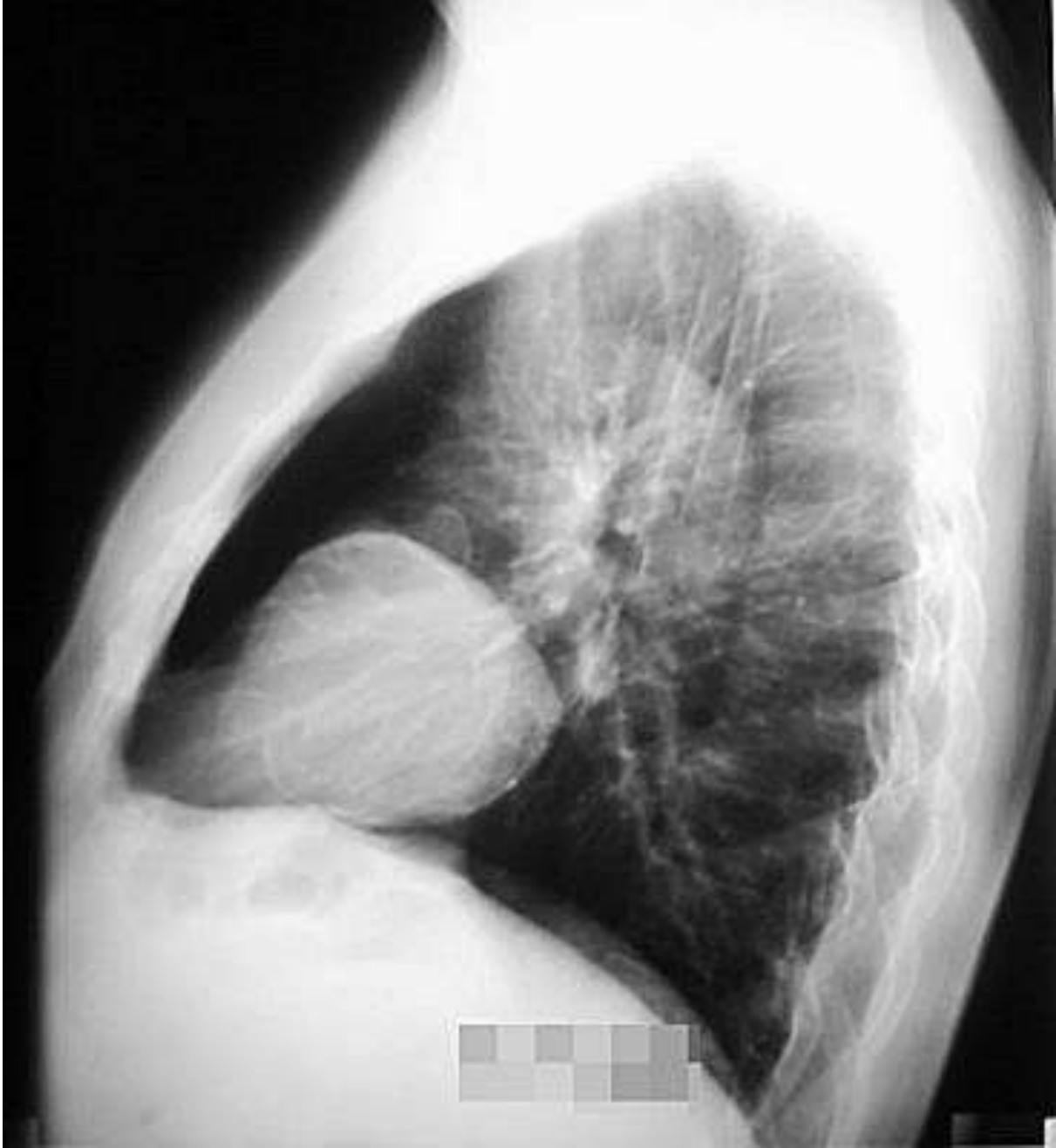


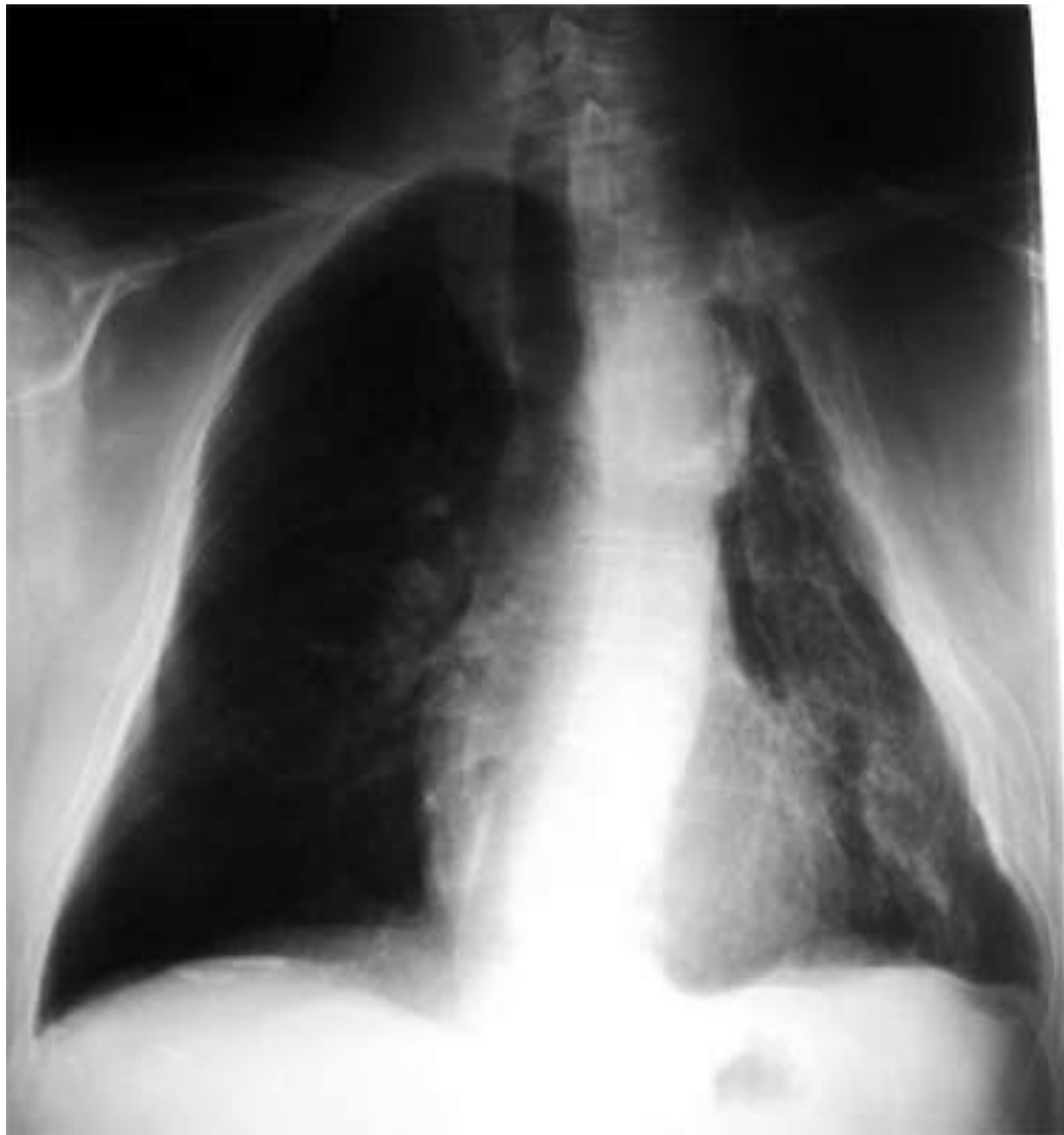
Agrandamiento cono pulmonar (TEP)

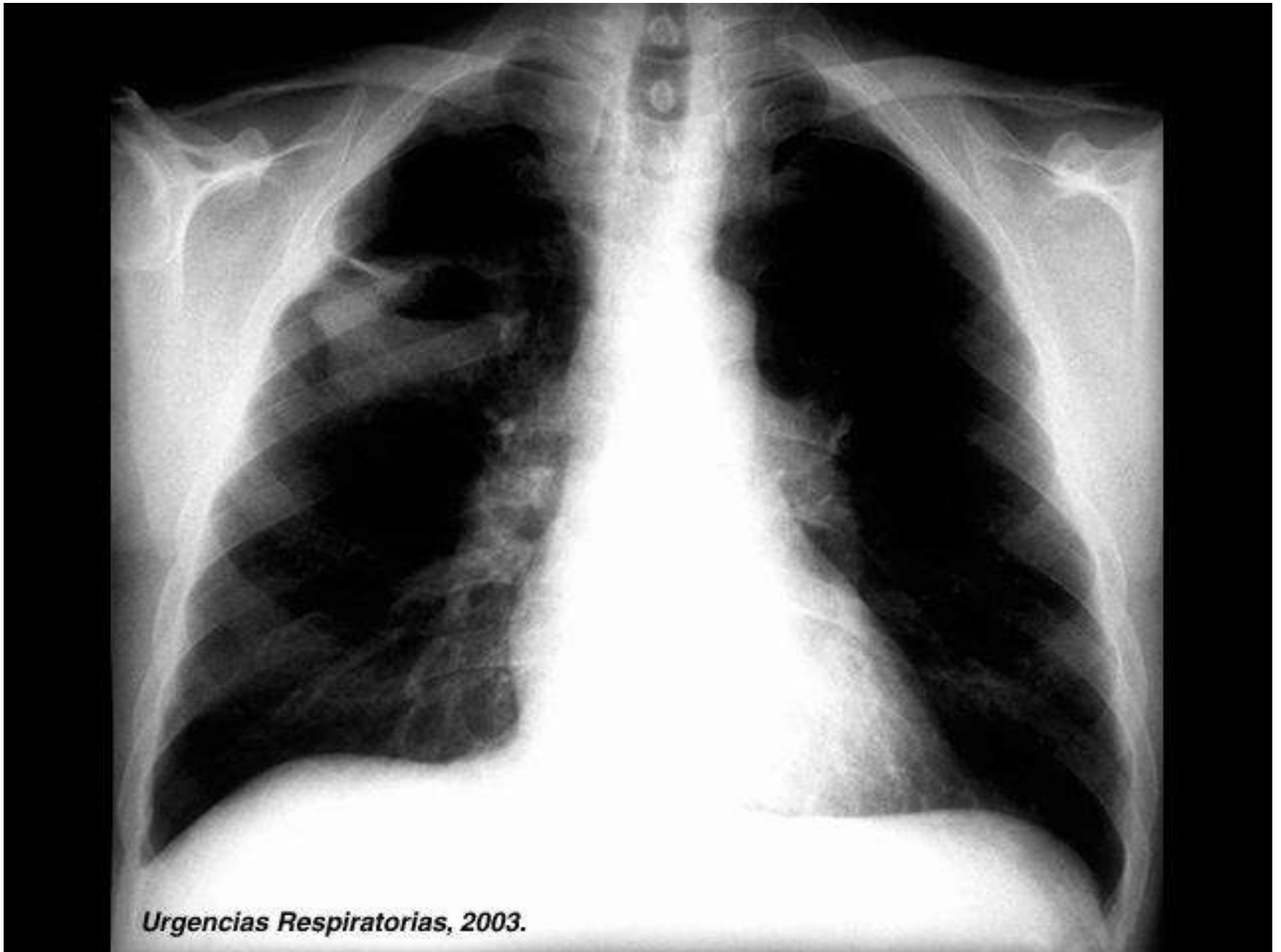


timoma



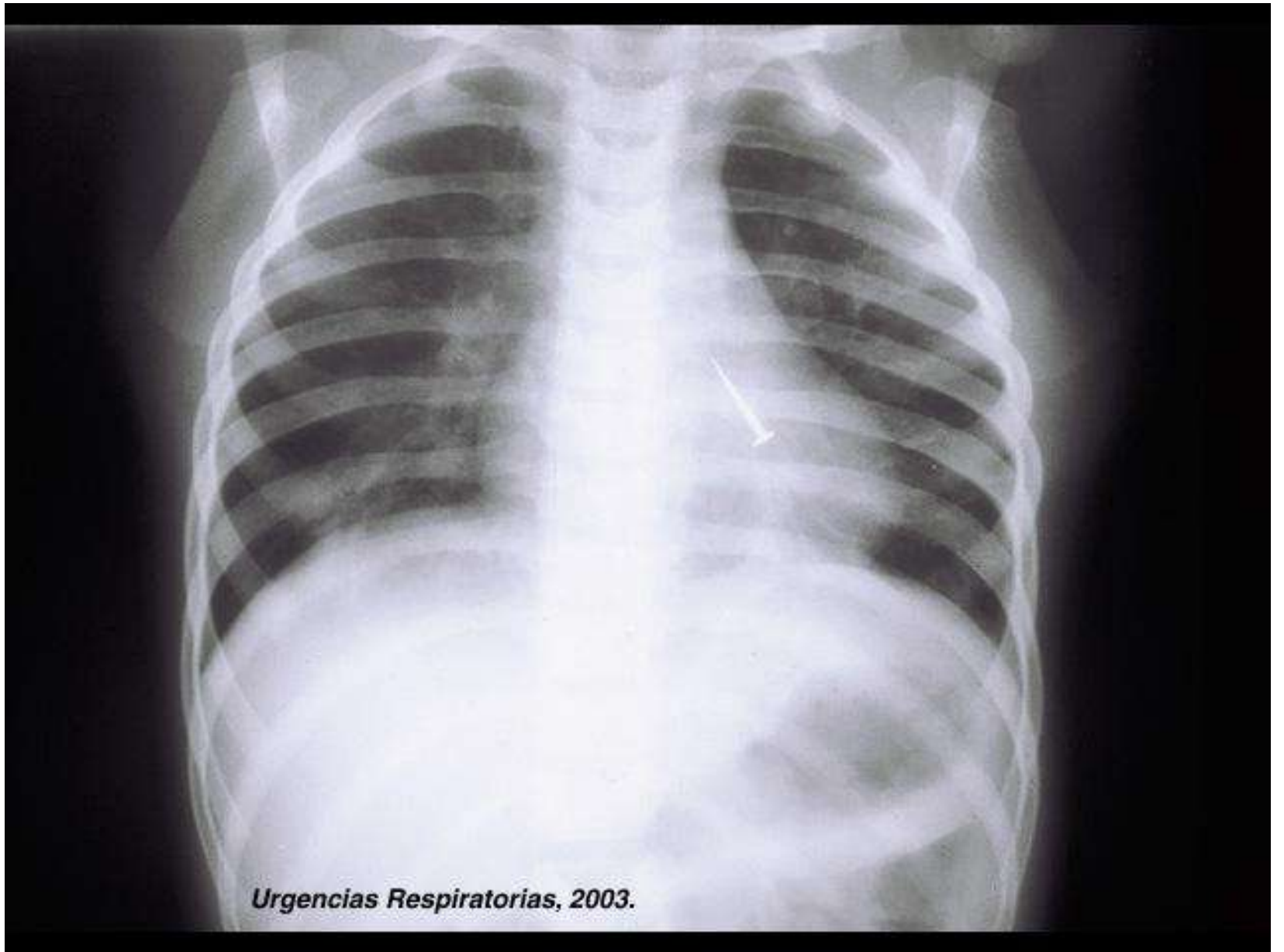


Toracoplastia izda por TB

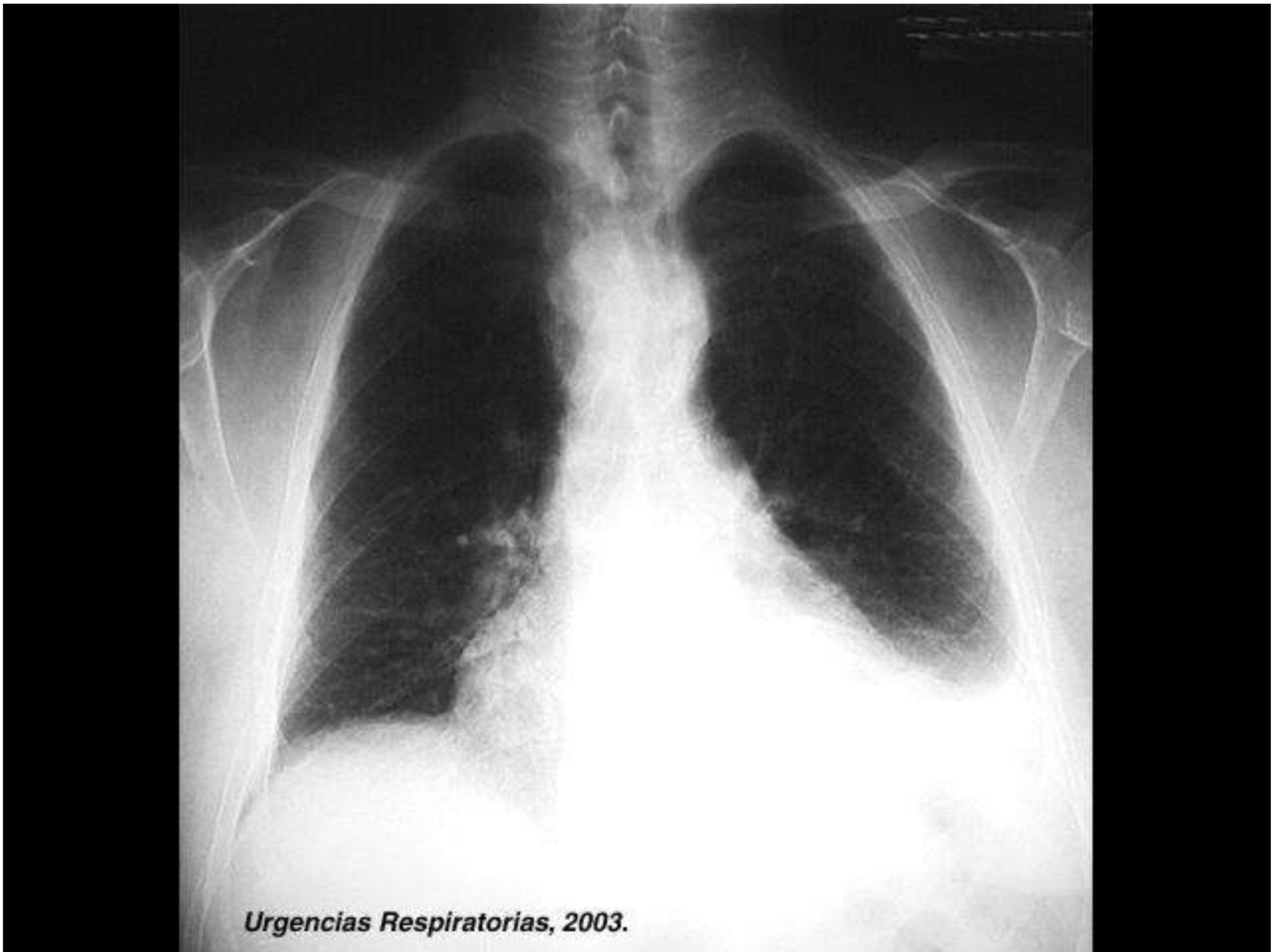


Urgencias Respiratorias, 2003.

Ca epidermoide

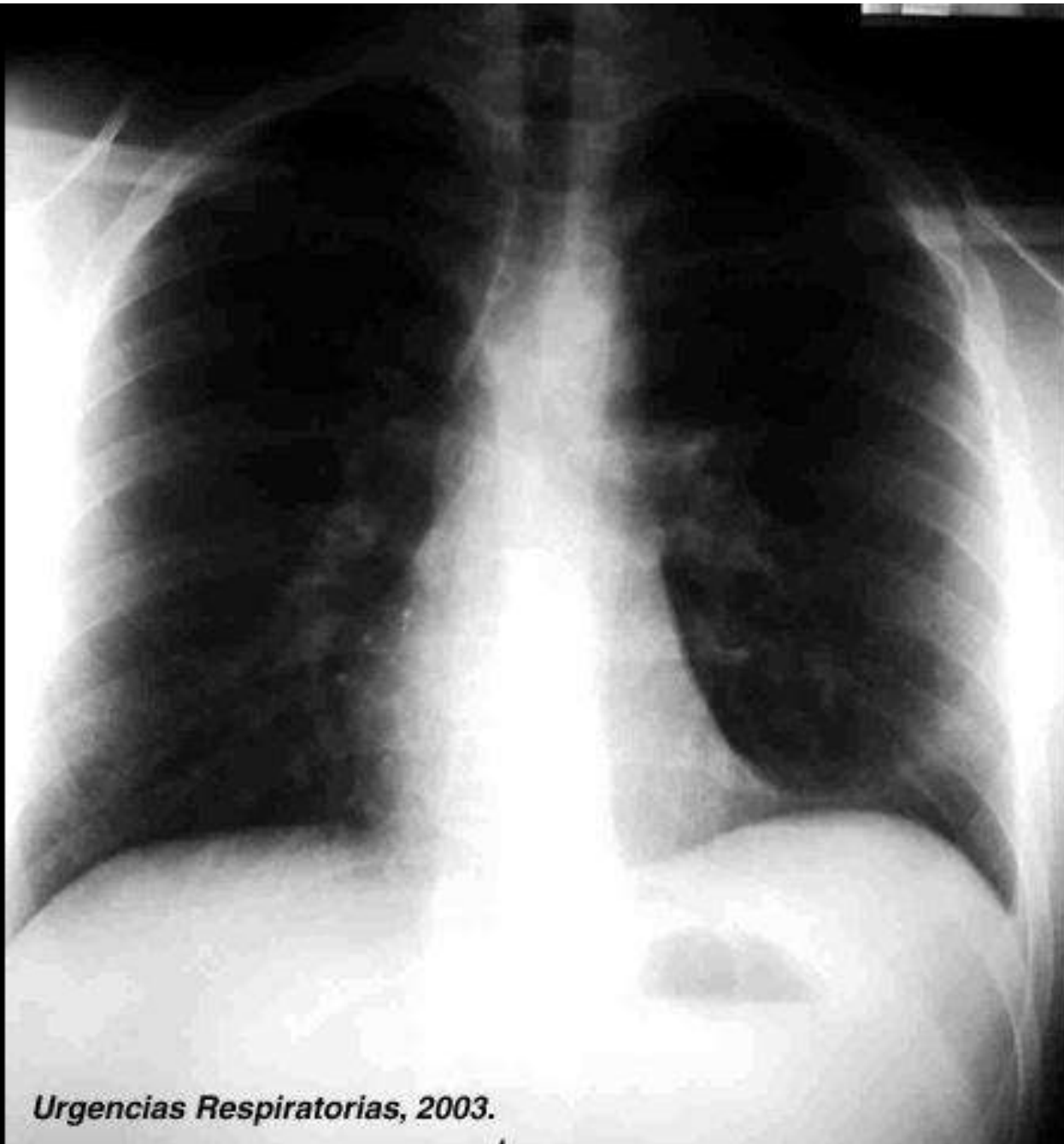


Urgencias Respiratorias, 2003.



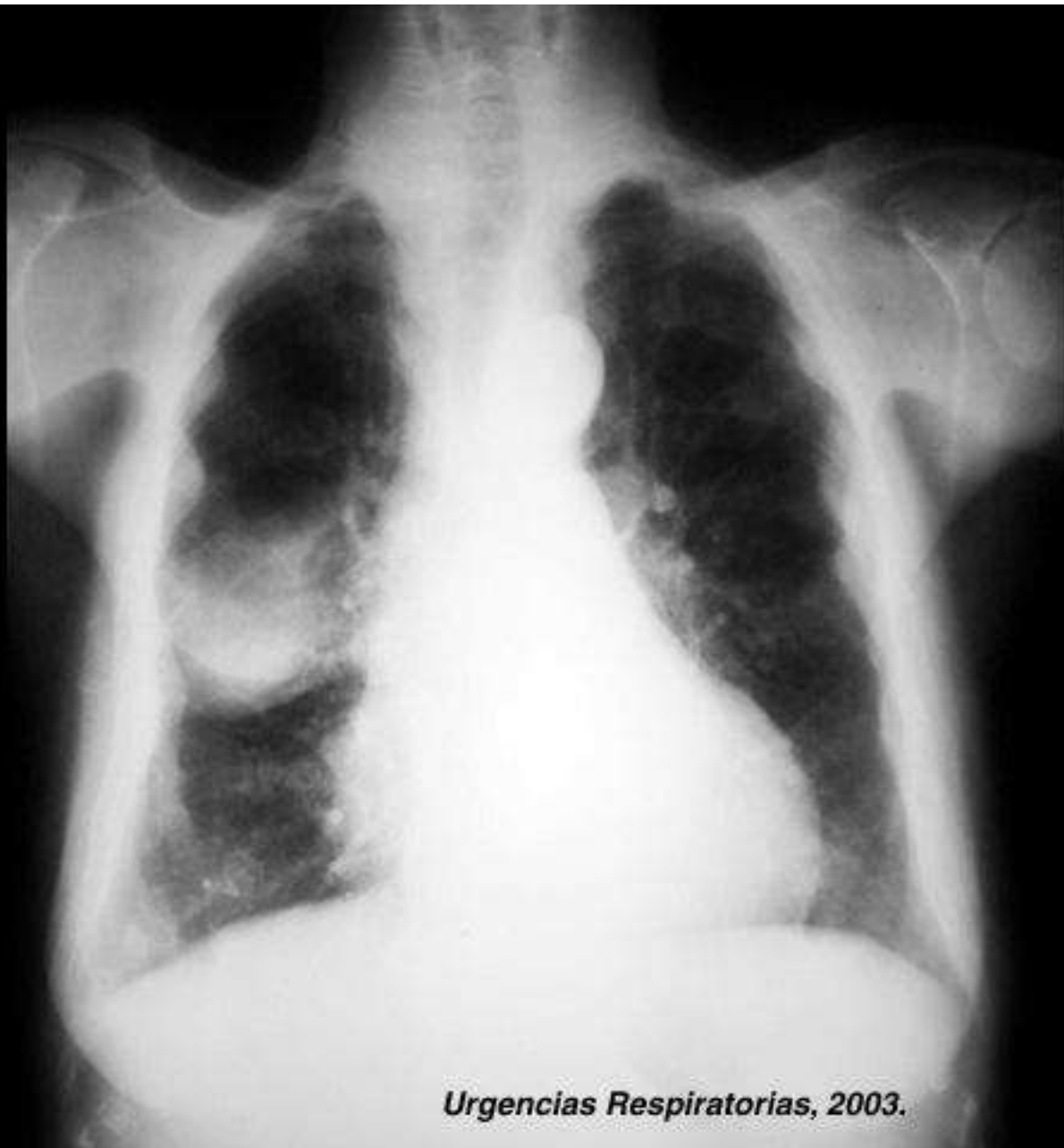
Urgencias Respiratorias, 2003.

Derrame pleural izdo



Urgencias Respiratorias, 2003.

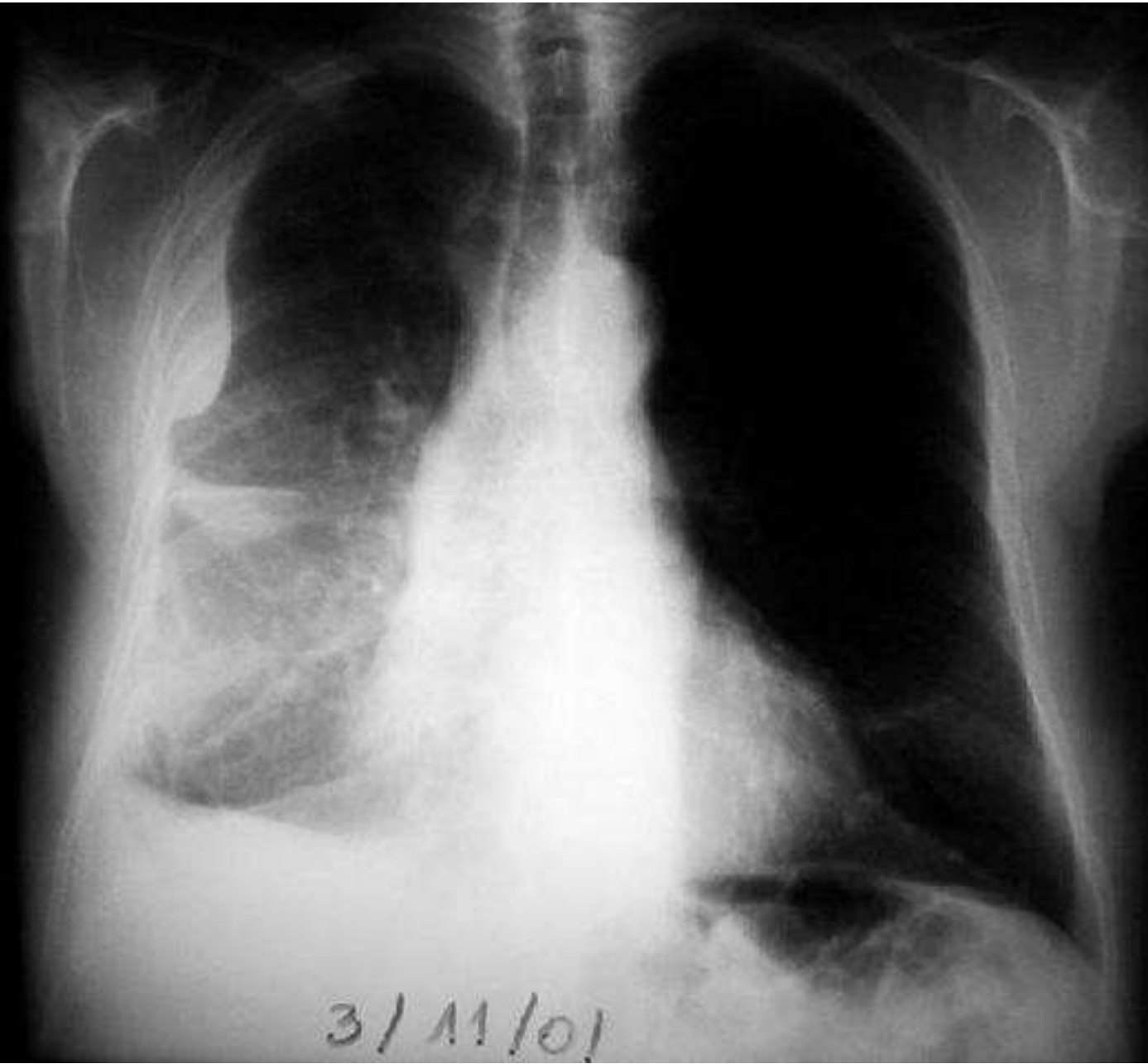Derrame subpulmonar izdo



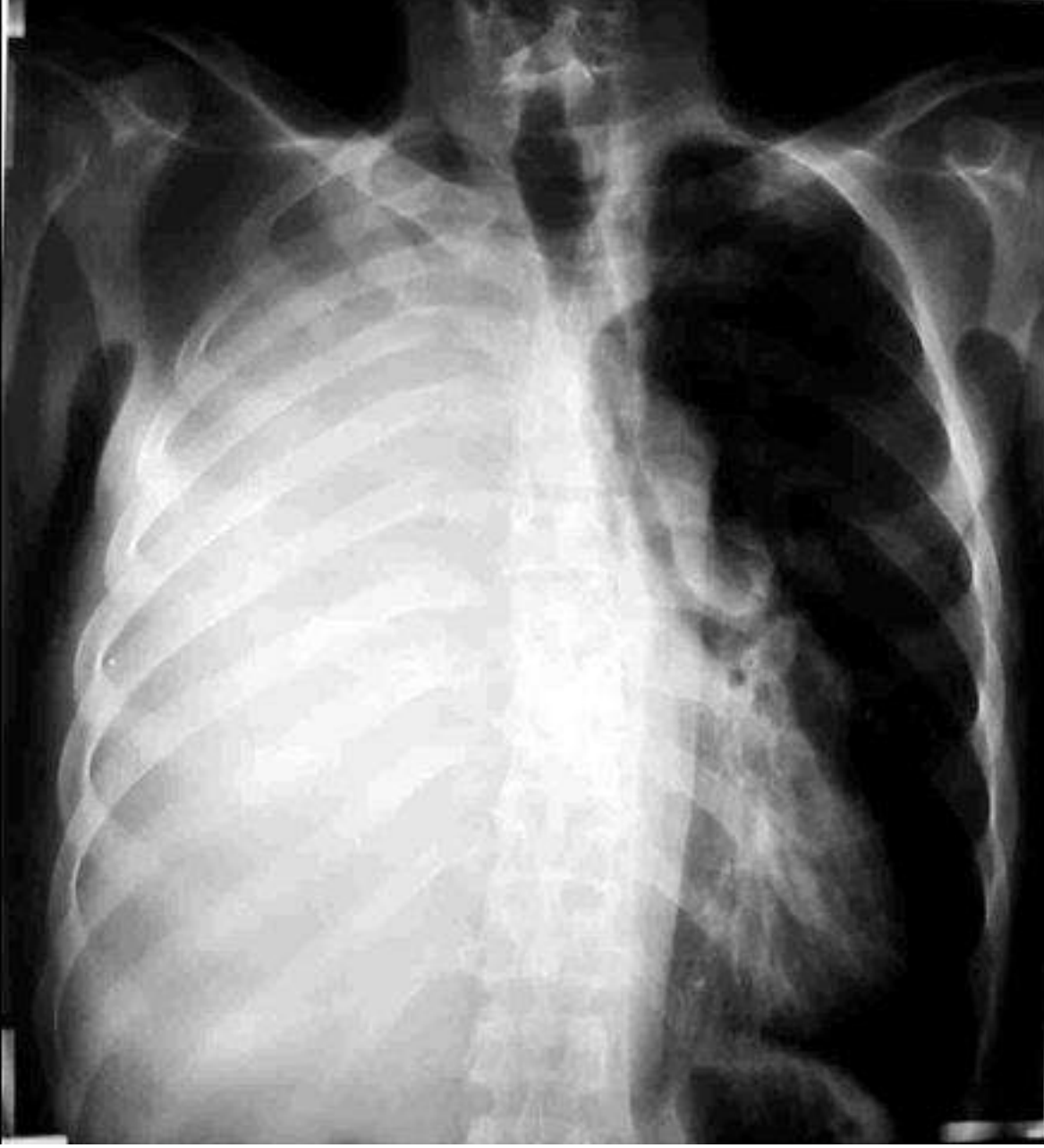Derrame lobulado

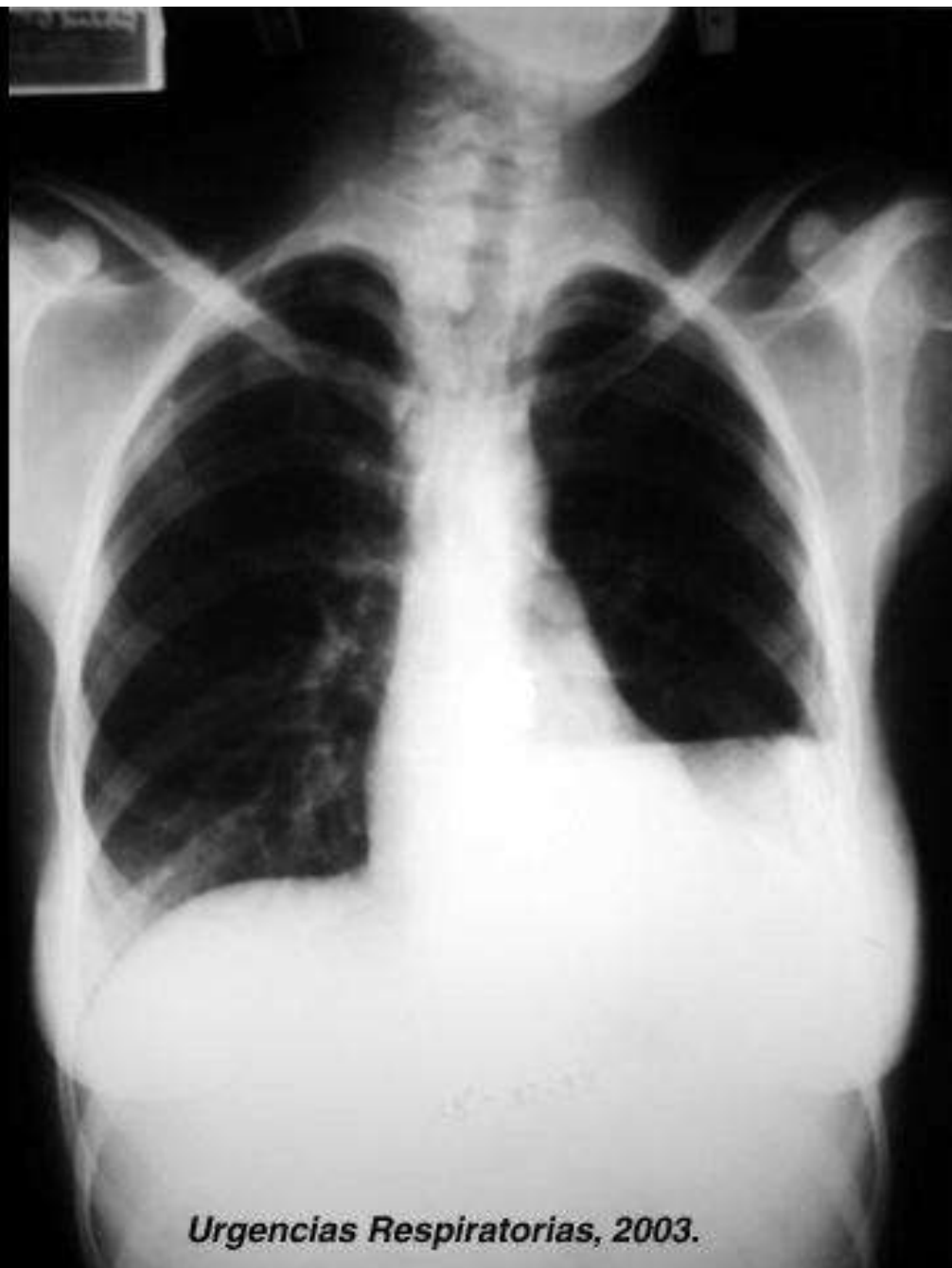Urgencias Respiratorias, 2003.

3/11/01

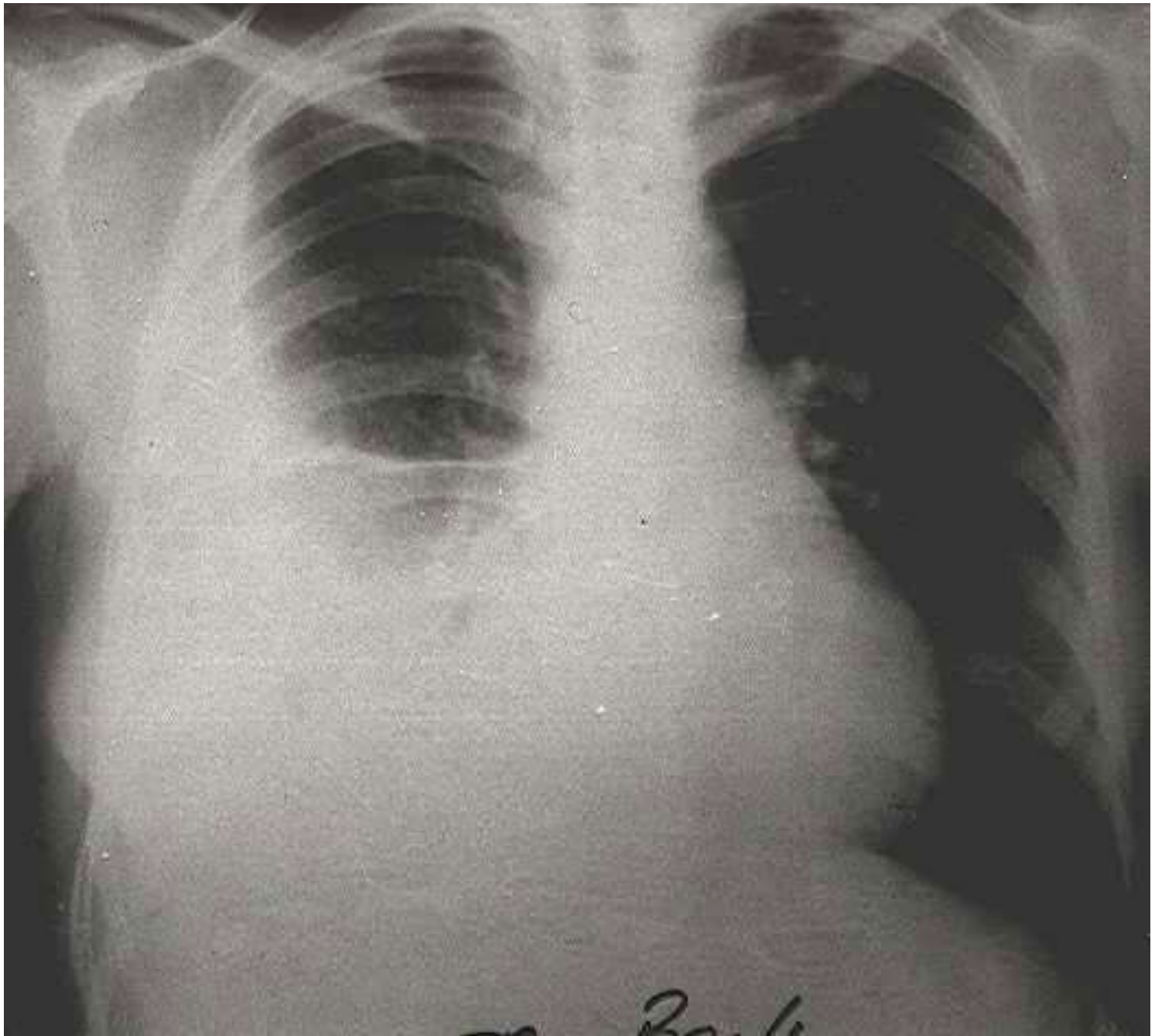


Urgencias Respiratorias, 2003.

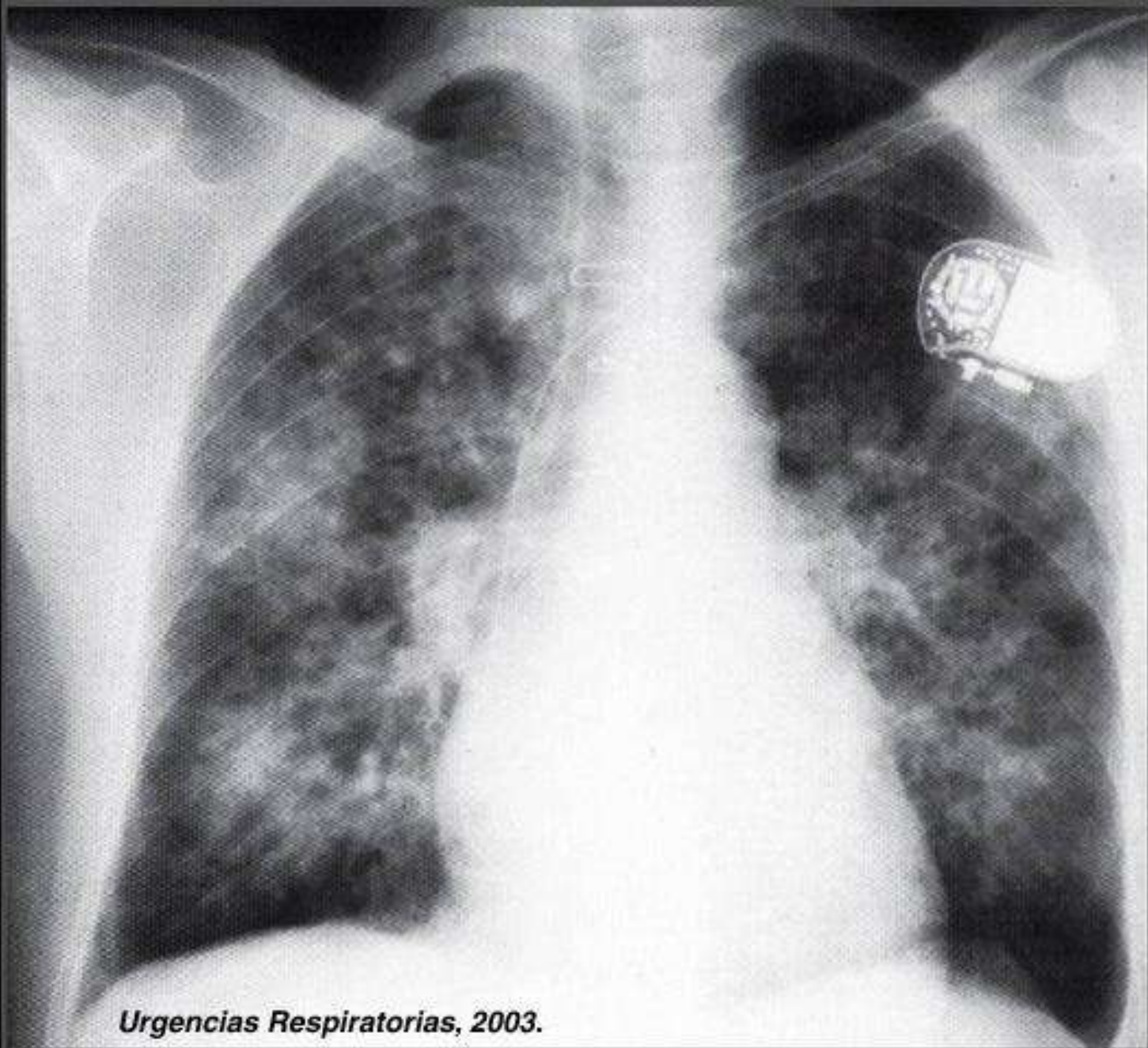




Urgencias Respiratorias, 2003.

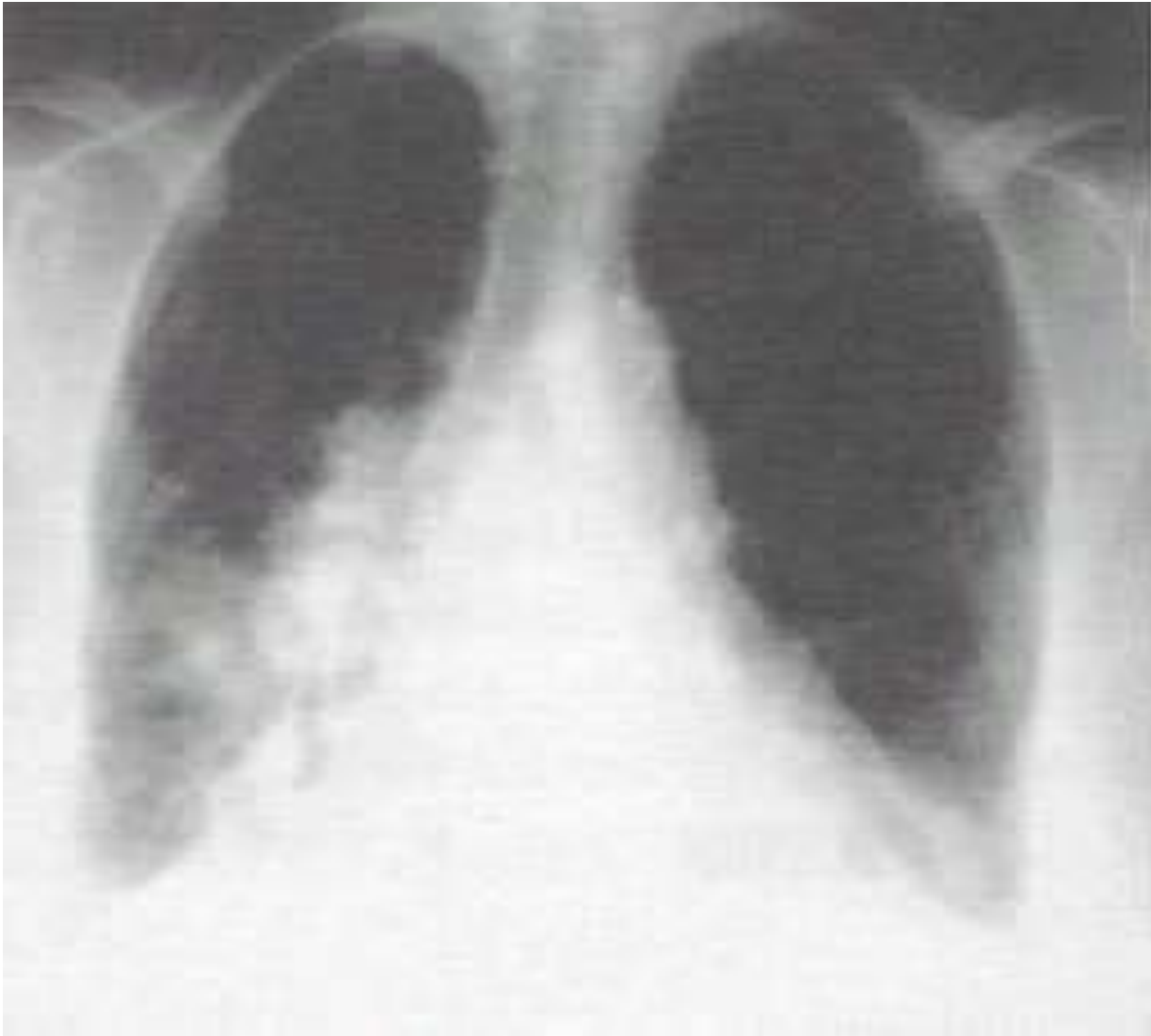

Derrame pleural

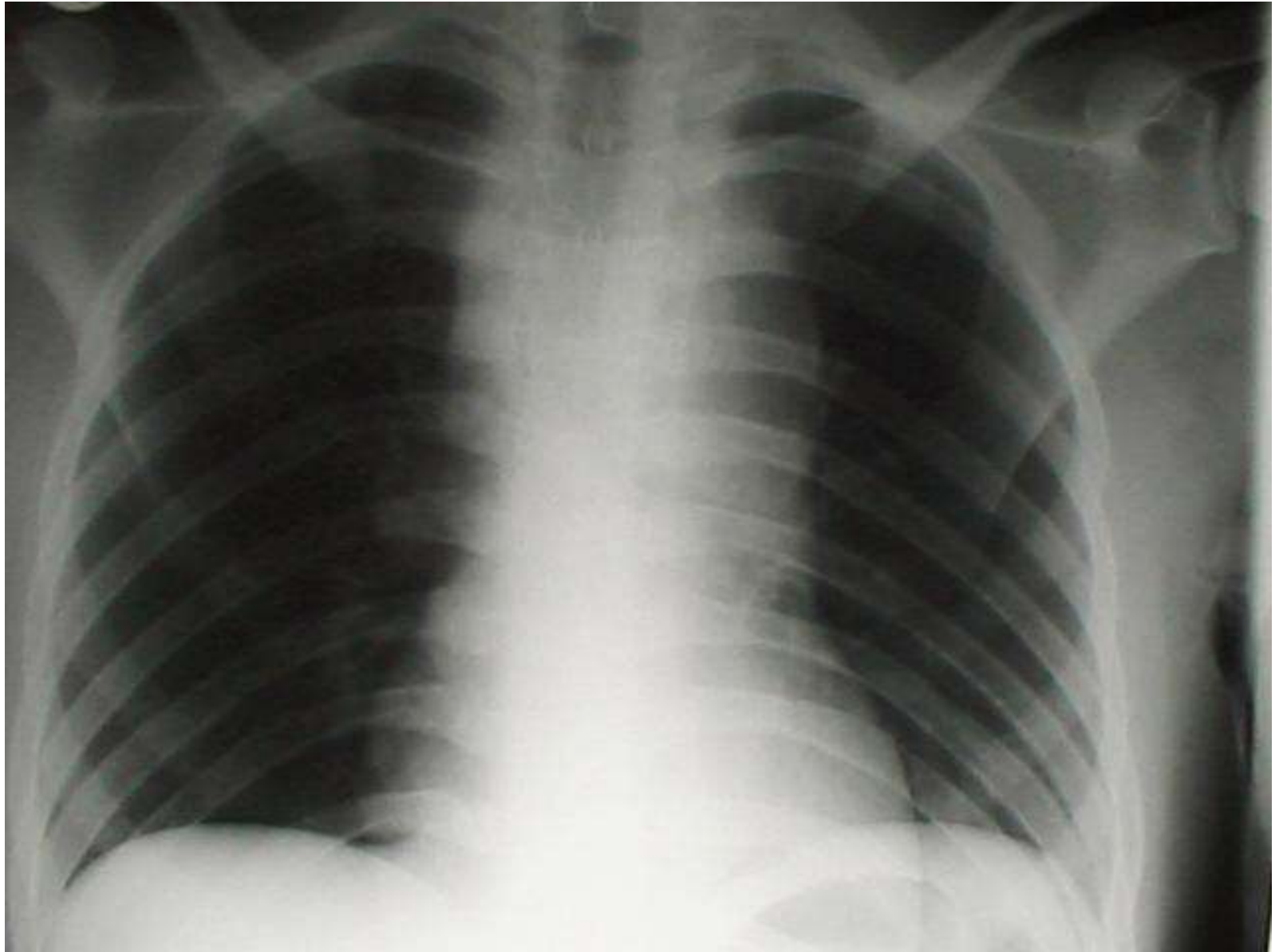


Urgencias Respiratorias, 2003.

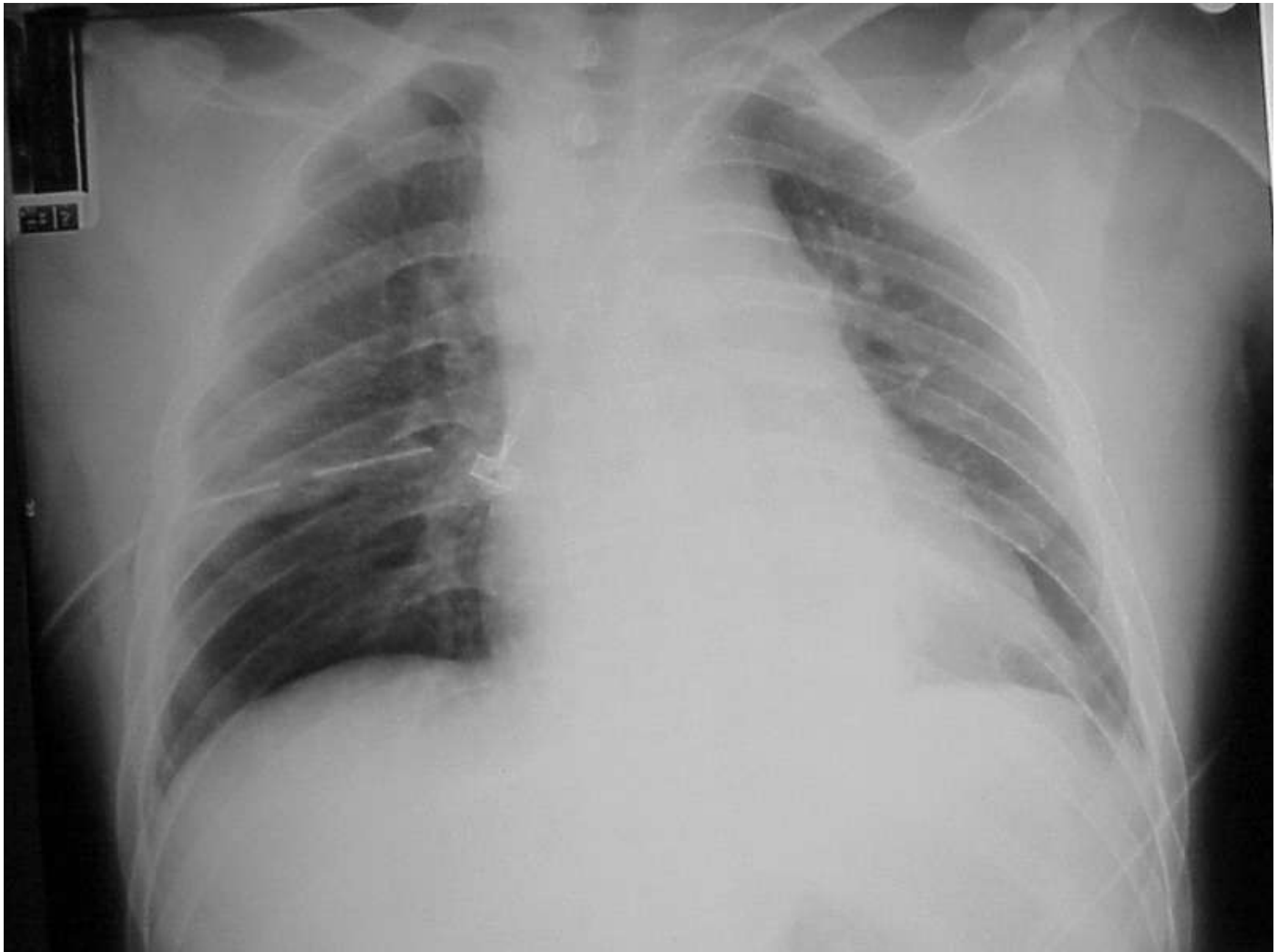EAP



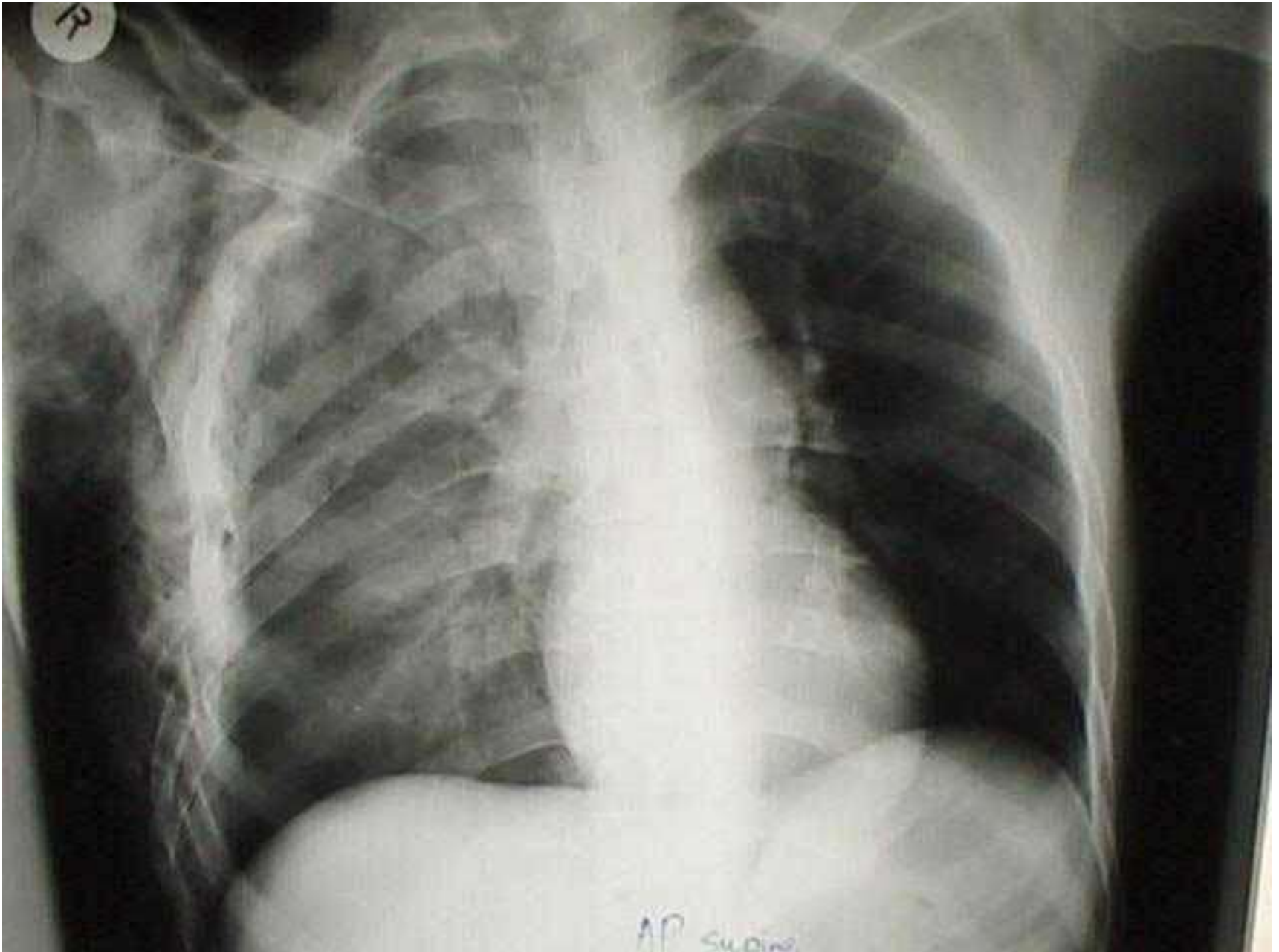
bronquiectasias



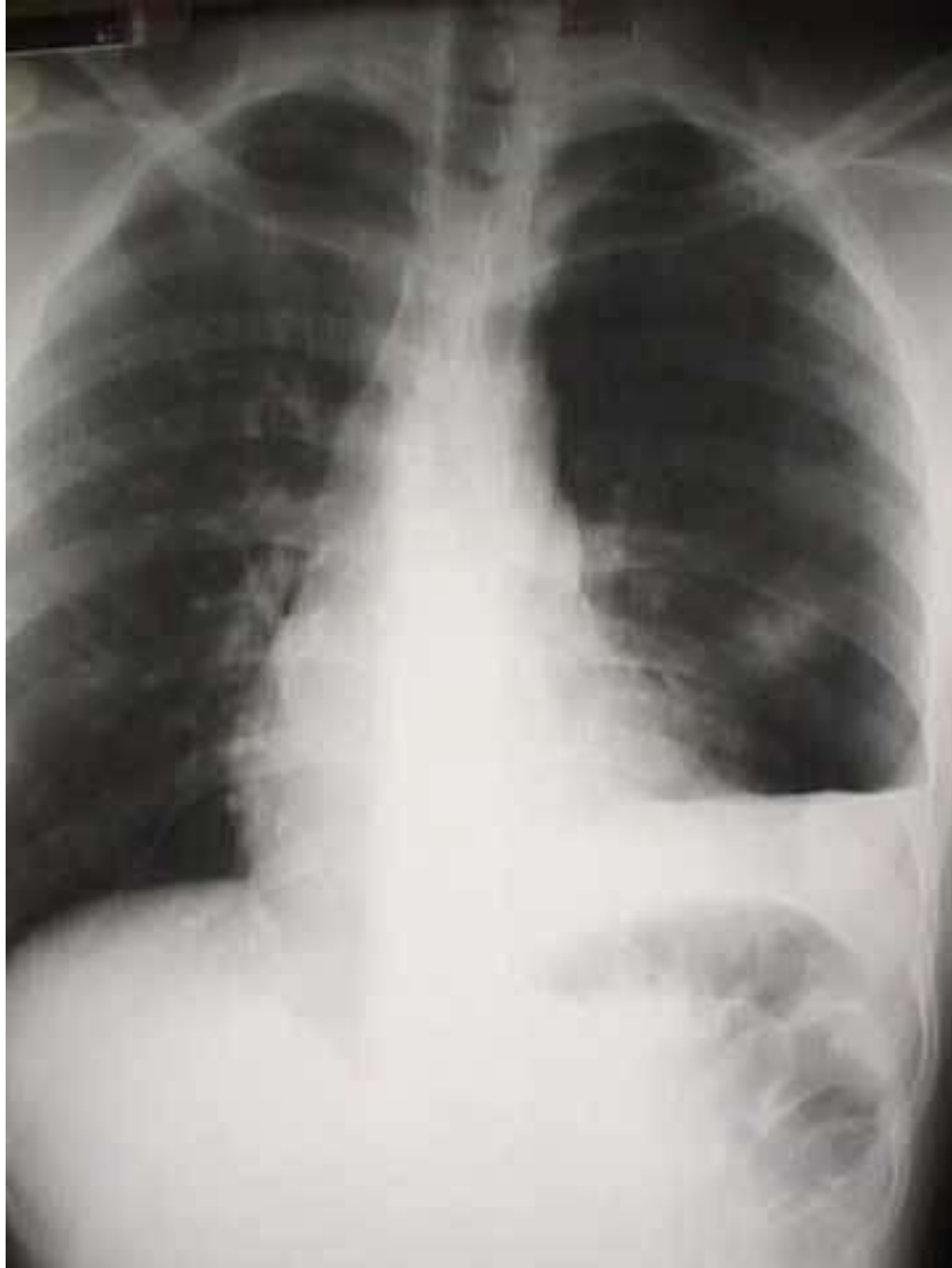
Ensanchamiento mediastínico



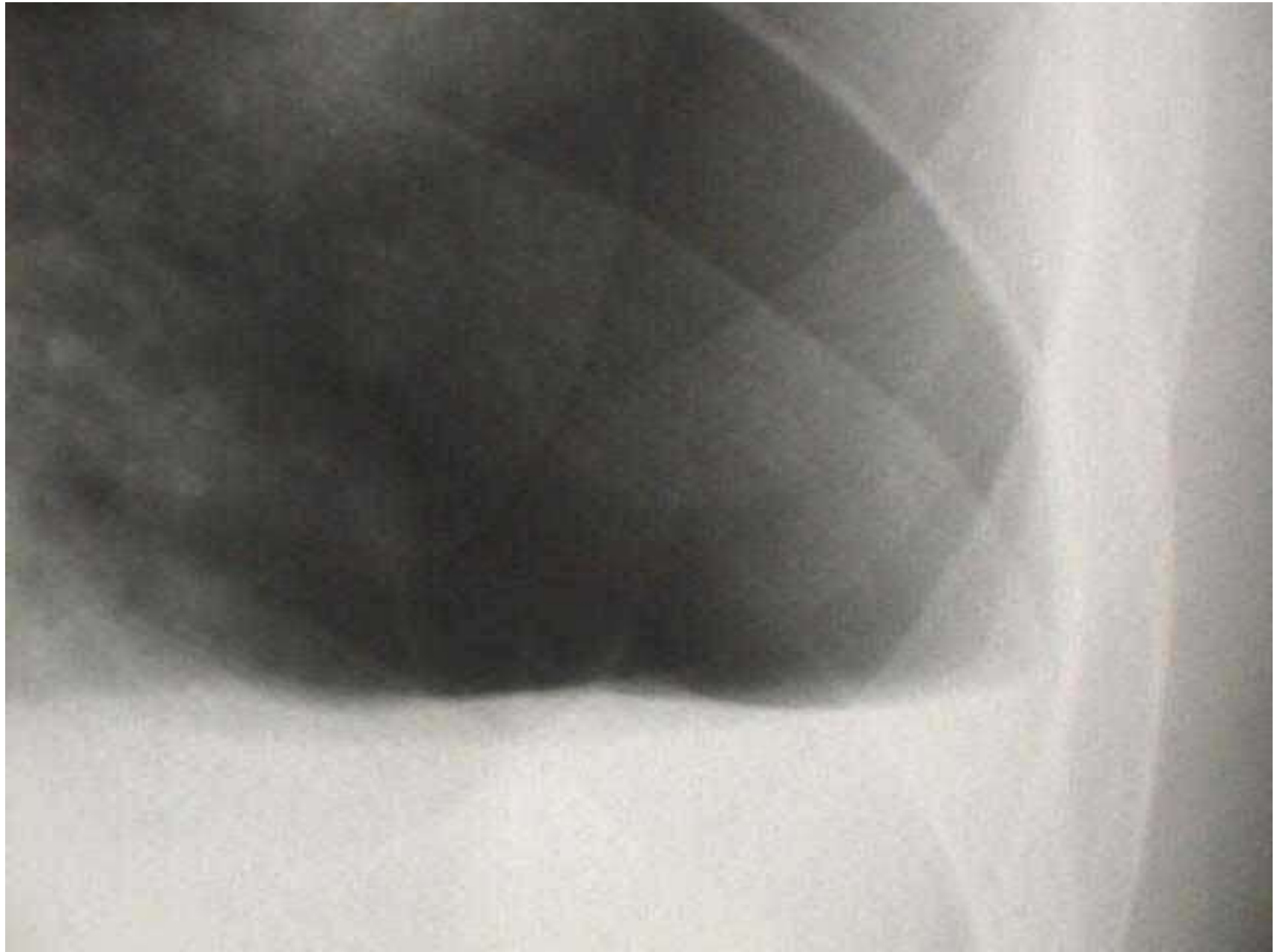
Ensanchamiento mediastínico

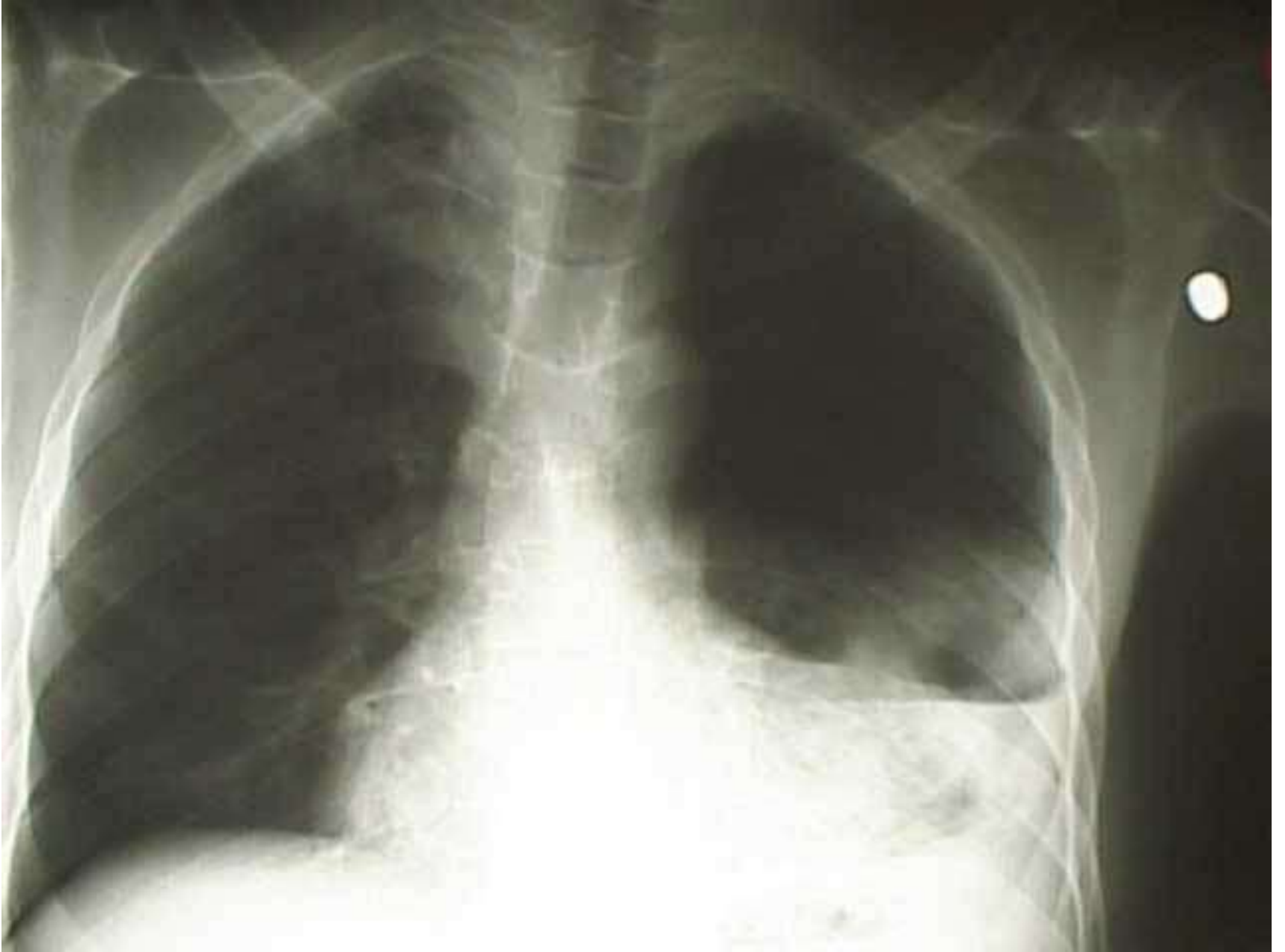

Fx costales múltiples y enfisema subcutáneo

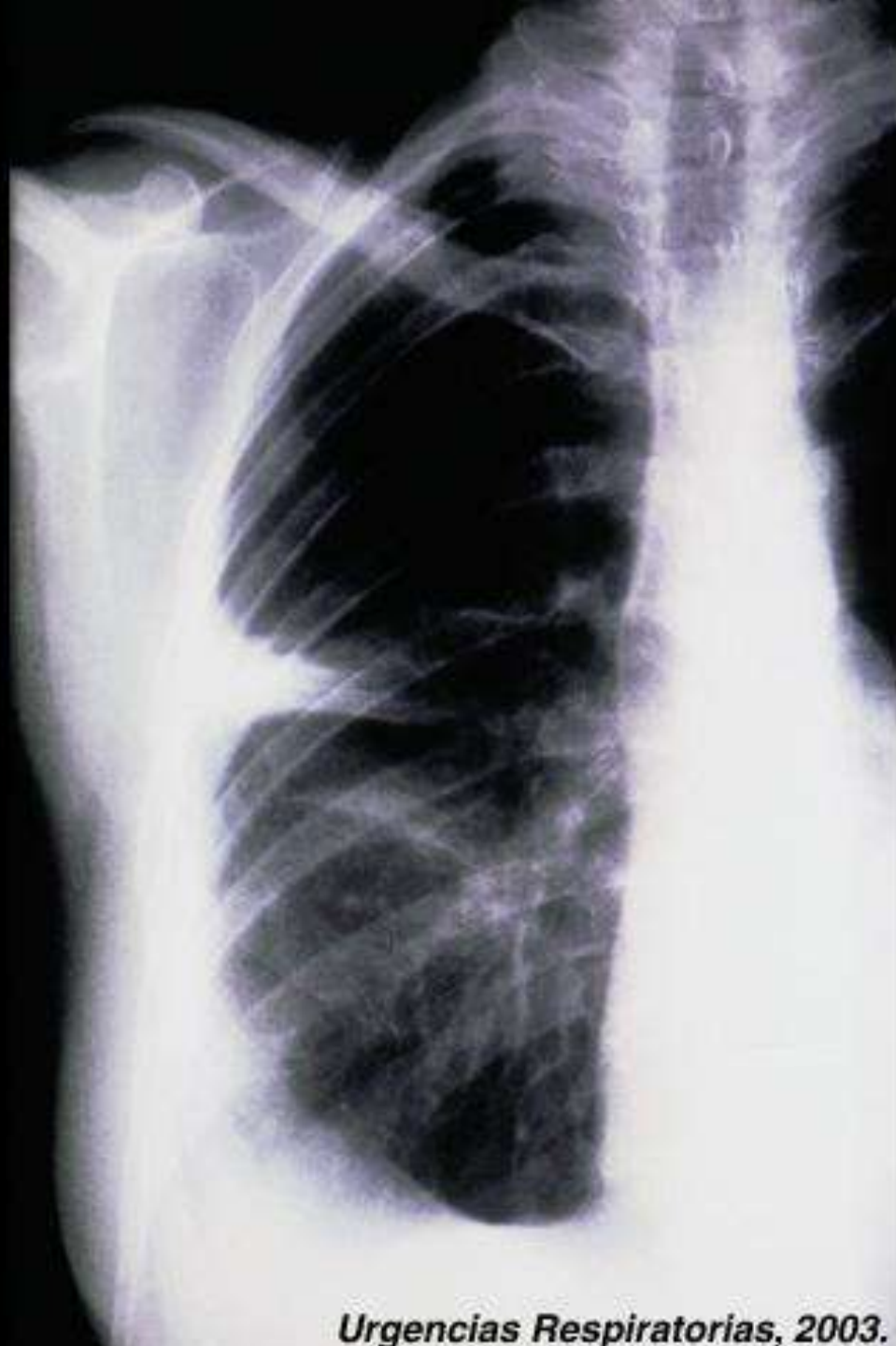


Hemoneumotórax

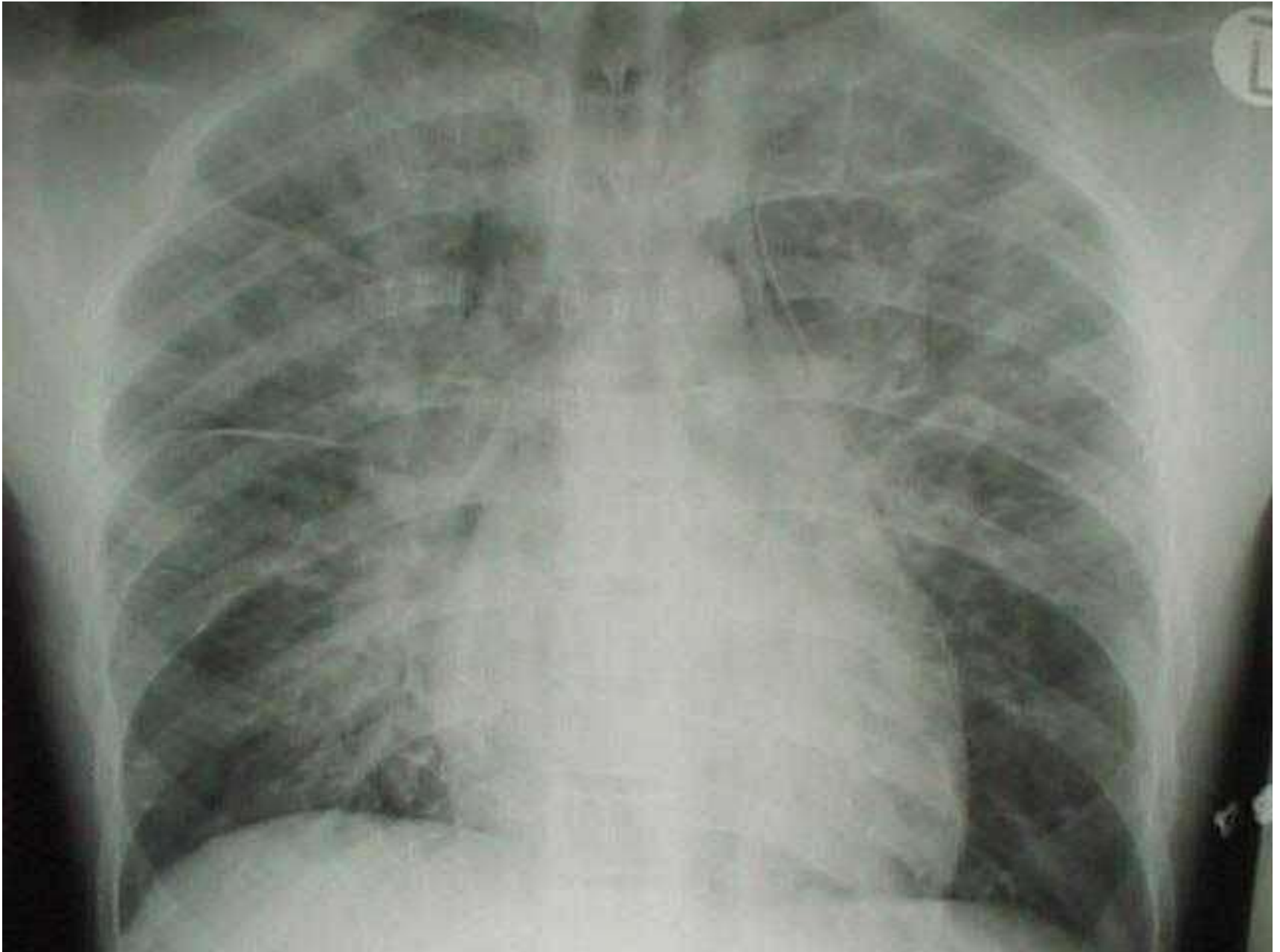




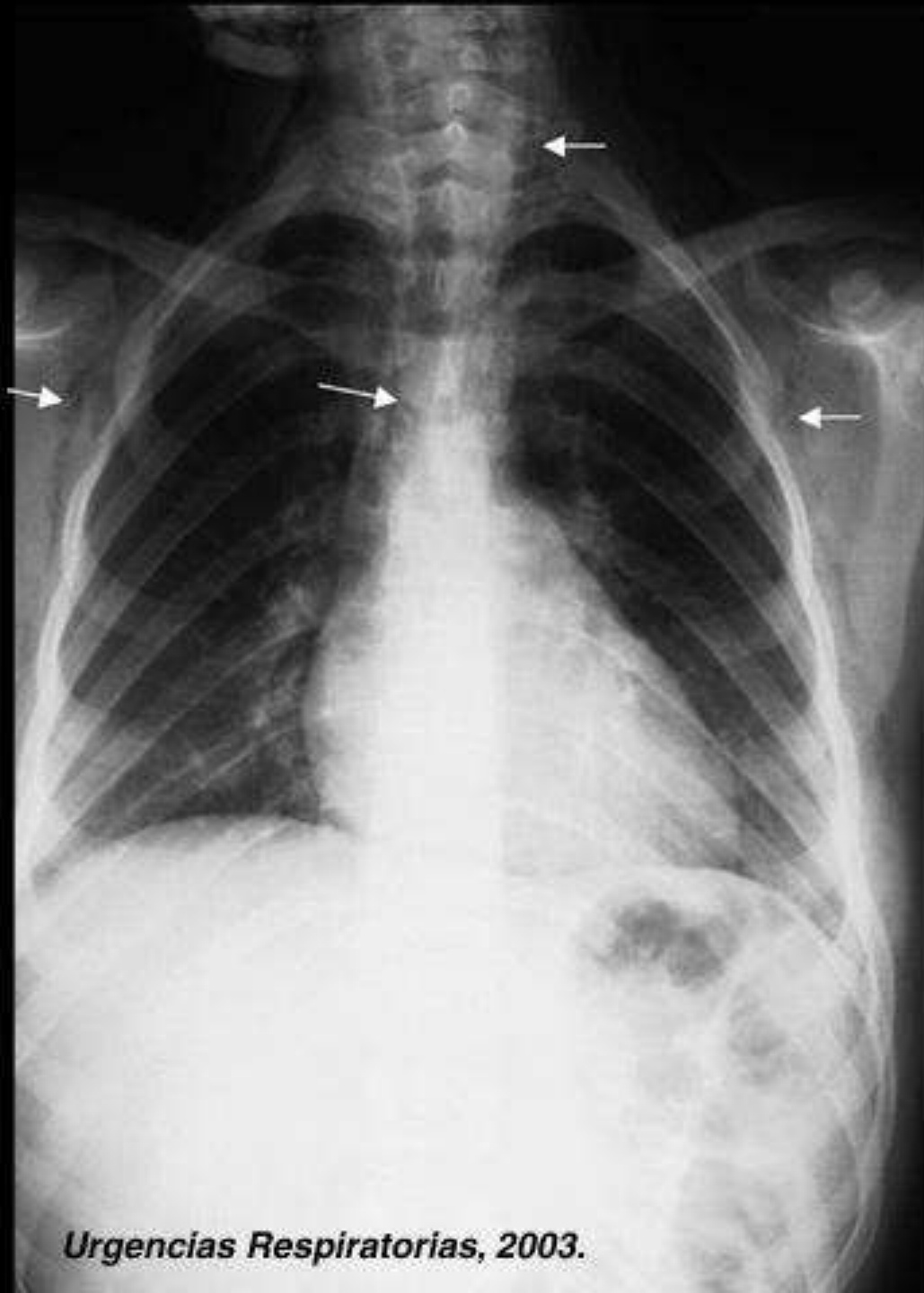hemotórax



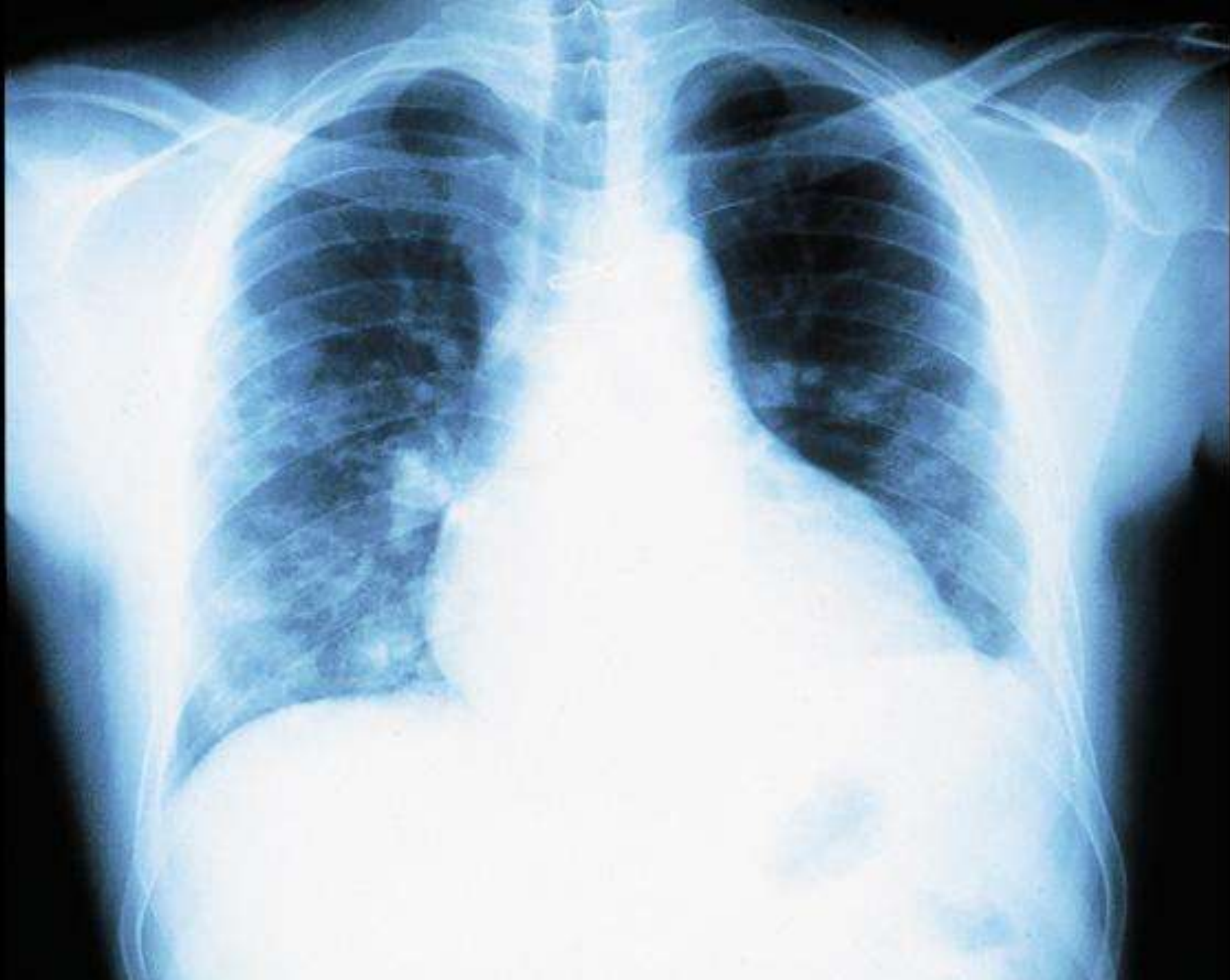
Urgencias Respiratorias, 2003.

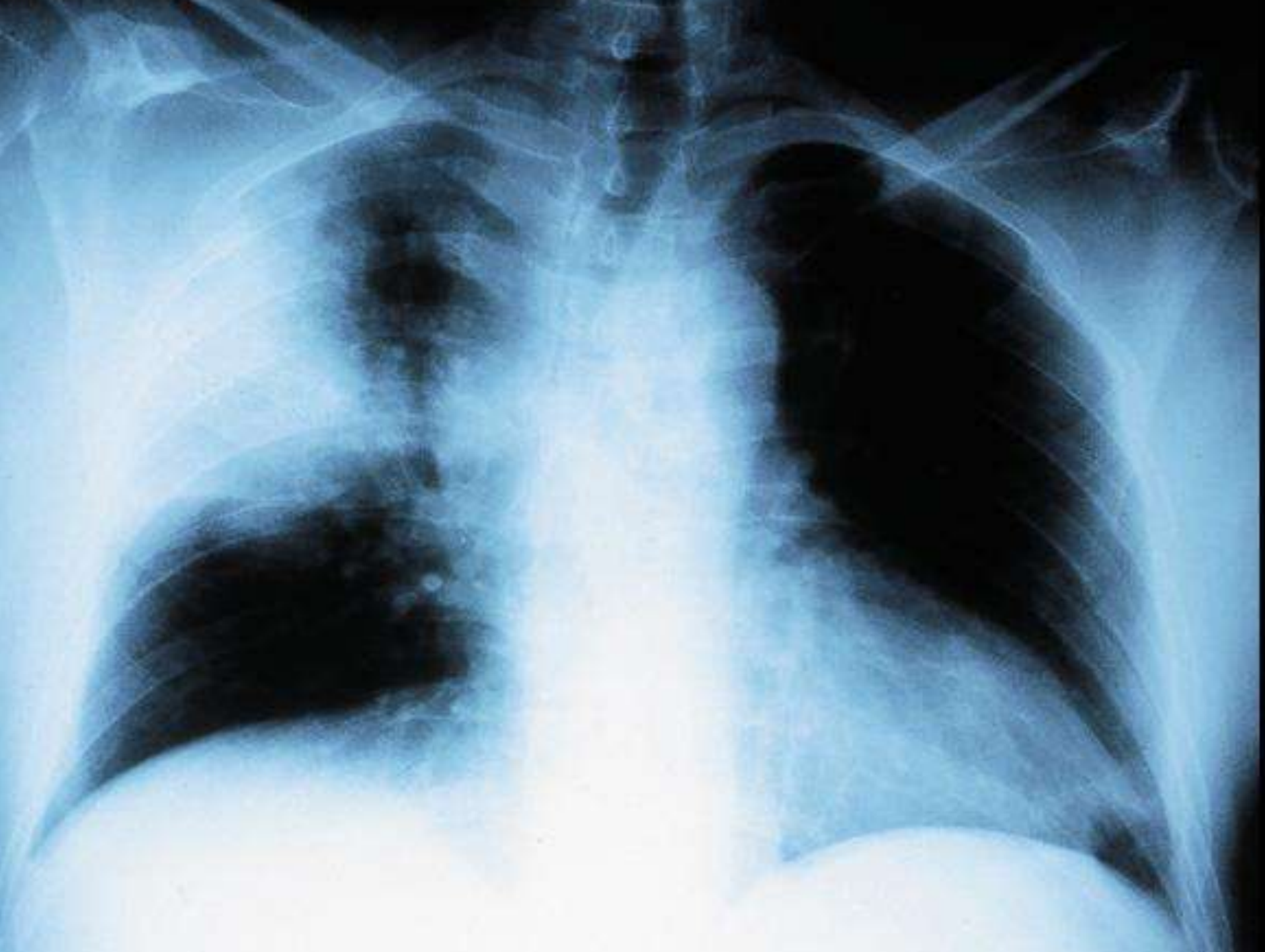


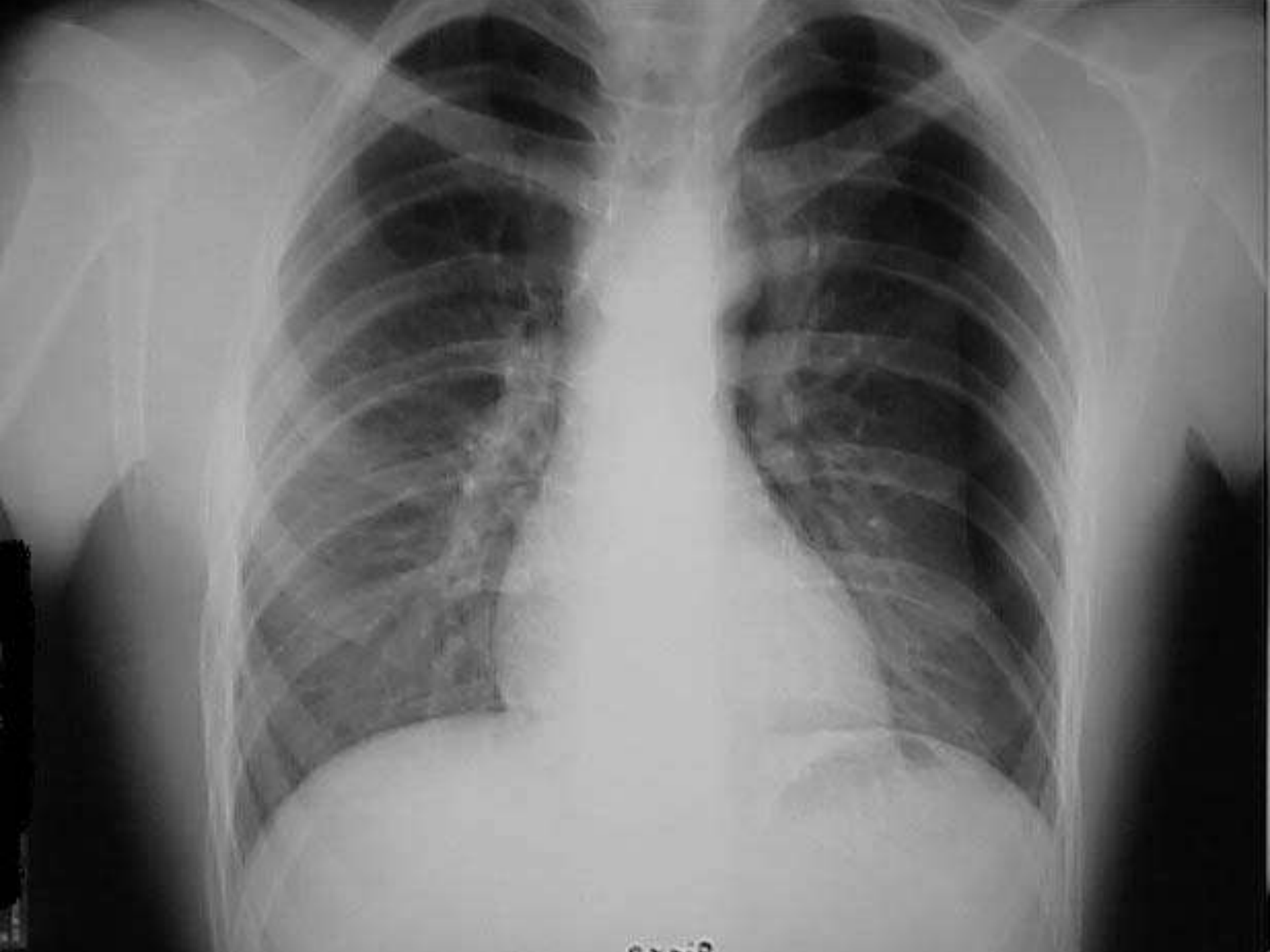Neumomediastino contusión pulmonar

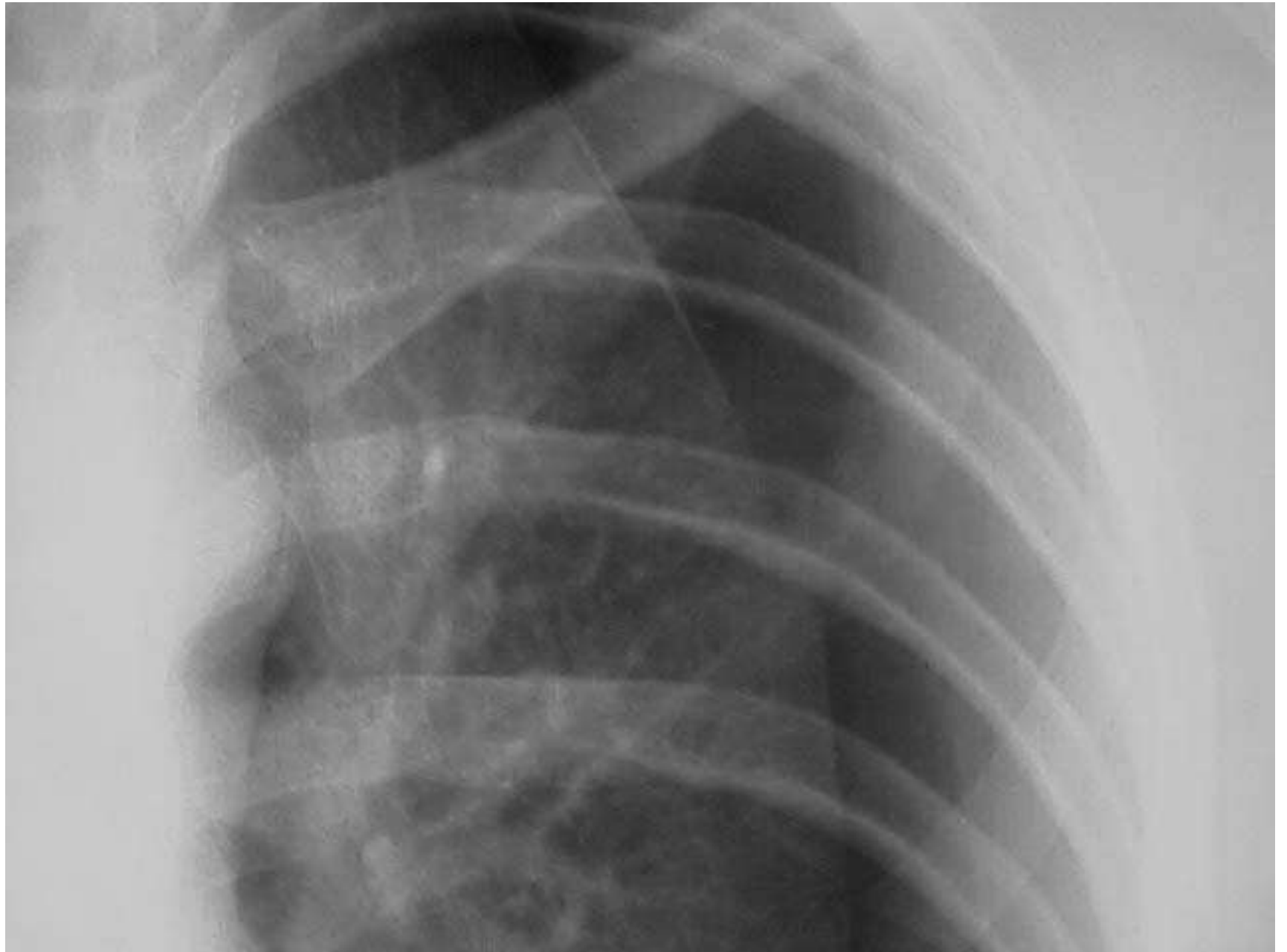


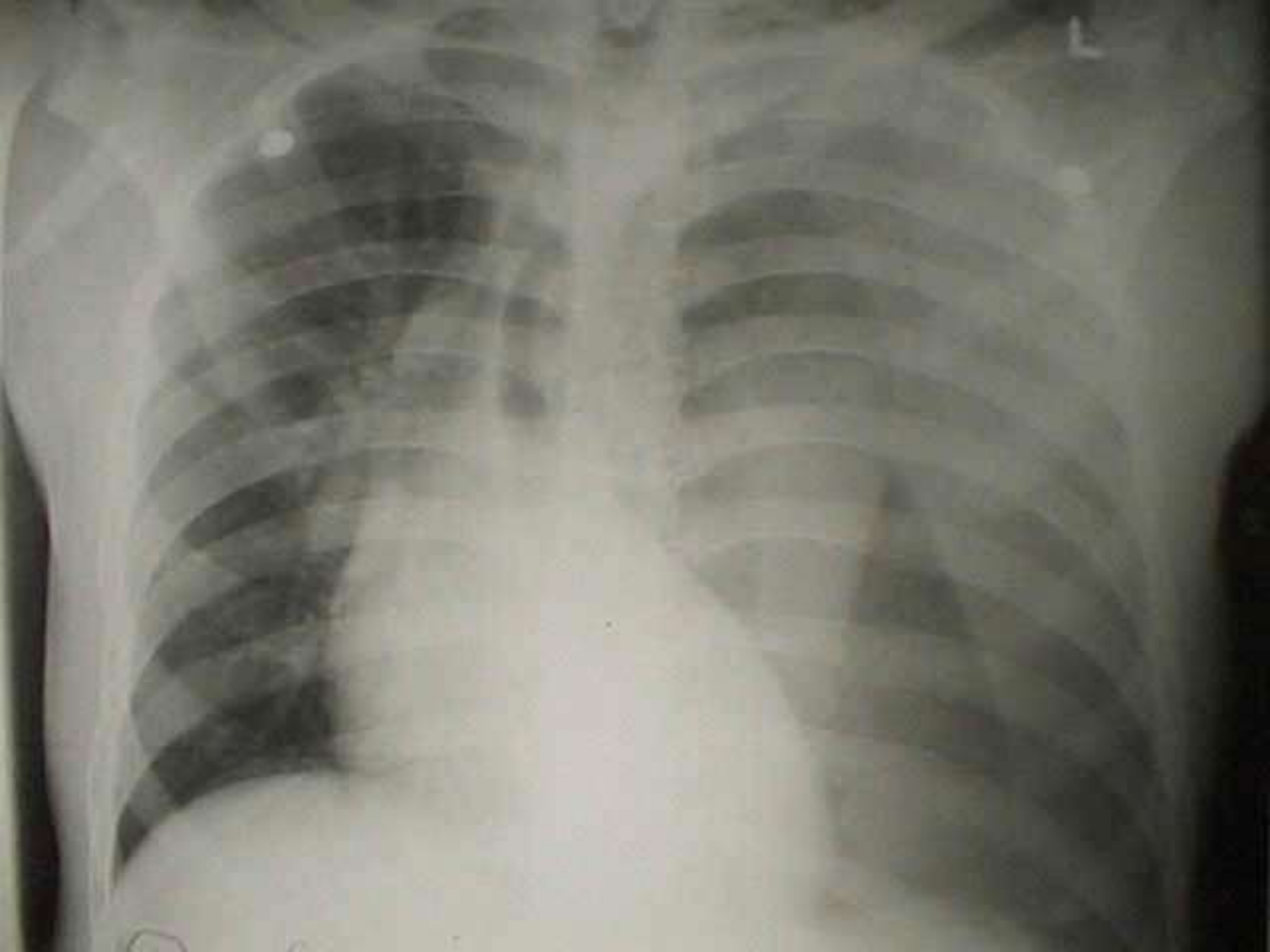Urgencias Respiratorias, 2003.

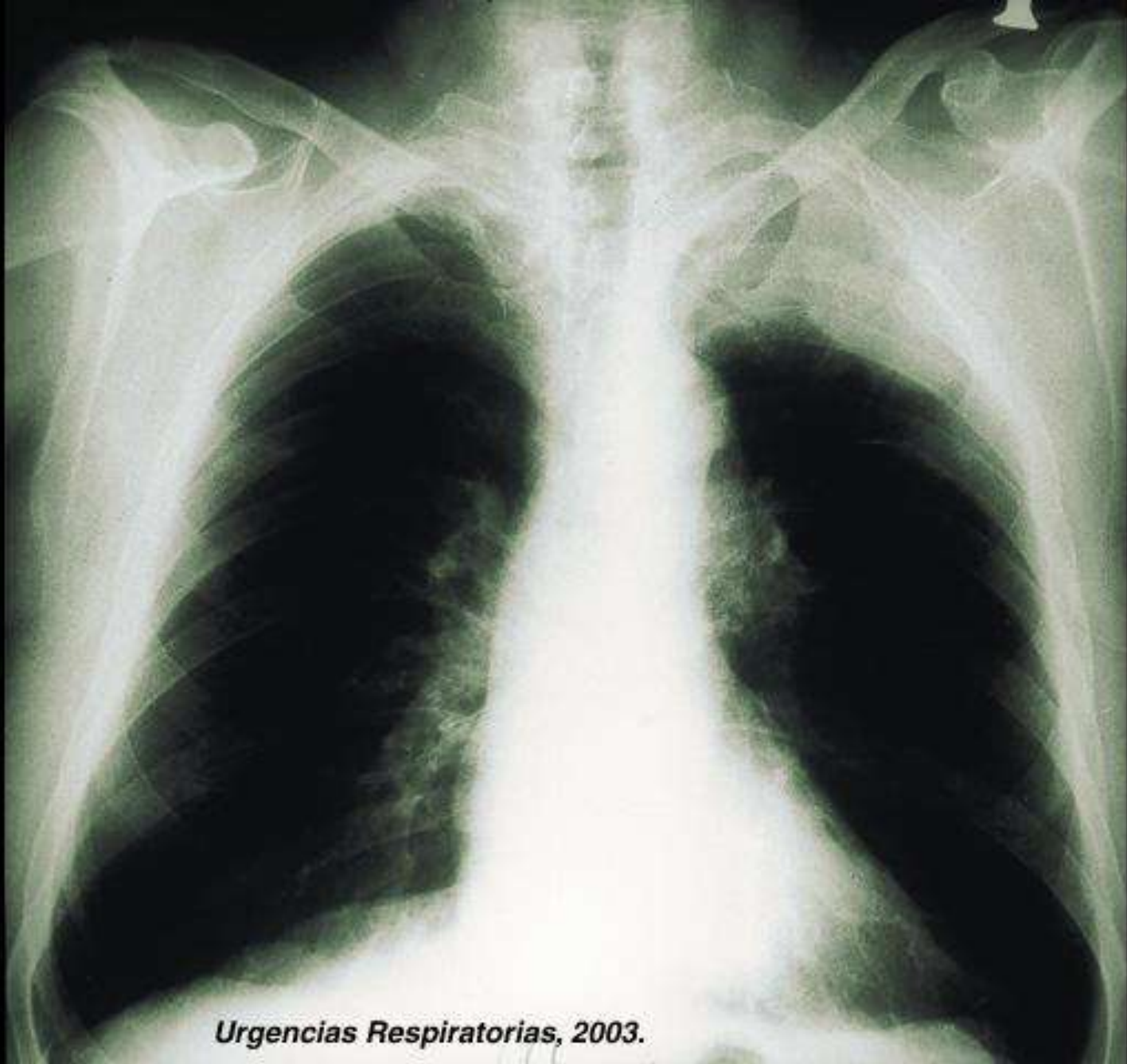






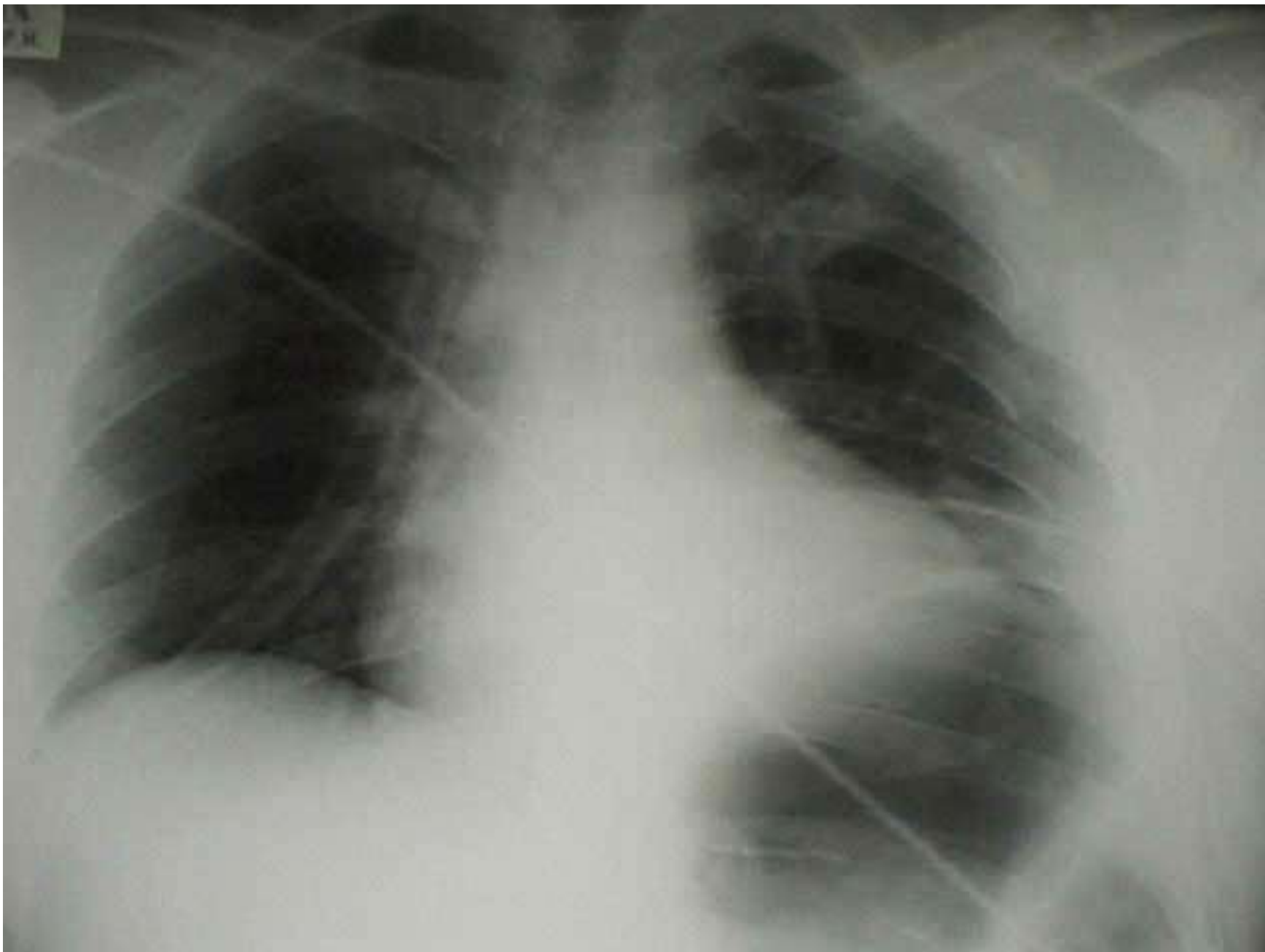






Urgencias Respiratorias, 2003.

T. Pancoast



Rotura diafragmática izda

